



PARTNERS IN CARE

VOLUME FOUR: NUMBER ONE

WINTER 2010

Online Imaging Consultations Now Available at Angell

For over a decade, Angell has provided consultative imaging services to our referring community.

Angell's Diagnostic Imaging service is pleased to announce an expansion of these services to include online consultations. In this digital age of imaging, obtaining the opinion of a radiologist via Internet transmission enables fast, precise diagnostic evaluations. Our experienced radiologists are currently partnering with fellow board-certified radiologists to provide timely interpretation of your digital images.

BENEFITS

- Timely consultation on difficult in-house cases
- If you choose to refer the case to Angell, our specialists can easily access your patient's radiographs

GETTING STARTED

Contact our Diagnostic Imaging service at 617 541-5139 or via e-mail at diagnosticimaging@angell.org to get started or for more information. We will arrange for DVMinsight support staff to call you to set up the system over the phone. Angell will pay the full set-up expense.

- DVMinsight support staff will guide you through the installation of the necessary software on your practice's computer, and assist you with procedures for transmission of images
- Angell will bill you monthly
- No required contract to sign

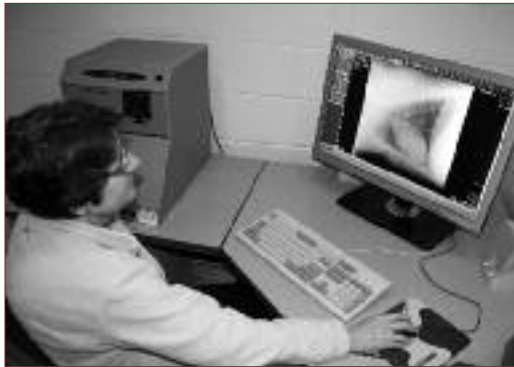
PROMPT TURNAROUND

- Average response time is 2–4 hours if the case is submitted between 8:00 a.m. and 4:00 p.m. Monday through Saturday
- Guaranteed 24-hour turnaround on cases submitted Monday through Saturday (Sundays and holidays excluded); Angell radiologists are available Monday 9:00 a.m.–5:00 p.m. and Saturday 9:00 a.m.–4:00 p.m.
- "Night owl" service is available after hours

Laser Surgery

Surgical lasers are a versatile instrument for a variety of small-animal soft tissue surgical procedures. Lasers have a few distinct advantages over conventional scalpel surgery. The primary advantage is decreased intraoperative hemorrhage when incising highly vascular tissues. I have found it particularly useful for surgical procedures involving the external nose and oral cavity in dogs and cats. Lasers can help minimize the risk of hemorrhage in small exotic pets that can ill afford any blood loss. Many surgeons find the surgical laser very effective for correction of elongated soft palate in the dog; it is my preferred method for soft palate resection, both for its ability to control

CONTINUED ON PAGE 2



Kathy Beck, DVM, DACVR interprets online images.

- STAT service is available — receive results within two hours for an additional fee
- Phone follow-up discussion readily available

ANGELL'S DIAGNOSTIC IMAGING SERVICE

Led by Kathy Beck, DVM, DACVR, who has been a veterinary radiologist for more than two decades, Angell's Diagnostic Imaging team is composed of three board-certified veterinary radiologists and a full support team including eight veterinary technicians.

Angell's Diagnostic Imaging services are provided in four radiology suites, two of which have fluoroscopic capability, one ultrasound room, a CT unit, and a new MRI unit. The MRI unit is designed specifically for animals, with the ability to accommodate even the largest of our small animal patients. It features a V-shaped table to facilitate correct positioning, and technologies for monitoring vital signs while a patient is under anesthesia.

To learn more about Angell's Diagnostic Imaging service or the expanded consultative service, please visit www.angell.org/diagnosticimaging. To contact Angell's Diagnostic Imaging service, please call 617 541-5139 or e-mail diagnosticimaging@angell.org.

INSIDE

Case Study: Mediastinal Mass	P2
Advanced Technology: Bronchoscopy	P3
Angell Referral Contact Information	P4

We encourage our referring veterinary partners to call or e-mail our Angell specialists to consult on difficult cases.

Angell specialists are available for consultation

Monday–Friday

9:00 a.m.–5:00 p.m.

Additionally, Angell

emergency doctors

are available for

consultation on weekends

and after hours

(7:00 a.m.–11:00 p.m.).

Please see the

back cover of this

newsletter for full

contact information.

Michael Pavletic, DVM, DACVS



Dr. Pavletic with Angell's laser unit.

CASESTUDY

Avian and Exotic Animal Medicine

Julie DeCubellis, MS, DVM

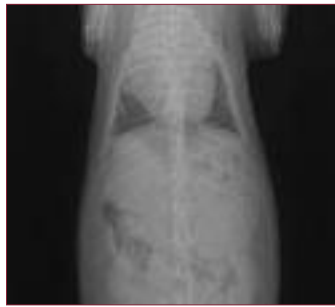
PATIENT:

Lucky, a female Dwarf Rabbit, almost 5 years of age.

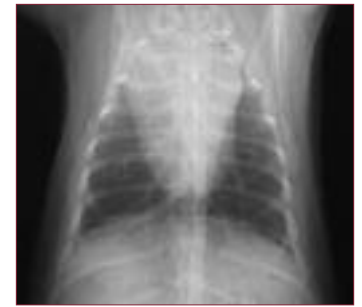
PRESENTING CONCERN: MEDIASTINAL MASS

Lucky, a previously healthy Dwarf Rabbit, presented to her primary care veterinarian with concern for exophthalmos (bulging eyes) with third eyelid protrusion and an increased respiratory rate. Radiographs demonstrated a large cranial mediastinal mass. She was referred to Angell Animal Medical Center for further treatment.

Cranial mediastinal masses in rabbits are most often due to thymoma or thymic lymphoma. Less common diagnoses include an intrathoracic fat pad, abscess, or thymic remnant. Consolidated lung tissue can also mimic a mass on radiographs. The incidence of these lesions in rabbits is unknown, as are any age, gender, or breed predilections. Space-occupying masses in the mediastinum frequently cause increased venous pressure, classically presenting as bilateral exophthalmos with third eyelid protrusion and tachypnea (cranial caval syndrome). Bilateral exophthalmos can also result from tooth root abscess or retrobulbar neoplasia; however, these are usually painful and the eyes cannot be retropulsed as they can be with increased venous pressure.



Radiation therapy image of Lucky prior to treatment.



Radiation therapy image of Lucky following three doses of radiation therapy.

the procedure, pericardial effusion was noted that was later attributed to the mass following an otherwise normal echocardiogram. Cytologic evaluation of the mass revealed a mixed lymphocytic proliferation. Differential diagnoses included lymphocyte-predominant thymoma, small cell (lymphocytic) lymphoma, and reactive lymphoid tissue. Due to the size of the mass, which initially appeared to occupy 1/3 to 1/2 of the chest cavity with obstruction of the cardiac silhouette, it was decided to attempt reduction via radiation therapy prior to considering surgical excision. Lucky received three doses of radiation therapy (8 Gy each) on days 0, 7, and 21. Following the first radiation treatment, the mass reduced 25% in size. After the final treatment, the mass had reduced another 25% and the cardiac silhouette was visible.



Lucky following radiation therapy.



Julie DeCubellis, MS, DVM and Jennifer Graham, DVM, DABVP-Avian, DACZM of Angell's Avian and Exotic service examine a chinchilla.

DIAGNOSIS/TREATMENT

Physical examination revealed tachypnea and exophthalmos that was able to be retropulsed. A complete blood count and chemistry profile demonstrated marked lymphocytosis. Lucky was anesthetized and an ultrasound-guided, fine-needle aspirate of the mass was performed. During

FOLLOW-UP

Lucky regained her former activity level and became more interactive with her family. The owners elected against surgical excision at this time and will be monitoring Lucky at home for recurrence of clinical signs. She will also be initially monitored monthly with physical and radiographic examinations.

FOR MORE INFORMATION

To refer a patient to Angell's Avian and Exotic service, please call us at 617 522-5011. For more information, please visit www.angell.org/avianandexotic.

Laser Surgery

CONTINUED FROM PAGE 1

hemorrhage and the time saved compared to conventional resection of this structure. I also have found the laser useful for partial resection of pinnal neoplasms, as well as for ear canal ablation for end-stage external ear canal disease. While many veterinarians have used the laser for a number of basic surgical procedures, such as castration and declawing, the advantages over the use of a cutting blade are largely based on the doctor's personal preference. A complete familiarity with the rules of proper laser usage can assure this surgical instrument can be used safely and effectively in the small-animal practice. There is a variety of laser models available for veterinary use. At Angell Animal Medical Center, we are satisfied with the carbon dioxide laser. However, veterinarians should review the literature and talk to other practitioners regarding which laser unit they find the most useful and cost-effective in their own small-animal practices.

We encourage you to e-mail Dr. Mike Pavletic if you have questions regarding laser surgery (mpavletic@angell.org). To learn more about Angell's surgical offerings, please visit www.angell.org/surgery. To refer a client to Angell's Surgery service, please contact Referral Coordinator Eleanor Cousino at 617 522-5011 or by fax at 617 989-1635.

CLINICAL STUDY

Rebecca Remillard, PhD, DVM, MS, DACVN



Rebecca Remillard, PhD, DVM, MS, DACVN.

Dear Colleagues:

Angell Animal Medical Center is conducting an Early Renal Disease Dietary Trial to determine the safety of feeding two different dietary protein levels to dogs.

Dietary restriction of phosphorus has been associated with preservation of renal structure and function, reduction of tubulointerstitial lesions, and reduction in hyperphosphatemia and hyperparathyroidism, and has been directly linked to increased mortality in dogs with chronic renal failure. Other studies have noted a reduction in morbidity and mortality when dietary protein was restricted, but these diets differed in phosphorous and most studies were conducted before urine protein losses could be measured. Thus the value of protein restriction (independent of phosphorous restriction in canine renal disease) is unclear.

We are recruiting clinically healthy dogs between the ages of 5 and 15 years with increased serum BUN and creatinine, and dilute urine (with and without protein losses), for a three-month food trial. Owners are provided with a kidney workup (US, blood, and urine values), a dry dog food, monitoring (recheck visits, BP, and lab values) and stabilization of a uremic crisis if needed. The owner must agree to regular recheck visits, feeding only the prescribed diet (some treats allowed), and maintaining a Food and Quality of Life Diary. Please have your interested clients call me at 617 541-5043 for more information.

Sincerely,

Rebecca Remillard, PhD, DVM, MS, DACVN
Angell Nutrition Service

Office Hours: Tuesday–Friday 9:00 a.m.–5:00 p.m.
Phone 617 541-5043 · Fax 617 989-1670

Advanced Technology: Bronchoscopy

Bronchoscopy is a very useful tool for evaluating respiratory disease in both dogs and cats. Angell's Internal Medicine service has recently purchased a new, state-of-the-art video bronchoscope for use in dogs. We also have a smaller scope for use in cats. Indications for bronchoscopy include chronic cough, parenchymal pulmonary disease, hemoptysis, foreign body extraction, evaluation of tracheobronchial collapse, and more thorough evaluation of diseases that are poorly responsive to therapy, such as relapsing pneumonia.

In addition to evaluating the major airways and localizing disease to specific lung lobes, the bronchoscope is useful for evaluation of the nasopharynx and the larynx, when evaluating upper airway stridor and assessing laryngeal function.

Bronchoalveolar lavage is routinely performed during the scope procedure, which allows collection of samples for cytology and culture. Samples are obtained from both the right and left lung lobes with diffuse disease, and specific lobes as indicated by gross pathology and radiographic findings. Brush cytology is also a very effective means of obtaining samples for microscopic analysis. Biopsies are rarely performed, given the risk of hemorrhage and iatrogenic pneumothorax.

We feel that this new scope will be a great diagnostic tool for evaluating chronic pulmonary disease, and will help provide accurate diagnoses and therefore more effective therapy for our patients with respiratory disease.

For more information, please visit www.angell.org/internalmedicine. Angell's Internal Medicine doctors are available for consultation via phone or e-mail Monday–Friday 9:00 a.m.–5:00 p.m. To refer a patient to the Angell Internal Medicine service, please call Referral Coordinator Eleanor Cousino at 617 522-5011.



Erika de Papp, DVM, DACVIM with Angell's state-of-the-art video bronchoscope. The bronchoscope is a great diagnostic tool for evaluating chronic pulmonary disease.

We encourage you to e-mail Angell's specialists with questions. We hope you will use Angell as a resource, and we look forward to working with you as we continue our legacy of providing compassion and care for animals.

**350 South Huntington Ave.
Boston, MA 02130
Main Phone: 617 522-7282
Veterinary Referrals:
617 522-5011**

Chief of Staff

Ann Marie Manning, DVM, DACVECC
amanning@angell.org

**Avian & Exotic Animal
Medicine**

Jennifer E. Graham, DVM,
DABVP—Avian, DACZM
jgraham@angell.org

Connie J. Orcutt, DVM, DABVP—Avian
corcutt@angell.org

Cardiology

Nancy J. Laste, DVM, DACVIM
nlaste@angell.org

Rebecca L. Malakoff, DVM, DACVIM
rmalakoff@angell.org

**Clinical & Anatomical
Pathology**

Patty Ewing, DVM, DACVP
pewing@angell.org

Pamela Mouser, DVM, MS, DACVP
pmouser@angell.org

Dentistry

William Rosenblad, DVM
wrosenblad@angell.org

Curtis A. Stiles, DVM, DAVIDC
cstiles@angell.org

Dermatology

Kathy Tater, DVM, DACVD
dermatology@angell.org

Diagnostic Imaging

Jessica Basseches, DVM, DACVR
jbasseches@angell.org

Kathy A. Beck, DVM, DACVR
kbeck@angell.org

Joan Regan, VMD, DACVR
jregan@angell.org

**Emergency & Critical
Care Medicine**

Kiko Bracker, DVM, DACVECC
kbracker@angell.org

Jennifer Holm, DVM, DACVECC
jholm@angell.org

Megan Whelan, DVM, DACVECC
mwhelan@angell.org

Internal Medicine

Doug Brum, DVM
dbrum@angell.org

Maureen Carroll, DVM, DACVIM
mccarroll@angell.org

Erika de Papp, DVM, DACVIM
edepapp@angell.org

Jean Marie Duddy, DVM
jduddy@angell.org

Shawn Kearns, DVM, DACVIM
skearns@angell.org

Chris Rollings, DVM, DACVIM
crollings@angell.org

Neurology

Andrew Farabaugh, DVM
afarabaugh@angell.org

Debbie Ruehlmann, DVM, MS, DACVIM
druehlmann@angell.org

Allen Sisson, DVM, MS, DACVIM
asisson@angell.org

Nutrition

Rebecca L. Remillard, PhD, DVM,
MS, DACVN
rremillard@angell.org

Oncology

Christine Anderson, DVM, MS,
DACVIM, DACVR
cranderson@angell.org

Carrie Wood, DVM, DACVIM
cawood@angell.org

Ophthalmology

Daniel J. Biros, DVM, DACVO
dbiros@angell.org

Martin Coster, DVM, MS, DACVO
mcoster@angell.org

Pain Medicine

Lisa Moses, VMD, DACVIM, CVMA
lmoses@angell.org

Surgery

Sue Casale, DVM, DACVS
scasale@angell.org

David W. Knapp, DVM, DACVS
dknapp@angell.org

Michael M. Pavletic, DVM, DACVS
mpavletic@angell.org

Catherine J. Reese, DVM, DACVS
creese@angell.org

Nicholas J. Trout, MA, VET MB, MRCVS,
DACVS, DECVS
ntrout@angell.org

Referral Contact Information

Cardiology Service

Referral Liaison: Sandra Russo
Referral Line: 617 541-5038 Referral Fax: 617 989-1653
E-mail: cardiology@angell.org Website: www.angell.org/cardiology

Dermatology Service

Referral Liaison: Rebecca Stlaske
Referral Line: 617 524-5733 Referral Fax: 617 989-1613
E-mail: dermatology@angell.org Website: www.angell.org/dermatology

Emergency Service

Referral Line: 617 522-7282 press 1 Referral Fax: 617 989-1633
Website: www.angell.org/emergency

Neurology Service

Referral Liaison: Lisa Canale
Referral Line: 617 541-5140 Referral Fax: 617 989-1666
E-mail: neurology@angell.org Website: www.angell.org/neurology

Oncology Service

Referral Liaison: Gary Vanasse
Referral Line: 617 541-5136 Referral Fax: 617 541-5130
E-mail: oncology@angell.org Website: www.angell.org/oncology

Ophthalmology Service

Referral Liaison: Sandra Russo
Referral Line: 617 541-5038 Referral Fax: 617 989-1653
E-mail: ophthalmology@angell.org Website: www.angell.org/eyes

Pain Medicine Service

Referral Liaison: Lisa Canale
Referral Line: 617 541-5140 Referral Fax: 617 989-1666
E-mail: painmedicine@angell.org Website: www.angell.org/painmedicine

**For all other referrals, please contact Eleanor Cousino,
Angell Referral Coordinator, at 617 522-5011,
or by fax at 617 989-1635.**



350 South Huntington Avenue
Boston, Massachusetts 02130

www.angell.org

Nonprofit Org
US Postage
PAID
Permit No. 56959
Boston MA

Are your clients new to Angell? Send them to www.angell.org/directions for detailed directions to our location. Ample free parking on site.