

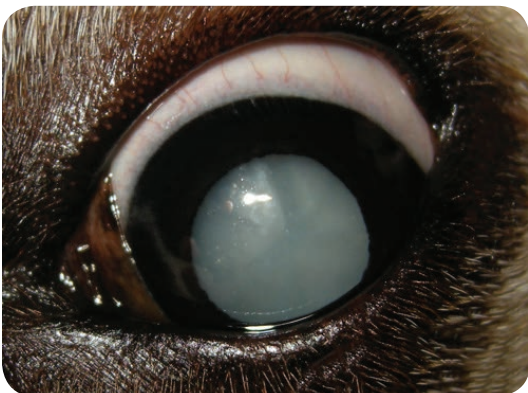Lifting the Veil: Canine Cataracts & Cataract Surgery



By Martin Coster,
DVM, MS, DACVO

angell.org/eyes
ophthalmology@angell.org
617-541-5095

The word “cataract” derives from the Greek word for waterfall, and so is apt as the term for an opaque, whitened lens which impairs the passage of light (a more complete discussion can be read at www.mrcophth.com/Historyofophthalmology/cataracthistory.html). The lens is essentially a bag of protein, with lens fibers residing inside a defined capsule (a modified basement membrane). Like cooking an egg white, changes in the structure and orientation of the usually-parallel lens fibers will cause light to reflect from the surface, instead of transmitting through to the retina. Cataracts are typically staged from incipient (<10%) to immature (10-90+) to mature (complete, Figure 1) and hypermature (complete yet resorbing lens, with lens capsule wrinkling and crystalline refractive



▾ Figure 1: Cataract in the left eye of a diabetic dog.
© Martin Coster.

opacities present). Visual impairment can result from almost any stage of cataract (e.g. a small cataract in the axial, posterior lens capsule will be directly in the path of the most important central light rays), although obviously more complete cataracts elicit greater visual impairment.

In the dog, the most common cause of cataract is genetic predisposition, with over 90 breeds identified as predisposed. Other common causes of canine cataracts are diabetes mellitus, age (“senile” cataract), trauma, uveitis, glaucoma, progressive retinal atrophy, and lens luxation; in other words, any condition that affects the balance of aqueous humor flow to the lens can result in metabolic derangement of the lens protein fibers and thus cataract formation.

In diabetics, 50% of dogs will develop cataracts within 6 months of diagnosis, 75% within a year, and 80% within 16 months.¹ It is, therefore, extremely important in this disease to educate clients, monitor the lens for cataract formation, and refer patients at an appropriate time. Generally, most veterinary ophthalmologists would prefer to be involved as early in the process as possible (upon diagnosis, or even before cataract diagnosis in the case of predisposing conditions such as diabetes). Since diabetic cataracts will often develop in the very periphery of the lens, they can be difficult to detect without iatrogenic dilation and careful slitlamp biomicroscopic evaluation.

When cataracts are developing, topical anti-inflammatory drops (such as non-steroidal diclofenac and flurbiprofen, or in more severe cases the steroids prednisolone acetate and dexamethasone) are recommended to reduce lens-induced uveitis, which can be the root cause of many other sequelae such as glaucoma and retinal detachment. Even if cataract surgery is not elected, lifelong topical anti-inflammatories should be continued. A recent retrospective review showed that “failure” (blindness, although euthanasia and deaths were also counted) of an eye was more likely in untreated eyes (8 of 8) than medically treated eyes (20 of 35, 57%). However, surgically treated eyes had the lowest failure rate (7 of 34, 21%).²

> Continued on Page 2

Inside

| | |
|--|----|
| Wynnie: A Case Study of Nasopharyngeal Stenosis | 4 |
| Practical Tips for Reducing NSAID Toxicity | 6 |
| Radiographic Approach to the Coughing Pet | 8 |
| Melatonin for Primary Immune-Mediated Thrombocytopenia | 10 |

Courtesy Consultations

Angell specialists are available for consultation Monday – Friday, 9:00 a.m. – 5:00 p.m.

Additionally, Angell emergency doctors are available for consultation on weekends and after hours (7:00 a.m. – 11:00 p.m.).

Referral Contact Information

Please see Page 11 and the back cover of this newsletter for full contact information.

Online Referral Forms

Please visit angell.org/referrals

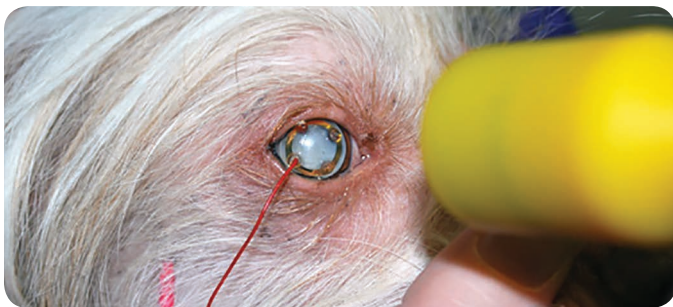
Upcoming CE Schedule

Please see Page 7

Available at angell.org/CE

> **Lifting the Veil: Canine Cataracts & Cataract Surgery** (Continued from Page 1)

Surgical extraction of cataracts remains the gold standard approach, and is usually recommended when cataracts are immature, as the lens will be softer and easier to extract. Some will choose to wait, with careful monitoring, until the immature cataract is causing noticeable visual impairment, although adaptation to the home environment can mask the severity of impairment. Recent research, presented at the American College of Veterinary Ophthalmologists conference in 2012, into non-surgical options for diabetic cataracts suggests that the vision supplement Ocu-GLO may slow development.³ This is, however, only a preliminary and non-peer-reviewed finding. Meanwhile, a topical aldose reductase inhibitor has shown promise in reducing cataract formation in diabetics, by halting the enzyme pathway that leads to the osmotic gradient responsible for lens imbibition.⁴ When and if this drug, Kinostat™, receives FDA approval, the management of diabetic cataracts may be revolutionized. However, the cost and lifelong thrice daily frequency required for this drug may limit its clinical application, leaving cataract surgery as the more efficient approach to case management.



∇ **Figure 2:** Electroretinography being performed for a diabetic cataract; there is a contact lens electrode on the cornea, one visible subcutaneous electrode, and the light source (yellow probe).

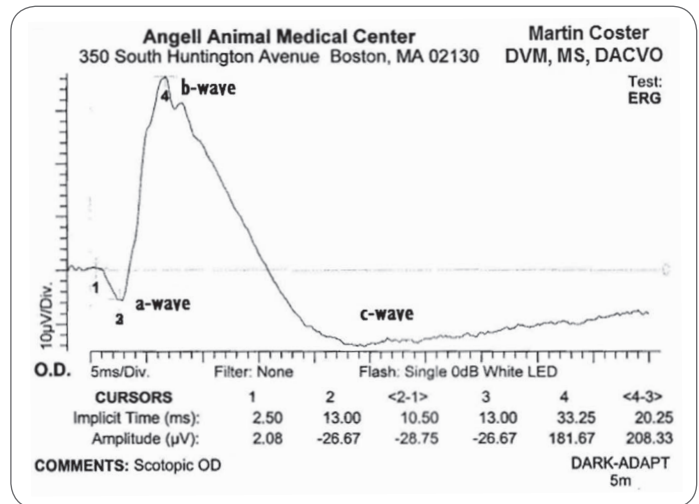
Prior to cataract extraction, a thorough assessment of the retina is made by the ophthalmologist. An electroretinogram (ERG) will show the functional activity of the retina (Figures 2 & 3).

Ocular ultrasonography is performed to confirm structural integrity of the retina, ruling out pre-existing retinal detachment (Figures 4 & 5, page 3). At Angell Animal Medical Center, ERG and ocular ultrasonography are performed under sedation.

In eyes with healthy retinas, cataract surgery can be elected. Modern cataract surgery uses an ultrasonic phacoemulsification probe to break up and extract the lens through a small ~3mm incision. An intraocular lens (IOL), made of acrylic, is then implanted in the majority of cases to improve focusing ability. (For a video of a recent cataract surgery performed by Dr. Coster, visit tinyurl.com/costersurgery. For a history of advances in cataract surgery, see Bellan, 2008 at www.medscape.com/viewarticle/579850_2, and for the development of IOLs by

Sir Harold Ridley, see Apple, 2006 at www.haroldridley.com/TableofContents.html.)

A recent advance in cataract surgery involves the treatment of lens subluxation with a surgical device called a Capsular Tension Ring (to see a recent implant performed by Dr. Coster, visit tinyurl.com/costerimplant. Often, the decision to implant a CTR is made intraoperatively, and CTRs have allowed the placement of IOLs into eyes that otherwise would not have received them, improving functional vision.



∇ **Figure 3:** Electroretinogram tracing, showing a normal waveform. The amplitude of the b-wave (4-3; the greatest peak) was 208μV; generally any value greater than 100μV is considered healthy. This dog underwent successful cataract surgery.

Post-operatively, cataract surgery is generally considered to have an excellent success rate in vision restoration, typically 90-95% in the immediate post-operative period. Numerous peer-reviewed articles have examined the success and complication rates following phacoemulsification cataract surgery in the dog, and a summary is provided in Table 1 on page 3. Additionally, the present author performed a meta-analysis on the available data from these studies, presented in Table 1.

Glaucoma and retinal detachment are the most significant potential post-operative complications, due to ensuing blindness. Post-operative ocular hypertension is generally a transient and treatable increase in pressure of the eye, and is the reason we hospitalize our patients at Angell for overnight monitoring following surgery. The reported uveitis rate refers to clinically significant uveitis, as the large majority of cataract patients will have post-operative inflammation to some extent.

> **Continued on Next Page**

> **Lifting the Veil: Canine Cataracts & Cataract Surgery** (Continued from Page 2)

| Table 1: Summary of 9 major reviews of success and complication rates | | | | | | | | | | |
|---|---------------------|----------|--------------------|--------------------|---------------------|------------------------|---------------------|---------------------|---------------------|---------------|
| Year | 1987 | 1991 | 1996 | 2000 | 2001 | 2005 | 2006 | 2006 | 2011 | Weighted |
| Author | Miller ⁵ | Davidson | Smith ⁶ | Biros ⁷ | Lennek ⁸ | Johnstone ⁹ | Sigle ¹⁰ | Appel ¹¹ | Klein ¹² | Meta-Analysis |
| No. Dogs | 56 | 182 | 88 | 220 | 154 | 143 | 172 | 108 | 103 | 1226 |
| No. Eyes | 82 | 296 | 139 | 346 | | 244 | 290 | 203 | 179 | 1779 |
| Vision (%) | 71-94 | 95 | | | | 87 | 80-95 | 92 | 83 | 86% |
| POH (%) | 38 | | 49 | | | 34 | | | 23 | 25% |
| Uveitis (%) | 15 | | | | | 8 | | | 16 | 9% |
| PCO (%) | 11 | 65 | | | | | 69 | | | 60% |
| Glaucoma (%) | 4.8 | 3 | | 16.8 | 14 | 11 | 12.4 | | 6.7 | 11% |
| RD (%) | 4.8 | 4.7 | | | | 3 | 1-2 | | 8.4 | 4% |
| Bleeding (%) | | 2 | | | | | 2 | | 12 | 5% |
| Corneal Opacity (%) | 29 | | | | | | 2 | | 19 | 9.5% |

Table 1: Summary of 9 major reviews of success and complication rates following phacoemulsification cataract surgery in the dog. Blank spaces indicate data were not available in the published article. Weighted meta-analysis was performed by the present author on available data. POH, Post-operative ocular hypertension; PCO, posterior capsular opacification; RD, retinal detachment.

Posterior capsular opacification (“after cataract”) of the remnant lens capsule is a very common phenomenon, but is rarely clinically significant in this author’s opinion. Intraocular hemorrhage and corneal opacification are of variable significance.

In a study of client satisfaction following cataract surgery, at 12 months follow-up, 81% of owners were satisfied with their decision to pursue surgery (whereas 95% of evaluating clinicians were satisfied with the dog’s visual outcome).¹³ Dissatisfaction reasons included vision loss as assessed by the owner (8%), diabetic control (3%), perceived poor value for money (1%), and unrelated neoplastic processes (2%). “Dissatisfied owners were significantly more likely to report that explanation of risks and complications

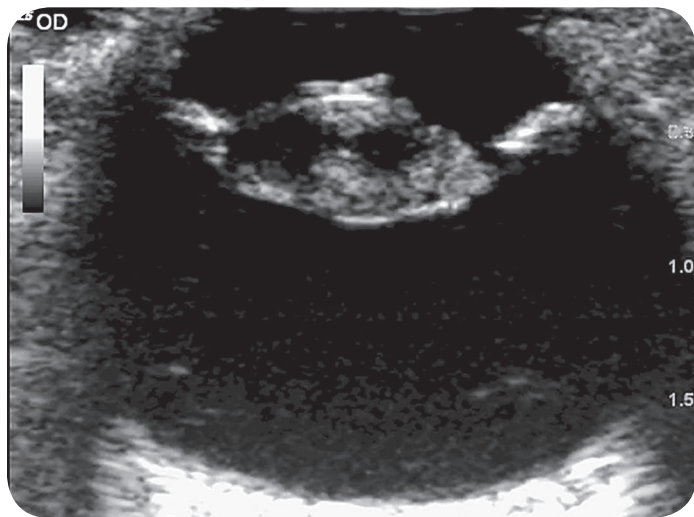


Figure 4: Ocular ultrasound of an eye with cataract (cornea is at the top of the image, retina at the bottom). The retina is not detached; this eye underwent successful cataract surgery.

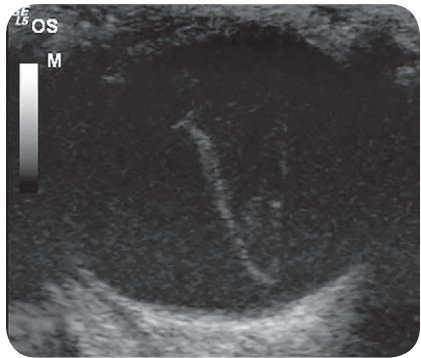


Figure 5: Ocular ultrasound of an eye with retinal detachment (the retina is the V-shaped structure in the vitreous). This eye was not a candidate for surgery. (This oblique view of the globe does not clearly show the lens; the cornea is at the top of the image.)

before surgery was inadequate.” However, dissatisfied owners also did not return for follow-up, which is an essential component of success.

In conclusion, cataract surgery is an elective procedure that offers a high rate of success in restoring vision to compromised eyes. Involvement of an ophthalmologist as early as possible in the process of cataractogenesis is recommended, so that adequate client education, monitoring, and timely medical and surgical intervention can be performed, maximizing success.



For more information about Angell’s Ophthalmology service, please visit angell.org/eyes. Drs. Coster and Biros are available for consults or referrals at 617-541-5095, or e-mail ophthalmology@angell.org.

> Continued on Page 11

Wynnie: A Case Study of Nasopharyngeal Stenosis



By Kirstin Johnson

angell.org/internalmedicine
internalmedicine@angell.org
617-522-7282

Wynnie, a female spayed Yorkie, originally presented at one year of age with the primary complaint of stertor. Wynnie was obtained from a breeder in South Carolina. When her owners picked her up, they noticed her stertorous breathing immediately. The breeder explained that she had been breathing normally until a couple of weeks after being spayed.

At the time of initial presentation, Wynnie had a normal appetite and energy level with no appreciable nasal discharge. Thoracic radiographs were taken and were normal. A CBC, chemistry panel, and fecal float were within normal limits. Several treatments had been attempted to improve her unusual respiratory sounds including Claritin, Clavamox, and a tapering dose of steroids. None of the treatments were successful. Wynnie's stertorous breathing did not improve nor progress. Besides the presence of stertor and decreased airflow through both nostrils, Wynnie's physical exam was normal.

Based on Wynnie's history of developing stertor soon after anesthesia, our number one rule out was nasopharyngeal stenosis, secondary to aspiration rhinitis. Other conditions ruled out include congenital nasopharyngeal stenosis and nasopharyngeal polyps with lessor consideration for inflammatory rhinitis (such as lymphoplasmacytic vs. infectious rhinitis; including fungal vs. bacterial and foreign body infections). Nasal mites were also less likely since sneezing was not a clinical sign mentioned.

Our diagnostic plan included a CT scan of the nose followed by retroflex endoscopic evaluation of the nasopharynx. Several months went by before Wynnie returned for her diagnostics. Within this time, she did develop nasal discharge which improved with doxycycline; however, the stertor persisted.

When Wynnie returned for her CT scan, she had been off antibiotics for a couple of weeks with now persistent mucoid nasal discharge and unchanged stertor. Wynnie was placed under general anesthesia without complication. A nasal CT scan using 1mm slices was performed and was suspicious for nasopharyngeal stenosis beginning just caudal to the choanae

and affecting about 12mm of the nasopharynx. Secondary bilateral nasal congestion was also noted as well as mild left and medial retropharyngeal lymphadenopathy. An endoscopic retroflex view of the back of the nasal passages confirmed the stenosis. A membrane was found across the nasopharynx with a small opening seen on the left side. The choanae could not be visualized. Rigid rhinoscopy revealed a large amount of mucoid discharge and some irregularities to the nasal mucosa in both nasal passages. Biopsy samples were obtained and the right nasal passage was cultured. Biopsy results revealed only mild mixed lymphoplasmacytic and neutrophilic inflammation. There was no growth on aerobic culture. Mycoplasma PCR and Cryptococcus antigen tests were negative. Wynnie was sent home with Cerenia to decrease nasal inflammation and Zertec.

Nasopharyngeal stenosis can occur as a congenital anomaly or secondary to an inflammatory condition such as chronic rhinitis or aspiration rhinitis from regurgitation. Surgery in this area and a space-occupying lesion can also result in nasopharyngeal stenosis. This condition is more common in cats than in dogs. In cats, nasopharyngeal stenosis is more frequently associated with chronic rhinitis or a congenital deformity. In dogs, aspiration rhinitis is the most common cause.

Treatment options for nasopharyngeal stenosis include surgical correction, balloon dilation and placement of a stent. We discussed treatment options with Wynnie's owner. Surgical resection of the stenotic tissue via a transpalatal approach did not seem the best choice for Wynnie since we hypothesized that her stenosis came about due to an inflammatory condition caused by aspiration rhinitis. When inflammation is present, surgical correction is more likely to fail due to recurrence of the stenosis. Wynnie's lesion was more than 1cm rostral to the end of the soft palate making her a good candidate for stenting. When a stent is placed more caudal than this, the patient is not able to compress this portion of the soft palate during eating which leads to signs of exaggerated swallowing and gagging. Wynnie's owner was not comfortable with the idea of placing a stent. Instead, she chose balloon dilation for Wynnie understanding that serial balloon procedures would likely be needed.

Wynnie's CT scan was used to measure the normal nasopharyngeal lumen diameter and the length of the stenosis. A balloon was then located that was an appropriate diameter and length. The following week, Wynnie returned for her balloon dilation procedure.

Wynnie was again anesthetized without complication. She was initially placed in dorsal recumbency and a retroflexed endoscopic view of the nasopharynx confirmed there was no change to the stenotic lesion. Wynnie was then placed in lateral recumbency and under fluoroscopic guidance; a guide wire was passed down her left nostril into her oropharynx. A balloon

> Continued on Next Page

> Wynnie: A Case Study of Nasopharyngeal (Continued from Page 4)



Wynnie relaxing at home.

catheter was then passed over the guide wire and situated in the area of her stenosis. The first balloon catheter was 3cm long and had an inflation diameter of 8mm. The inflation of this balloon was monitored with fluoroscopy and was maintained for 1 minute; then repeated. A second balloon measuring 3cm long with a dilation diameter of 10mm was then used in a similar fashion and repeated. At the end of the procedure, the deflated 10mm balloon catheter was passed down both nostrils into the oropharynx without resistance. A repeat retroflex view of the oropharynx showed a much wider opening.

Wynnie was sent home on a tapering dose of steroids. Within a week, her stertor returned. The balloon procedure was repeated. This time the stenosis was found to be wider than before the first dilation. Also the repeat balloon dilation resulted in an opening wider than that made during the first dilation. Wynnie was again sent home with a tapering dose of steroids, but also started on colchicine. Four weeks after her second balloon procedure, Wynnie returned with stertor. Again, the stenosis was improved when compared with the opening we found before the second dilation. During this procedure, we were able to completely open the nasopharynx and could easily visualize the choanae. Wynnie is currently at home breathing normally. She is taking a tapering dose of prednisone and is still on colchicine, Cerenia, and Zertec. We are hopeful this was her last balloon procedure. If her stenosis returns, we will recommend placement of balloon-expandable metallic stent.



angell.org/internalmedicine

If you have questions about nasopharyngeal stenosis or stents, please contact **Dr. Johnson** at 617 522-7282 or kcjohnson@angell.org. ■

Angell Welcomes New Staff Doctors

We are delighted to welcome **Meghan Sullivan, DVM, DACVS** to Angell's **Surgery service** and **Ashley Barton-Lamb, DVM** to lead our **Anesthesia service**. Both doctors joined Angell following Labor Day.

Dr. Barton-Lamb graduated from Kansas State University, College of Veterinary Medicine and completed a rotating internship in equine medicine at the Mid-Atlantic Equine Medical Center in Ringoes, New Jersey. She recently completed her Anesthesia residency at Cornell University. Dr. Lamb will administer and oversee local and regional anesthesia across Angell's many specialty services and will partner closely with Lisa Moses, VMD, DACVIM, CVMA who leads our Pain Medicine service to ensure maximum comfort and safety for Angell patients. Please visit angell.org/anesthesia for more information on this service.

Dr. Sullivan joins us from VCA Boston Road Animal Hospital in Springfield, MA. Dr. Sullivan attended Ross University School of Veterinary Medicine and completed her 4th clinical year of study at the University of Minnesota. She pursued a rotating internship in Small Animal Surgery and Medicine at Angell before completing a residency in small animal surgery at the University of Illinois where she received the ACVS Most Outstanding Resident Research Award.

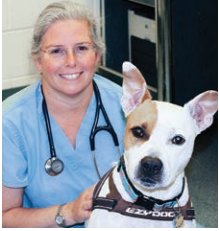
Dr. Sullivan has authored several scientific publications, enjoys lecturing at continuing education events and has received awards for excellence in teaching. Dr. Sullivan performs soft tissue, orthopedic, many neurosurgical procedures, minimally invasive surgery, laparoscopy and arthroscopy. Please visit angell.org/surgery for more information on our Surgery service.

LIKE ANGELL ON FACEBOOK!



Find out the latest CE Schedule and gain access to clinical articles by Angell's specialists at [facebook.com/AngellReferringVeterinarians](https://www.facebook.com/AngellReferringVeterinarians) with content prepared just for our referring partners.

Practical Tips for Reducing NSAID Toxicity



By Lisa Moses,
VMD, DACVIM, CVMA

angell.org/painmedicine
painmedicine@angell.org
617-541-5140

Do you hesitate to prescribe NSAIDs to your patients for fear of adverse effects? If so, you may be unnecessarily depriving animals of effective pain relief, especially in the post-operative or trauma setting. In the Pain Medicine Clinic at Angell Animal Medical Center, we spend a lot of time managing NSAID side effects or safe use in patients that really need the benefits of these useful drugs. Our hope is that prescribers can feel comfortable managing the risks associated with NSAID use so their use is not avoided needlessly.

Appropriate Patient Selection for NSAID Use

The “art” of NSAID use is in assessing risks for complications and relative contraindications.

Basic contraindications for use are:

- Active vomiting or diarrhea
- Known GI ulceration
- Dehydration
- Pre-existing renal or hepatic dysfunction
- Known conditions that pose potential for immediate organ dysfunction (e.g., sepsis, heart failure)
- Concurrent or recent use of other NSAIDs or corticosteroids
- < 12 weeks of age

Some of these contraindications should be strictly followed. Dogs with active gastrointestinal disease and those recently receiving other NSAIDs or corticosteroids are at an increased risk of GI ulceration. Puppies younger than 12 weeks of age do not have fully matured renal protective mechanisms and can have permanent renal damage from NSAID use, although some authors believe that after eight weeks of age the risks are minimal with a single dose or short course.

Dogs with pre-existing hepatic and/or renal dysfunction are at greater risk from adverse effects, due to reduced excretion

and disruption of normal protective mechanisms. NSAIDs are primarily excreted through hepatic metabolism with some renal involvement. The decision to use NSAIDs in patients with known renal or hepatic dysfunction must be made only when owners are willing to accept the known risks in exchange for benefits in patients suffering without NSAIDs.

Initial NSAID Drug Selection and Dosing Strategies

Due to the narrow therapeutic index of NSAIDs in dogs and the known toxicities, use of an NSAID that is FDA approved for dogs is important. In particular, aspirin is known to cause gastric lesions in virtually 100% of dogs when given at published doses. Despite the well-publicized risk of GI ulceration in FDA-approved NSAIDs, this risk is still considerably less than with aspirin.

All approved NSAIDs for dogs have very similar statistical rates and proportions of GI, renal, and hepatic toxicity. Because of this and the lack of clear data demonstrating greater analgesic efficacy of a particular NSAID, the initial choice of a particular drug can be made using factors that improve compliance or convenience. An NSAID that a dog has tolerated in the past is often a good first choice. Because of the wide variety in formulations, sizes, and palatability, pick a drug after consultation with the owner to help insure compliance.

NSAIDs can often be dosed as “to effect” drugs when used long-term for chronic pain, but usually require full daily dosing at the beginning of therapy, when pain is at its peak. To minimize risk, consider label doses and dosing intervals as the maximum dose. If relative contraindications to use are present, consider reducing the initial dose and/or increasing the dose interval.

Veterinarians frequently prescribe courses that are too short to adequately reduce inflammation or for the expected duration of pain. Presumably this is due to either fear of adverse effects with longer courses or discomfort with assessing pain. NSAIDs, like any analgesic, must be given as long as the patient shows signs of pain, regardless of our expectation of the time course for resolution of the problem. If we or owners cannot assess pain, then we can at least use the anthropomorphic approach to estimating how long a given problem will cause pain (i.e., how long would a person with this problem feel pain). In cases where we are attempting to prevent persistent, chronic pain syndromes, this is particularly important.

NSAIDs and Client Communication Necessities

Well-informed clients, given specific information about risk, are fundamental to reducing NSAID risk. Compliance surveys of pet owners reveal surprising rates of non-prescription NSAID administration to dogs — alarmingly, often without a veterinarian’s knowledge. When questioned, pet owners

> Continued on Next Page

> Practical Tips (Continued from Page 6)

may not understand the basic facts of NSAID use, including that anti-inflammatory medication is analgesic or even why an NSAID was prescribed for their dog. Ask, more than once, whether the dog is receiving any other oral or topical medication; any OTC medication; or has been prescribed medication by another veterinarian. Owners may tell technicians this information, but not veterinarians, so have multiple staff members ask the question.

Client communication fundamentals before prescribing:

- Explain why an NSAID is being prescribed and its intended effect
- Explicitly state the known risks
- Inform owners that dogs are more likely than humans to develop GI toxicity from NSAIDs, especially if multiple types are given concurrently
- Describe why you believe the benefits outweigh the risks in this specific patient
- Advise owners of their pivotal roles in reducing the risk
- Provide clear instructions for what to do in the case of suspected adverse events
- Outline a plan for drug monitoring if NSAIDs are to be used chronically

All of this information should be given to a client verbally, so they can ask clarifying questions. Additionally, there are excellent written resources available that can be provided to clients. Both AAHA and the FDA have free, downloadable handouts for client use, as do several of the NSAID manufacturers.

Clients should be clearly instructed, both verbally and on the medication label, to:

- Only give the medication when the appetite is normal and after the pet has eaten
- Monitor their pet for loss of appetite, vomiting, or any change in stool color or consistency
- Discontinue use if they see any of these signs and contact the prescriber



angell.org/painmedicine

If you have specific questions about safe NSAID use or difficult cases, feel free to contact Dr. Moses of the Angell Pain Medicine Service at **617-541-5140** or via e-mail painmedicine@angell.org ■

Upcoming Angell CE Seminars

Please visit angell.org/ce to register or call **617-522-5011** for more information.

Upper Airway Stenting: Indications, Complications, and Case Reports

Wednesday, October 9, 2013

6:15 p.m. – 8:45 p.m.

2 CE Credits (pending R.A.C.E. approval)

Register by October 2, 2013 at angell.org/ce

CE Location:

Hilton Hotel – Dedham, 25 Allied Drive, Dedham, MA
(at the intersection of Route 128 and Route 1)

Speakers:

Maureen Carroll, DVM, DACVIM

Erika de Papp, DVM, DACVIM

Shawn Kearns, DVM, DACVIM

Kirstin Johnson, DVM, DACVIM

Topics:

Overview of tracheal collapse, indications for upper airway stenting, nasopharyngeal stenosis, case reviews, and more.

Complimentary dinner and lecture for veterinarians.

Thank you to our sponsor:



Kidney Disease: Prevention and Management of Complications

Sunday, November 3, 2013

8:00 a.m. – 4:00 p.m.

5 CE Credits (pending R.A.C.E. approval)

Register by October 23, 2013 at angell.org/ce

CE Location:

Hilton Hotel – Dedham, 25 Allied Drive, Dedham, MA
(at the intersection of Route 128 and Route 1)

Speakers:

Maureen Carroll, DVM, DACVIM

Erika de Papp, DVM, DACVIM

Shawn Kearns, DVM, DACVIM

Kirstin Johnson, DVM, DACVIM

Topics:

Lyme disease; from arthritis to nephritis and everything in between; Soft-coated wheaten terrier PLN/PLE; Dialysis: indications and options; Update on current practices and controversies in management of chronic kidney disease.



angell.org/ce

Pricing at angell.org/ce. Open to veterinarians, veterinary technicians, and veterinary students.

Radiographic Approach to the Coughing Pet



By Steven Tsai,
DVM, DACVAR

angell.org/diagnosticimaging
diagnosticimaging@angell.org
617-541-5139

Thoracic radiographs in the coughing dog or cat can present a significant interpretive challenge for even the most experienced veterinarians. Evaluating the heart, pulmonary vessels, and pulmonary parenchyma provides a minimum baseline for determining the cause of a patient's respiratory signs. Of those three, the pulmonary parenchyma typically poses the greatest challenge, as there is great variability and overlap between what normal and abnormal lungs look like. Cardiovascular structures, on the other hand, tend to be either big, or not big. This article will focus on radiographic evaluation of the pulmonary parenchyma, with brief overviews of both the classical pattern-based approach and an alternative approach based on macroscopic distribution of pulmonary abnormalities.

Most veterinarians are taught some version of the classical approach to pulmonary interpretation, focusing on the differences between interstitial, alveolar, and bronchial patterns. A distinction should be made between interstitial and alveolar patterns on the one hand, and bronchial patterns on the other, since two different sets of disease processes will typically lead to those two groups of patterns. The catch-all term "bronchointerstitial" is, therefore, somewhat unhelpful for

narrowing down the differential list, since it encompasses nearly all causes of diffuse pulmonary disease. It is best to determine whether the primary pattern is bronchial, interstitial, or truly both at the same time.

Interstitial and alveolar patterns essentially sit at different points on a continuum and are created by degrees of increased pulmonary opacity which partially or completely obscure the pulmonary vessels. If pulmonary vessels are visible but have fuzzy margins, giving the appearance of "trees in a fog," that is an interstitial pattern. If the vessels are completely obscured, that is an alveolar pattern (Figure 1). Air bronchograms may or may not be present in an alveolar pattern. In either case, the radiographic signs are caused by an accumulation of fluid (edema), hemorrhage, or cellular infiltrate (inflammatory or neoplastic) within the pulmonary interstitium, bronchioles, or alveoli. Interstitial and alveolar patterns can also be caused by partial or complete lung collapse (such as secondary to prolonged lateral recumbency), and typically is accompanied by a mediastinal shift towards the abnormal lung in that case. Typical differentials for interstitial and alveolar patterns in dogs include: cardiogenic or noncardiogenic pulmonary edema, bronchopneumonia (of which aspiration pneumonia is a sub-category), fibrosis, metastatic neoplasia, and pulmonary hemorrhage. The list for cats is similar, except that bronchopneumonia is exceedingly rare in cats and generally should not be considered in the absence of a recent anesthesia event or neurologic dysfunction which would impair the robust feline laryngeal reflex. In one study, out of over 31,000 cat necropsies during a 10 year period at a veterinary teaching hospital, only 39 cases of confirmed infectious pneumonia were found, and only 6 of those were attributable to aspiration of gastric contents.¹

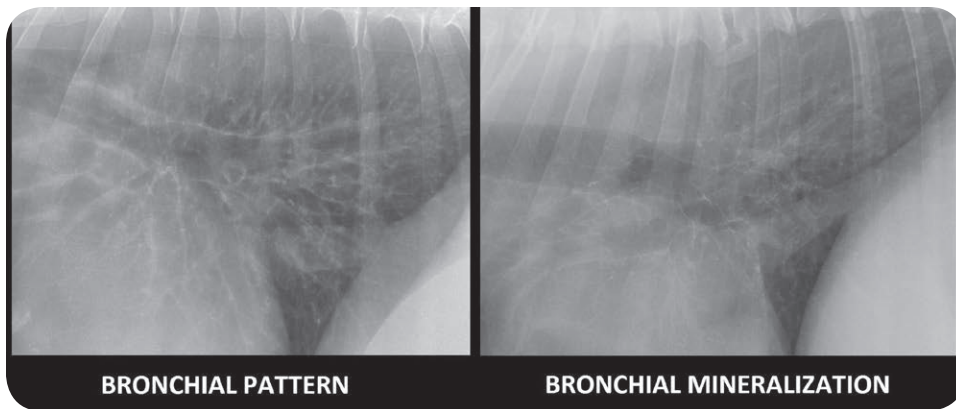
Bronchial patterns are generally distinct from interstitial and alveolar patterns, with the primary cause being thickening of the larger, conducting airways. The radiographic signs of a bronchial pattern are ring-like opacities ("donuts") and parallel lines ("tram

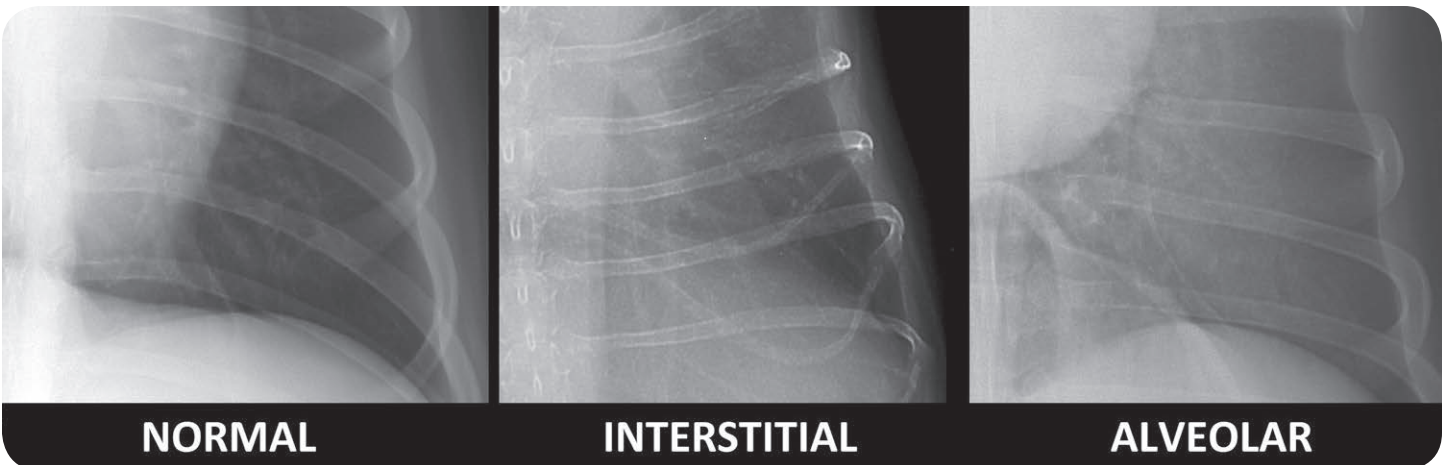

Figure 1: Zoomed in images of the left caudal lung on a ventrodorsal projection in three dogs.

> Continued on Next Page

> Radiographic Approach to the Coughing Pet (Continued from Page 8)



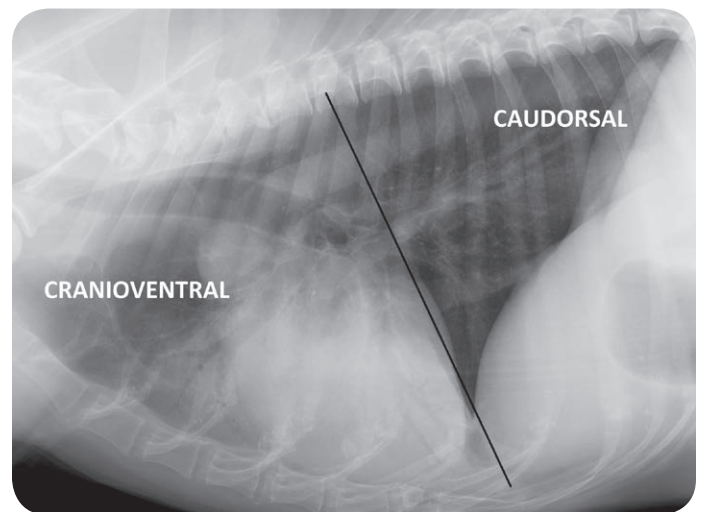
↘ Figure 2: Caudodorsal lungs on a lateral view in two dogs. Note the significant thickening of airways in the image on the left, compared with the thin-walled appearance of mineralized bronchi on the right. Bronchial mineralization is a common incidental finding in geriatric patients.

lines"). In cats, only donuts are recognizable, as the bronchi are generally too small to create visible tram lines. The appearance of the bronchial pattern may be exacerbated by an indistinct opacity surrounding the airway, termed "peribronchial cuffing." This often leads to the bronchointerstitial appearance, but it is important to recognize that the bronchial pattern is the major one in these cases, as most often this indicates more severe or acute airway inflammation. Another common cause of a bronchointerstitial pattern is age-related fibrosis and mineralization of the interstitium and airways. Age-related bronchial mineralization leads to thin-walled, distinct bronchial opacities as opposed to the thick-walled, slightly indistinct appearance typical of a true bronchial pattern (Figure 2). For a true bronchial pattern, the primary differential is chronic lower airway disease of allergic (e.g. feline asthma, chronic bronchitis), infectious (e.g. tracheobronchitis a.k.a. "kennel cough"), or parasitic (e.g. lungworm, heartworm) etiology.

While recognizing the distinction between interstitial/alveolar and bronchial patterns is important, an alternative method stresses the importance of lesion distribution.² With the exception of distinct nodules or masses, most pulmonary lesions are distributed cranioventrally, caudodorsally, multifocally, or asymmetrically. Cranioventral encompasses the entire left cranial, right cranial, and right middle lung lobes and is most commonly associated with bronchopneumonia, hemorrhage, neoplasia, and lung lobe torsion. Caudodorsal encompasses the left caudal, right caudal, and accessory lobes and is most commonly associated with cardiogenic or noncardiogenic pulmonary edema, pulmonary fibrosis, or neoplasia (Figure 3). It should be noted that there is no difference in the distribution of cardiogenic and noncardiogenic edema; differentiation is based on presence or absence of cardiomegaly or pulmonary venous enlargement. Feline cardiogenic edema is most commonly multifocal, often ventral, and commonly accompanied by variable degrees of pleural effusion. Metastatic carcinoma in cats also frequently presents as a multifocal indistinct pattern.

Asymmetric lesions are most commonly seen with trauma (contusions), neoplasia, or bronchopneumonia.

By integrating the radiographic pattern and distribution along with the patient's signalment, history, and physical exam findings, one can very often narrow down the source of coughing to cardiogenic, airway, or pulmonary parenchymal causes. Usually each cause branches further into just one or two reasonable differentials for the individual



↘ Figure 3: Lateral view of a thorax delineating the difference between cranioventral and caudodorsal distribution. Note the air bronchograms indicating a cranioventral alveolar pattern in this dog, consistent with aspiration pneumonia.

patient, which may require an additional diagnostic test (tracheal wash, heartworm test, etc.) or therapeutic trial (a dose of furosemide, a couple puffs of albuterol, etc.) to narrow down to a working clinical diagnosis.



angell.org/diagnosticimaging

For more information on Angell's Diagnostic Imaging service or our online imaging consultative services, please visit angell.org/diagnosticimaging. Dr. Tsai can be reached at 617-541-5139 or via e-mail diagnosticimaging@angell.org. ■

References:

1. Macdonald E, Norris C, Berghaus R, Griffey S. Clinicopathologic and radiographic features and etiologic agents in cats with histologically confirmed infectious pneumonia: 39 cases (1991-2000). *J Am Vet Med Assoc* 2003; 223(8): 1142-50.
2. Nykamp SG, Scrivani P, Dykes N. Radiographic signs of pulmonary disease: An alternative approach. *Compendium* 2002; 24(1): 25-35.
3. T Schwartz and V Johnson. *BSAVA Manual of Canine and Feline Thoracic Imaging*, ed., British Small Animal Veterinary Association, Gloucester 2008;

Melatonin for Primary Immune-Mediated Thrombocytopenia (ITP)



By Megan Whelan,
DVM, DACVECC

angell.org/emergency
emergency@angell.org
617-522-7282

Melatonin is a naturally occurring compound that is found in animals, plants such as St. John's wort, and microbes.¹ It is classified by the United States Food and Drug Administration as a dietary supplement and can be bought at supermarkets, commonly in 3mg capsule form. In comparison, in the United Kingdom it is available by prescription only.² Due to the fact that it is a supplement, and not a drug, other ingredients may be found in the product.

In mammals, melatonin is synthesized from the dietary amino acid tryptophan. Melatonin is produced by the pineal gland and released into the bloodstream; therefore, it is a hormone. Melatonin is involved in the circadian rhythm and acts as a free-radical scavenger. In human medicine, it has been used for a number of medical issues such as mood disorders, immune disorders, obesity etc. In general, it has minimal side effects, but humans have described feeling drowsy after taking it.

In animals, its use has been reported in alopecia cases such as Alopecia-X or flank alopecia, and anecdotally in cases of older animals that have cognitive dysfunction for aiding in sleep. The dose range in Plumb's Veterinary Drug Handbook in dogs is 3-6mg PO SID or BID depending on the weight of the patient or as an implant.³ Regular melatonin should be used instead of the rapid release or extended release formulations. More recently, it has been suggested as a non-immunosuppressive, alternative agent that can be used for immune diseases such as primary immune-mediated thrombocytopenia (ITP). In the human literature, there are reports of its use for refractory ITP in 3 cases and to stop severe bleeding symptoms in 1 case of ITP.^{4,5} There is little information on this supplement in veterinary literature, but it is thought that melatonin stimulates platelet generation by promoting the megakaryocyte fragmentation and modulating the cytokines that are involved in the production of platelets.⁶ Primary ITP is a disease caused mainly by destruction of platelets, that is why treatment efforts are focused on immunosuppression. However, if platelet production could be increased in the blood via the use of melatonin, this may help prevent life threatening bleeds and the need for transfusions.

In conclusion, melatonin appears to be a safe supplement with minimal side effects. However, its efficacy in canine ITP has yet to be determined. Anecdotally, I have used it in a refractory ITP case that did eventually go into remission, but it is difficult to say if it was just the additional time on the immunosuppressive drugs or if it was the addition of this supplement that caused the improvement. The efficacy of melatonin in this disease warrants further investigation in canines due to its minimal cost and minimal side effects. A double-blind, placebo-controlled, prospective study would need to be conducted comparing dogs that received either prednisone and melatonin or prednisone alone for primary ITP.



angell.org/emergency

For more information about Angell's Emergency service, please visit angell.org/emergency. For consults or referrals, please call 617 522-7282, or e-mail emergency@angell.org. ■



References:

1. www.wikipedia.org/wiki/Melatonin
2. Ibid.
3. Plumb, DC. *Plumb's Veterinary Drug Handbook*, 7th Edition.
4. Todisco M, Rossi N. Melatonin for refractory idiopathic thrombocytopenic purpura: a report of 3 cases. *Am J Ther* 2002; 9(6):524-526.
5. Todisco M, Casaccia P, Rossi N. Severe bleeding symptoms in refractory idiopathic thrombocytopenic purpura: a case of successfully treated with melatonin. *Am J Ther* 2003; 10(2):135-136.
6. Nakamura RK, Tompkins E, Bianco D. Therapeutic options for immune-mediated thrombocytopenia. *J Vet Emerg Crit Care*. 2012; 22(1): 59-72.
7. *J Vet Emerg Crit Care*. 2012; 22(1): 59-72.

> Lifting the Veil: Canine Cataracts & Cataract Surgery (Continued from Page 3)

References:

1. Beam et al, 1999. *Cesk Radiol.* 1975 May;29(3):160-3. [The use of Frickle dosimeter for the purpose of comparative measurements in clinical practice (author's transl)]. www.ncbi.nlm.nih.gov/pubmed/1139726
2. Lim et al, 2011. *Can Vet J.* 2011 March; 52(3): 283–288. Cataracts in 44 dogs (77 eyes): A comparison of outcomes for no treatment, topical medical management, or phacoemulsification with intraocular lens implantation www.ncbi.nlm.nih.gov/pmc/articles/PMC3039899/
3. Williams & Golitz, 2012, Abstract #119, www.onlinelibrary.wiley.com/doi/10.1111/j.1463-5224.2012.01072.x/pdf
4. Kador et al, 2010. *Vet Ophthalmol.* 2010 Nov;13(6):363-8. doi: 10.1111/j.1463-5224.2010.00826.x. Topical KINOSTAT™ ameliorates the clinical development and progression of cataracts in dogs with diabetes mellitus. www.ncbi.nlm.nih.gov/pubmed/21182720
5. Miller et al, *J Am Vet Med Assoc.* 1987 Jun 15;190(12):1577-80. Phacofragmentation and aspiration for cataract extraction in dogs: 56 cases (1980-1984). www.ncbi.nlm.nih.gov/pubmed/3610770
6. Smith et al, *J Am Vet Med Assoc.* 1996 Jul 1;209(1):105-11. Ocular hypertension following cataract surgery in dogs: 139 cases (1992-1993). www.ncbi.nlm.nih.gov/pubmed/8926189
7. Biroš et al, *J Am Vet Med Assoc.* 2000 Jun 1;216(11):1780-6. Development of glaucoma after cataract surgery in dogs: 220 cases (1987-1998). www.ncbi.nlm.nih.gov/pubmed/10844971
8. Lannek et al, *J Am Vet Med Assoc.* 2001 Jan 1;218(1):70-6. Development of glaucoma after phacoemulsification for removal of cataracts in dogs: 22 cases (1987-1997). www.ncbi.nlm.nih.gov/pubmed/11149718
9. Johnstone et al: *Vet Ophthalmol.* 2005 Jan-Feb;8(1):47-50. The incidence of posterior capsule disruption during phacoemulsification and associated postoperative complication rates in dogs: 244 eyes (1995-2002). www.ncbi.nlm.nih.gov/pubmed/15644100
10. Sigle et al: *J Am Vet Med Assoc.* 2006 Jan 1;228(1):74-9. Long-term complications after phacoemulsification for cataract removal in dogs: 172 cases (1995-2002). www.ncbi.nlm.nih.gov/pubmed/16426170
11. Appel et al: *J Am Vet Med Assoc.* 2006 Mar 15;228(6):870-5. Evaluation of client perceptions concerning outcome of cataract surgery in dogs. www.ncbi.nlm.nih.gov/pubmed/16536695
12. Klein et al: *Vet Ophthalmol.* 2011 Mar;14(2):114-20. doi: 10.1111/j.1463-5224.2010.00853.x. Postoperative complications and visual outcomes of phacoemulsification in 103 dogs (179 eyes): 2006-2008. www.ncbi.nlm.nih.gov/pubmed/21366827
13. Appel et al: *J Am Vet Med Assoc.* 2006 Mar 15;228(6):870-5. Evaluation of client perceptions concerning outcome of cataract surgery in dogs. www.ncbi.nlm.nih.gov/pubmed/16536695
14. Ibid.

REFERRAL CONTACT INFORMATION

For additional information, please contact Eleanor Cousino, Angell Referral Coordinator, at **617 522-5011**, or by fax at **617 989-1635**. You may also find our appointment hours at angell.org/hours.

Anesthesiology Service

Referral Contact: Kim Swank
Referral Line: 617 541-5048
Referral Fax: 617 989-1660
E-mail: anesthesia@angell.org
angell.org/anesthesia

Avian & Exotic Medicine Service

Referral Contact: Stacey Escalante
Referral Line: 617 989-1561
Referral Fax: 617 989-1668
E-mail: avianexotic@angell.org
angell.org/avianandexotic

Cardiology Service

Referral Contact: Rebecca Stlaske
Referral Line: 617 541-5038
Referral Fax: 617 989-1653
E-mail: cardiology@angell.org
angell.org/cardiology

Dentistry Service

Referral Contact: Michael Johnson
Referral Line: 617 524-5643
Referral Fax: 617 989-1636
E-mail: dentistry@angell.org
angell.org/dentistry

Dermatology Service

Referral Contact: Rebecca Stlaske
Referral Line: 617 524-5733
Referral Fax: 617 989-1613
E-mail: dermatology@angell.org
angell.org/dermatology

Diagnostic Imaging

Referral Contact: Radiology Staff
Referral Line: 617 541-5139
Referral Fax: 617 989-1617
E-mail: diagnosticimaging@angell.org
angell.org/diagnosticimaging

Emergency/Critical Care Service

Referral Line: 617 522-5011
Referral Fax: 617 989-1633
E-mail: emergency@angell.org
angell.org/emergency

Internal Medicine

Referral Contact: Eleanor Cousino
Referral Line: 617 522-5011
Referral Fax: 617 989-1635
E-mail: internalmedicine@angell.org
angell.org/internalmedicine

Neurology Service

Referral Contact: Lisa Canale
Referral Line: 617 541-5140
Referral Fax: 617 989-1666
E-mail: neurology@angell.org
angell.org/neurology

Nutrition

Referral Contact: Eleanor Cousino
Referral Line: 617 522-5011
Referral Fax: 617 989-1635
E-mail: nutrition@angell.org
angell.org/nutrition

Oncology Service

Referral Contact: Stacey Escalante
Referral Line: 617 541-5136
Referral Fax: 617 989-1668
E-mail: oncology@angell.org
angell.org/oncology

Ophthalmology Service

Referral Contact: Rachael Donnelly
Referral Line: 617 541-5095
Referral Fax: 617 989-1647
E-mail: ophthalmology@angell.org
angell.org/eyes

Pain Medicine Service

Referral Contact: Lisa Canale
Referral Line: 617 541-5140
Referral Fax: 617 989-1666
E-mail: painmedicine@angell.org
angell.org/painmedicine

Pathology Service (Clinical and Anatomical)

Referral Contact: Laboratory Staff
Referral Line: 617 541-5014
Referral Fax: 617 522-7356
E-mail: pathology@angell.org
*Sample submission forms and information at angell.org/lab

Surgery Service

Referral Contact: Kim Swank
Referral Line: 617 541-5048
Referral Fax: 617 989-1660
E-mail: surgery@angell.org
angell.org/surgery



350 South Huntington Ave.
Boston, MA 02130

angell.org
facebook.com/AngellReferringVeterinarians

Nonprofit Org.
US Postage
PAID
Permit No. 1141
Boston, MA

We mail one complimentary copy of our newsletter to each of our referring partners. Please circulate this copy within your practice.



Saturday/Sunday/Evening/
Early Morning Appointments:
Angell offers expanded appointment
hours for many services.
Please visit angell.org/hours.



Are your clients new to Angell?
Send them to angell.org/directions
for detailed directions to our location.
Ample free parking on site.

**We encourage you to e-mail
Angell's specialists with questions.
We hope you will use Angell as
a resource, and we look forward
to working with you as we
continue our legacy of providing
compassion and care for animals.**

Main Phone: 617 522-7282
Veterinary Referrals: 617 522-5011

Chief of Staff

Ann Marie Manning, DVM, DACVECC
amanning@angell.org

Anesthesiology

Ashley Barton-Lamb, DVM
abartonlamb@angell.org

Avian & Exotic Medicine

Elisabeth Simone-Freilicher, DVM,
DABVP (Avian Practice)
esimonefreilicher@angell.org

Cardiology

Nancy Laste, DVM, DACVIM
(Cardiology)
nlaste@angell.org
Rebecca Malakoff, DVM, DACVIM
(Cardiology)
rmalakoff@angell.org
Rebecca Quinn, DVM, DACVIM
(Cardiology and IM)
rquinn@angell.org

Dentistry

William Rosenblad, DVM
wrosenblad@angell.org

Dermatology

Klaus Loft, DVM
keloft@angell.org
Meghan Umstead, DVM
mumstead@angell.org

Diagnostic Imaging

Rebecca Manley, DVM, DACVR
rmanley@angell.org
Joan Regan, VMD, DACVR
jregan@angell.org
Steven Tsai, DVM, DACVR
stsai@angell.org

**Emergency & Critical
Care Medicine**

Kiko Bracker, DVM, DACVECC
kbracker@angell.org
Roxanna Khorzad, DVM
rkhorzad@angell.org
Megan Whelan, DVM, DACVECC
mwhelan@angell.org

Internal Medicine

Doug Brum, DVM
dbrum@angell.org
Maureen Carroll, DVM, DACVIM
mccarroll@angell.org

Erika de Papp, DVM, DACVIM
edepapp@angell.org

Jean Marie Duddy, DVM
jduddy@angell.org

Kirstin Johnson, DVM, DACVIM
kcjohnson@angell.org

Shawn Kearns, DVM, DACVIM
skearns@angell.org

Susan O'Bell, DVM, MPH, DACVIM
sobell@angell.org

Neurology

Allen Sisson, DVM, MS, DACVIM
(Neurology)
asisson@angell.org

Nutrition

Dana Hutchinson, DVM, DACVN
dhutchinson@angell.org

Oncology

Christine Anderson,
DVM, MS, DACVIM (Oncology),
DACVR (Radiation Oncology)
cranderson@angell.org

Jennifer Mahoney, DVM, DACVIM
(Oncology)
jmahoney@angell.org

Carrie Wood, DVM, DACVIM
(Oncology)
cawood@angell.org

Ophthalmology

Daniel Biro, DVM, DACVO
dbiros@angell.org

Martin Coster, DVM, MS, DACVO
mcoster@angell.org

Pain Medicine

Lisa Moses, VMD, DACVIM, CVMA
lmoses@angell.org

**Pathology
(Clinical & Anatomical)**

Patty Ewing, DVM, MS, DACVP
pewing@angell.org
Pamela Mouser, DVM, MS, DACVP
pmouser@angell.org

Surgery

Sue Casale, DVM, DACVS
scasale@angell.org
Michael Pavletic, DVM, DACVS
mpavletic@angell.org
Meghan Sullivan, DVM, DACVS
msullivan@angell.com
Nicholas Trout, MA, VET MB, MRCVS,
DACVS, DECVS
ntrout@angell.org