



# Partners In Care

Veterinary Referral News from Angell Animal Medical Center

Summer 2017 ■ Volume 11:2 ■ [angell.org](http://angell.org) ■ [facebook.com/AngellReferringVeterinarians](https://facebook.com/AngellReferringVeterinarians)

SEE INSIDE  
Referral Contact Info  
on a removable postcard!

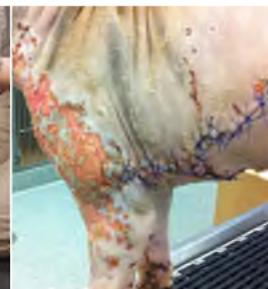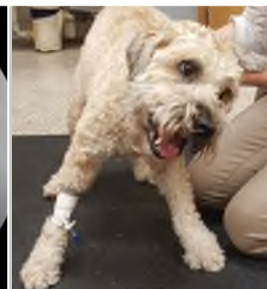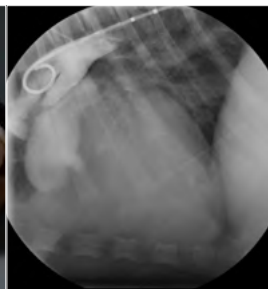ANESTHETIC MANAGEMENT  
OF BRACHYCEPHALIC DOGS

HELPING YOUR CLIENTS  
PICK THE RIGHT DOG  
TRAINER AND KNOWING  
WHEN A BEHAVIORIST IS  
NEEDED INSTEAD

CONGENITAL HEART  
DISEASE III: PATENT DUCTUS  
ARTERIOSUS IN THE CANINE  
AND FELINE PATIENT

ACUTE VESTIBULAR  
DISEASE IN OLD  
DOGS

NECROTIZING SOFT  
TISSUE INFECTIONS  
(NSTI)



PAGE 1

PAGE 1

PAGE 4

PAGE 7

PAGE 9

## ANESTHESIA



### Anesthetic Management of Brachycephalic Dogs

Stephanie Krein, DVM, DACVA

[angell.org/anesthesia](http://angell.org/anesthesia)  
[anesthesia@angell.org](mailto:anesthesia@angell.org)  
617-541-5048

## BEHAVIOR



### Helping Your Clients Pick the Right Dog Trainer and Knowing When a Behaviorist is Needed Instead

Terri Bright, Ph.D., BCBA-D, CAAB  
Director of Behavior Services

[angell.org/behavior](http://angell.org/behavior)  
[behavior@angell.org](mailto:behavior@angell.org)  
617-989-1520

**B**rachycephalic breeds, including Pugs, French Bulldogs, English Bulldogs, American Bulldogs, and Boston Terriers, can be some of the most difficult animals to anesthetize and present unique challenges that do not exist among other breeds. This article will discuss the anatomic and physiologic differences that can affect the outcome of anesthesia and ways to deal with these differences.

Brachycephalic dogs have anatomic considerations that may affect anesthetic outcomes.<sup>1</sup> Many brachycephalic breeds suffer from brachycephalic airway syndrome (BAS), which includes the presence of stenotic nares, elongated soft palate, everted laryngeal sacculles, and hypoplastic trachea, and have narrower and smaller upper airways than dogs with a normal anatomy.<sup>2,3,4</sup> These narrow airways increase resistance and the work of breathing. This becomes particularly important during times of stress when the respiratory rate increases and the flow becomes turbulent, further increasing the work of breathing. It is important when anesthetizing a brachycephalic dog to be prepared at all times for upper airway obstruction. These dogs must be monitored closely after premedication, throughout anesthesia, into the postoperative period, and after extubation into the recovery period. An oxygen source and endotracheal tube should always be readily available, even after extubation. Regurgitation or reflux is always a concern when sedating

**H**aving the best referral information at your fingertips can make your day go more smoothly and make you into a hero to your clients, and this is never truer than when your patients have behavioral problems. In the case of a sudden behavior change, rule out medical issues in your patient before making a behavioral referral, then refer to these steps to make your referral decision:

**Socialization classes:** All puppies should be properly socialized to people and other dogs before they are 12 weeks old. The American Veterinary Society of Animal Behaviorists has a position statement about this, stating "Incomplete or improper socialization...can increase the risk of behavioral problems later in life, including fear, avoidance and/or aggression" (<https://avsab.org/resources/position-statements/>). It goes on to say that behavioral issues, not illness, are the number one cause of death in dogs under three years old. Therefore, it behooves you to consider the risk/benefit of exposure of your client's puppies to other dogs before being completely vaccinated, and to have a serious discussion with clients about proper socialization. A simple requirement that a puppy going to a socialization class must be seen by a vet at least once since the owner got it can help to limit risk. A good puppy class is far less risky for health and behavior than a dog park. At a well-run puppy class, puppies can be

(CONTINUED ON NEXT PAGE)

(CONTINUED ON PAGE 3)

## ANESTHESIA

Continued from page 1



or anesthetizing brachycephalic dogs and one should be prepared if this should happen. Preventative measures should be taken with all brachycephalic dogs undergoing sedation or anesthesia, although these measures have not been shown definitively to reduce regurgitation. Steps that can be taken in attempts to prevent regurgitation include adding metoclopramide to the premedication, administration of Cerenia at least one hour prior to premedication, and the addition of other centrally acting antiemetics such as dolasetron or ondansetron to the protocol. Although these additions have not been shown to reliably reduce regurgitation, they do reduce nausea and vomiting associated with drugs and anesthesia and this ultimately will lead to a better anesthetic experience for both the dog and their owner.

Designing the perfect anesthetic protocol for brachycephalic dogs can be difficult, to say the least. The proper sedation should allow the patient to breathe slowly and calmly without causing excessive respiratory depression. Many brachycephalic dogs respond well to sedatives such as acepromazine or dexmedetomidine in conjunction with an opioid, but the sedative dose should be half of what is used in the non-brachycephalic dog. Full mu opioids can be used but may cause excessive respiratory depression, so a reversal agent should be available. Butorphanol, a kappa agonist and mu antagonist opioid, can be used and provides reliable sedation but short-acting analgesia. Buprenorphine, a partial mu agonist, provides moderate analgesia and minimal sedation and can also be used as part of the premedication. Dexmedetomidine, an alpha-2 agonist, may be used in these dogs if no cardiovascular disease exists, but due to the presence of high vagal tone the dose used should

be reduced. Dexmedetomidine, when used in lower doses, provides good sedation, is fully reversible, and provides analgesia.<sup>6</sup> Acepromazine, a phenothiazide sedative, is commonly used in many brachycephalic breeds due to its anxiolytic properties. Acepromazine provides reliable sedation in these dogs but is not reversible, so it should be used in low doses. There are several websites stating that acepromazine cannot be used in French Bulldogs, but these websites are not backed by any reliable scientific evidence or studies and should be followed with caution. In fact, French Bulldogs are often highly stressed and excited when presenting for anesthesia and can actually benefit from the addition of acepromazine to the protocol. The goal of premedication in brachycephalic dogs is to provide enough sedation and anxiolysis to allow intravenous catheter placement with minimal stress.

The induction agent chosen should allow for smooth, rapid induction and intubation, thereby protecting the airway and providing a source of oxygen as quickly as possible. The induction agent should also allow for rapid loss of consciousness and rapid return of consciousness. There are several induction agents that can be chosen including propofol or alfaxalone. Preoxygenation is always recommended before induction of dogs with BAS.<sup>3,4,5</sup> Intubation should be performed as rapidly as possible and mask inductions should be avoided.<sup>4,5</sup> Due to their everted laryngeal sacculles and small tracheal size, most BAS breeds require a smaller-size endotracheal tube than would be expected for a patient of the same weight, so it is important to have a large variety of sizes of endotracheal tubes available during induction.<sup>7</sup> Due to the common occurrence of obesity in brachycephalic breeds, controlled or mechanical ventilation is often necessary. It is not uncommon for regurgitation to occur during the induction period, and it is of good practice to have active suction available for rapid suction of the airway. The intraoperative period is usually similar to that of other breeds, although if surgery is to be performed on the airway itself, it may be indicated to administer an injectable steroid such as dexamethasone to reduce postoperative swelling.

Most problems occur during the induction and recovery periods, and this is a particular problem in the recovery period when patients are poorly monitored. It is important to postpone extubation until the patient is bright, alert, swallowing, and even chewing on the endotracheal tube.<sup>5</sup> If extubation is attempted while the patient is sedate and groggy from anesthesia, there is an increased risk of upper airway obstruction. If an upper airway obstruction does occur, the

patient may need to be reintubated, so extra laryngoscopes, induction agents, and tubes should be available. Once extubation occurs, the patient should be observed for breath sounds and signs of obstruction such as inflation of the abdomen with collapse of the thorax on inspiration and lack of breath sounds. The patient should be placed in sternal recumbency during recovery and pulse oximetry should be monitored as long as possible. The airway may also be opened by extending the head, opening the mouth, and pulling out the tongue of the patient. It is often enough just to prop up the head of the patient, maintaining a patent airway while they are still groggy. If reversible sedatives were used, then the antagonist can be given to try and lessen the sedation levels. Once the patient is taking good breaths and awake, they should be monitored closely for the next few hours or transferred to the intensive care unit. Brachycephalic patients should never be left alone in the recovery period. The key to a successful anesthetic recovery is a calm, comfortable patient and a calm, prepared anesthetist. Although sedation and anesthesia of BAS patients can be difficult and stressful, with proper precautionary steps and drug choices it can be done safely and successfully.

For more information, please contact Angell's Anesthesiology Service at 617-541-5048 or [anesthesia@angell.org](mailto:anesthesia@angell.org).

## REFERENCES

- 1 Brodbelt D. Perioperative mortality in small animal anaesthesia. *The Veterinary Journal*. Vol. 182. Nov. 2009; (2):152-161.
- 2 Bednarski RM. Dogs and cats. In Tranquilli WJ, Thurmon JC, Grimm KA (eds.), *Lumb and Jones' Veterinary Anesthesia and Analgesia*, ed. 4. Ames, IA: Blackwell Publishing, 2007: 705-706.
- 3 Anaesthesia of the dog. In Hall LW, Clarke KW, Trim CM (eds.), *Veterinary Anesthesia*, ed. 10. London: WB Saunders, 2001: 393-394.
- 4 Cuvellier S, Ronenay Y. Canine breed-specific problems. In Greene SA (ed.), *Veterinary Anesthesia and Pain Management Secrets*. Philadelphia: Hanley & Belfus, 2002: 233-237.
- 5 The anesthetic period: Predictable problems. Modifications for breeds. In Sawyer DC: *The Practice of Small Animal Anesthesia*. Philadelphia: WB Saunders, 1982: 186-187.
- 6 Murrelet JC, Hellebrekers LJ. Medetomidine and dexmedetomidine: a review of cardiovascular effects and antinociceptive properties in the dog. *Veterinary Anaesthesia and Analgesia*. Vol. 32. 2005; (3):117-127.
- 7 Anesthetic Management of Brachycephalic Breeds. In Smith LJ: *Questions and Answers in Small Animal Anesthesia*. Iowa: Wiley Blackwell, 2016: 323-326.

## BEHAVIOR

*Continued from page 1*

matched with others of a similar size and play style, e.g., the Jack Russell Terrier plays with the big puppies, not the Maltese. In the right class, fearful puppies should be allowed to take breaks as often as needed, and should never be forced to interact when they are afraid. The ideal class has an adult dog who can “correct” over-zealous puppies who don’t know how to take turns. One bark from an adult dog can put a puppy on the right track in a way no human interaction can. No one should ever spray, scruff, or otherwise frighten any puppy in class.

**Obedience classes:** If the behavior problems involve typical “obedience”-type behaviors, such as pulling on the leash, jumping on the counter (and on Grandma), destructive behavior (chewing on things), housebreaking, running away instead of coming when called, or barking when the doorbell rings, these issues can usually be handled by your client taking a group class. This will be less expensive for the client than private training. The class will typically feature these basic exercises: sit, stay, come when called, loose-leash walking, down, even “leave it.” Many problem behaviors can be solved by simply teaching these behaviors as replacements for unwanted behavior. No special equipment should be required other than a flat-buckle or martingale collar, or perhaps a head harness for a strong dog. Instructions to clients should include “Brings lots of treats to class.” A clicker might be featured in training, but is not required.

**Dog trainers:** If your clients don’t have the time to attend a series of group classes, and want someone to work with them in their home, a qualified dog trainer can do just that. As in group classes, make sure the trainer does not require any special collars, such as a prong or electronic collar. You can find many trainers at the Association of Professional Dog Trainers ([www.apdt.com](http://www.apdt.com)), and can even search the website by zip code. To pick a trainer from the list, look for language that discusses teaching

replacement behaviors rather than making you “dominant” over your dog. Dominance is an oft-misused term that indicates the trainer may be relying on outdated methodology. Another sign of this is reference to making you a “pack leader.” Some wolf species have good pack leaders; dogs are terrible at forming pack hierarchies, and people aren’t wolves or dogs... so leave the pack behind when looking for a trainer. Some trainers offer “board and train,” in which they keep your dog for a few weeks and train them on-site. If a board and train service does not feature rewards-based training only, skip it.

**Behaviorist:** Some behavior problems need specialized training and experience. A behaviorist is someone who has a graduate degree in behavior, animal behavior, or who is a vet who has been mentored by a veterinary behaviorist. Ideally, a behaviorist should be board-certified. Board certifications mean the behaviorist has met stringent requirements put forth by an accrediting body, such as the American College of Veterinary Behaviorists certifications, DACVB (see [dacvb.org/](http://dacvb.org/)), and the Animal Behavior Society’s CAAB/ACAAB ([animalbehaviorsociety.org/web/applied-behavior-caab-directory.php](http://animalbehaviorsociety.org/web/applied-behavior-caab-directory.php)). The problems that should be handled by a qualified behaviorist include:

- **Separation anxiety:** True separation anxiety is characterized by prolonged vocalization, attempts to escape, urination/defecation, and/or destructive behavior when a dog is left home alone.
- **Aggression of any kind:** This includes dogs snapping because they are fearful, guarding food, places, and toys, biting people or other dogs, or aggressing at the front door or fence line.
- **Extreme fear:** This is endemic now among many dogs being imported from Southern states. These dogs are afraid to leave the house and walk around their neighborhoods.

- **Reactivity:** Dogs may not be aggressive, but may lunge and bark at people, other dogs, or things in the environment.

If you are certain there is an underlying medical component affecting the behavior, or that medication will be required which you do not feel comfortable prescribing, refer to a veterinary behaviorist. It is important to recognize there may be no “cure” for a serious problem behavior. Think of those humans you know who stop drinking or smoking; they are always at risk of exhibiting that behavior in the future. The same is true for animals. A behavior in their repertoire may be elicited in the future, despite all the best training efforts. An ethical trainer or behaviorist will recommend alternative behaviors and careful management of the environment to reduce instances of unwanted behavior. Training methods that rely on frightening an animal can have unwanted side effects of increased aggression, and can physically injure an animal. Therefore, stick to trainers and behaviorists who do not use prong or shock collars.

**Cats:** Cats have behavioral problems, too, and are best referred to a behaviorist. Like dogs, they should be socialized as kittens. We just started a kitten socialization class at the MSPCA-Angell, and hopefully others will follow our lead. Visit [angell.org/dogtraining](http://angell.org/dogtraining) for information on kitten and dog classes. Behavior problems such as litter box issues, aggression, and inter-cat aggression are some of the common issues seen.

---

Finally, if at any time you are flummoxed and cannot decide where or how to refer, do not hesitate to email our Behavior Department at [behavior@angell.org](mailto:behavior@angell.org) or telephone us at 617-989-1520.

---





## Congenital Heart Disease III: Patent Ductus Arteriosus in the Canine and Feline Patient

Nancy Laste, DVM, DACVIM (Cardiology)

[angell.org/cardiology](http://angell.org/cardiology)

[cardiology@angell.org](mailto:cardiology@angell.org)

617-541-5038

**T**he ductus arteriosus is a normal fetal blood vessel running between the aorta and the main pulmonary artery. Oxygenated blood flows through the pulmonary artery (high pulmonary vasculature resistance in the fetus) and is directed through the ductus arteriosus into the ascending aorta and out to the body (bypassing the lungs, which are nonfunctional in the fetus). “Right to left” flow is the normal flow pattern in the fetus. At birth, when the neonate takes their first breath and expands the lungs, the tissue of the ductus arteriosus should respond to the increase in the oxygen tension with a vasoconstrictive response, resulting in the closure of the ductus arteriosus in the minutes to hours after birth. If the ductus arteriosus fails to close (remains “patent”) then a patent ductus arteriosus (PDA) is present with blood now flowing from the high pressure arterial side to the pulmonary artery: “left to right” flow. The continuous flow of blood through the ductus arteriosus through all phases of the cardiac cycle gives the PDA its typical

“machinery,” a continuous heart murmur that is best auscultated cranially and high on the left hemithorax (in the left axillary region). A palpable thrill is often appreciated. The hemodynamic consequences of the PDA depend on the overall size of the PDA and how much blood is being shunted left to right through the PDA (shunt fraction, Qp/Qs). A PDA is the most common cause of left-sided congestive heart failure in a neonate. Pets with a PDA generally have strong, hyperkinetic femoral pulses. The majority of patients with an uncorrected PDA will develop congestive heart failure (pulmonary edema) within the first few years of life. Occasionally, a PDA is diagnosed in a much older patient. In these cases, the shunt is usually relatively small and the condition may be incidentally diagnosed when the patient develops another cardiac condition, most typically chronic degenerative valvular disease.

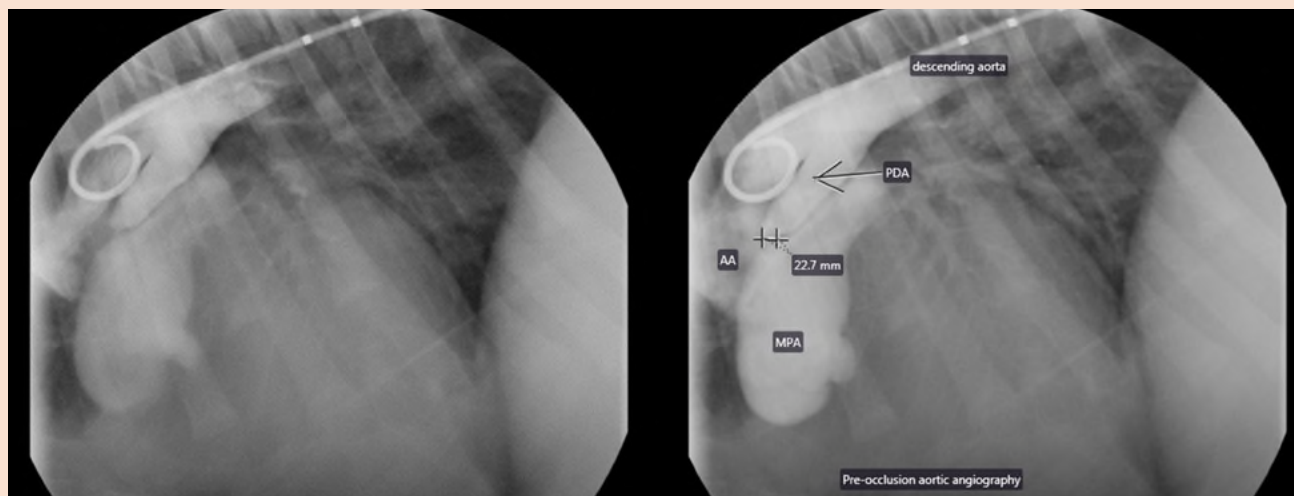
PDA is one of the most common causes of congenital heart disease in the dog (ranking in

the top three causes, alongside pulmonic or subaortic stenosis). In feline patients, PDA is approximated as the sixth most common congenital heart disease.

A small subset of patients may have (or develop) a “reverse PDA,” which is the term for a right to left shunting PDA that develops in response to severe pulmonary hypertension. It is generally thought that some patients with PDA are genetically predisposed to develop significant PH related to the PDA flow. Corgi dogs are the most commonly described breed with right to left PDA, suggesting a genetic predisposition in this breed. Reverse PDA is one type of Eisenmenger syndrome, in which blood flows right to left secondary to the development of pulmonary hypertension related to a cardiac shunt. Patients with reverse PDA (who do not have a history of a left to right PDA) can be difficult to diagnose without maintaining an index of suspicion for a shunt. These patients most typically present for syncope, exercise

FIGURE 1

Arteriography: Patient in right lateral recumbency. Pigtail measuring catheter in place in the ascending aorta, contrast noted in the ascending aorta (AA), PDA, dilated main pulmonary artery (MPA) and descending aorta. The minimal ductal diameter has been measured on the (labeled) image to the right at approximately 2.3 mm.



## CARDIOLOGY

intolerance and/or high leg weakness. On physical examination there is either no cardiac murmur or only a mild cardiac murmur or split-second heart sound (typical with PH). The cranial mucous membranes (oral) are pink while the caudal (vulvar, penile) mucus membranes are cyanotic (although this can be difficult to appreciate). Echocardiography will reveal changes consistent with significant pulmonary hypertension: right ventricular hypertrophy, pulmonary artery enlargement and often a small left ventricular chamber. Definitive diagnosis can be made with an echocardiographic contrast study (bubble study). Agitated saline is administered through a cephalic catheter while visualizing the four chambers of the heart on echocardiography. The microbubbles in the saline will opacify the heart, but no bubbles will be seen crossing at the atrial or ventricular levels. If the study is negative at the level of the heart, an additional injection is given while visualizing the abdominal aorta (usually imaged adjacent to the kidneys). If a right to left shunting PDA is present, microbubbles will be seen in the aorta. This bubble study result: negative at the cardiac level and positive at the abdominal level is diagnostic for a right to left PDA. Unfortunately, other than managing the pulmonary hypertension (with Viagra®) and managing any associated polycythemia (with phlebotomy and/or hydroxyurea), there is no surgical or interventional procedure that will help a patient with reverse PDA. Luckily, most PDA cases will be identified and corrected long before they develop a reverse shunt.

FIGURE 2

➤ ACDO in place at the pulmonic ostium of the ductus arteriosus.

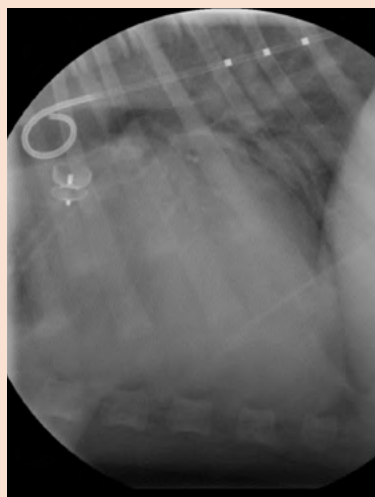
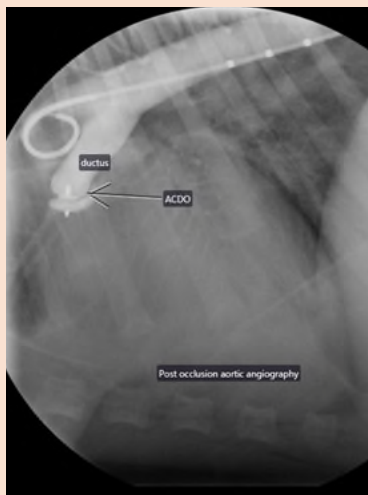


FIGURE 3

➤ Post-ACDO placement angiography. Contrast fills the PDA but no longer crosses the ductus into the pulmonary artery.



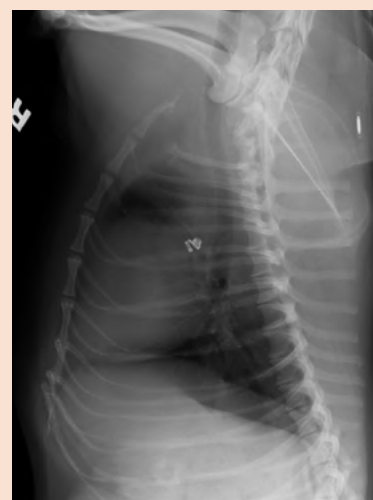While you can be fairly confident of your diagnosis of a PDA on physical examination, it is important to refer these patients to a cardiologist to further delineate the morphology and size of the PDA to determine the possible treatment plans. Dogs who are at least 4 kg and have a ductal morphology that is tapering and with an appropriate minimal ductal diameter will be candidates for ACDO closure in the cardiac catheterization lab. The ACDO sizes run from 3-14 mm with appropriate sizing ratios of 1.5 -2.5 times the minimum ductal diameter as measured on angiography (and estimated on echocardiography). This allows for closure of minimal ductal diameters of 1.5 to 9.0 mm. It is also important that the ductus have a tapering shape (not a straight tube) so as to retain the device. With smaller patients it is important to consider the relative size of the ductus related to the size of the dog (and the dog's femoral arteries), for in small dogs with a relatively large ductal diameter, the femoral arterial size may be the limiting factor. Dogs with a small ductal diameter (under 3.0 mm) may also have the PDA closed using embolization coils. These tend to remain in place and work well for successful embolization in small ducts and require a much smaller device for coil placement. Embolization coils are more likely to embolize through the PDA into the pulmonary arteries. Luckily, coils embolized to the pulmonary arteries seem to be reasonably well tolerated, as they can be very difficult to retrieve. ACDO devices are much less likely to embolize, provided they have been sized and placed appropriately. While the ACDO devices (Infinity Medical) are not inexpensive (\$875

with placement sheaths running in the \$200 range), the shorter procedural time means less time under anesthesia (less expensive) as well as reduced intensity of postoperative care (with significant decrease in patient mortality) and short hospitalization (patients are discharged the day after the procedure).

PDA closure in the cardiac catheterization lab usually results in a total bill of approximately \$2,800–3,500, while a surgical PDA closure ends up closer to \$4,000–5,000, depending on the intensity of postoperative care. Closure of PDA via thoracotomy is generally reserved for very small patients, patients with a non-tapering ductus, patients with a very large ductus or small patients with a proportionately large ductus arteriosus. Although most of the time surgery goes very well, acute hemorrhage related to a tear in the ductus arteriosus of the junction with the main pulmonary artery may be fatal. Most reports suggest an incidence of 5–10% of fatal hemorrhage with the procedure. Although device closure is less invasive, it is not without potential serious complications such as vascular perforation (with hemorrhage), embolization of the ACDO or coils (which may necessitate subsequent surgical closure in some cases), device dislodgement and fatal arrhythmia.

FIGURE 4

➤ Smaller canine patient with two embolization coils in the ductus arteriosus.



Patients who have the PDA closed without any residual PDA flow are thought to have an excellent prognosis. However, the typical left ventricular remodeling—dilation and sphericity of the LV with some decrease in wall motion—

*Continued on page 6*

## CARDIOLOGY

*Continued from page 7*

tends to persist. When some of these patients develop degenerative valvular disease later in life, they may not tolerate the subsequent volume load and develop CHF at what seems to be an earlier point in the disease process. Patients who had congestive heart failure at the time of surgery can often be weaned off some or all of the medications (diuretics, ACE inhibitors, pimobendan, sometimes digitalis glycosides).

Cats with PDA have been closed both by thoracotomy as well as coil embolization, depending on the size of the cat and the size and morphology of the ductus arteriosus. The ACDO devices require larger femoral artery access than is typically available in the feline patient, and the procedure has not been successfully done to the author's knowledge.

*Note: This is the third article in a series of three Congenital Heart Disease articles. Please visit [angell.org/articles](http://angell.org/articles) and select 'cardiology' from the right navigation to read the preceding articles.*

For more information, please contact Angell's Cardiology Service at **617-541-5038** or **[cardiology@angell.org](mailto:cardiology@angell.org)**.

## REFERENCES

Gordon SG, Saunders AB, et al. Transarterial ductal occlusion using the Amplatz canine duct occluder in 40 dogs. *J Vet Cardiol.* Aug. 2010; 12(2):85-92.

Nguyenba TP, Tobias AH. The Amplatz canine duct occluder: a novel device for patent ductus arteriosus occlusion. *J Vet Cardiol.* Nov. 2007; 9(2):109-17.

Oliviera P, Domenech O, et al. Retrospective review of congenital heart disease in 976 dogs. *J Vet Intern Med.* 2011; 25(3):477-83.

Schrope D. Prevalence of congenital heart disease in 76,301 mixed-breed dogs and 57,025 mixed-breed cats. *J Vet Cardiol.* Sept. 2015; 17(3):192-202.

Singh MK, Kittleson MD, Kass MG, Griffiths LG. Occlusion devices and approaches in canine patent ductus arteriosus: comparison of outcomes. *J Vet Intern Med.* 2012, Jan.-Feb.; 26(1):85-92.

Stauthammer CD, Olson, J, et al. Patent ductus arteriosus occlusion in small dogs utilizing a low profile Amplatz® canine duct occluder prototype. *J Vet Cardiol.* Sept. 2015; 17(3):203-9.

## ➤ HAVE YOU TRIED ANGELL'S REFERRING VETERINARIAN PORTAL?

Angell's Referring Veterinarian Portal is a mobile-friendly online portal for referring veterinarians to gain 24/7 access to their patients' lab results, image studies, SOAPs, referral reports, check in/discharge status, discharge instructions, and more.

To receive a login and password for your clinic, please contact us at **617-522-7282**.







# Acute Vestibular Disease in Old Dogs

Jennifer Michaels, DVM, DACVIM (Neurology)

angell.org/neurology  
neurology@angell.org  
617-541-5140

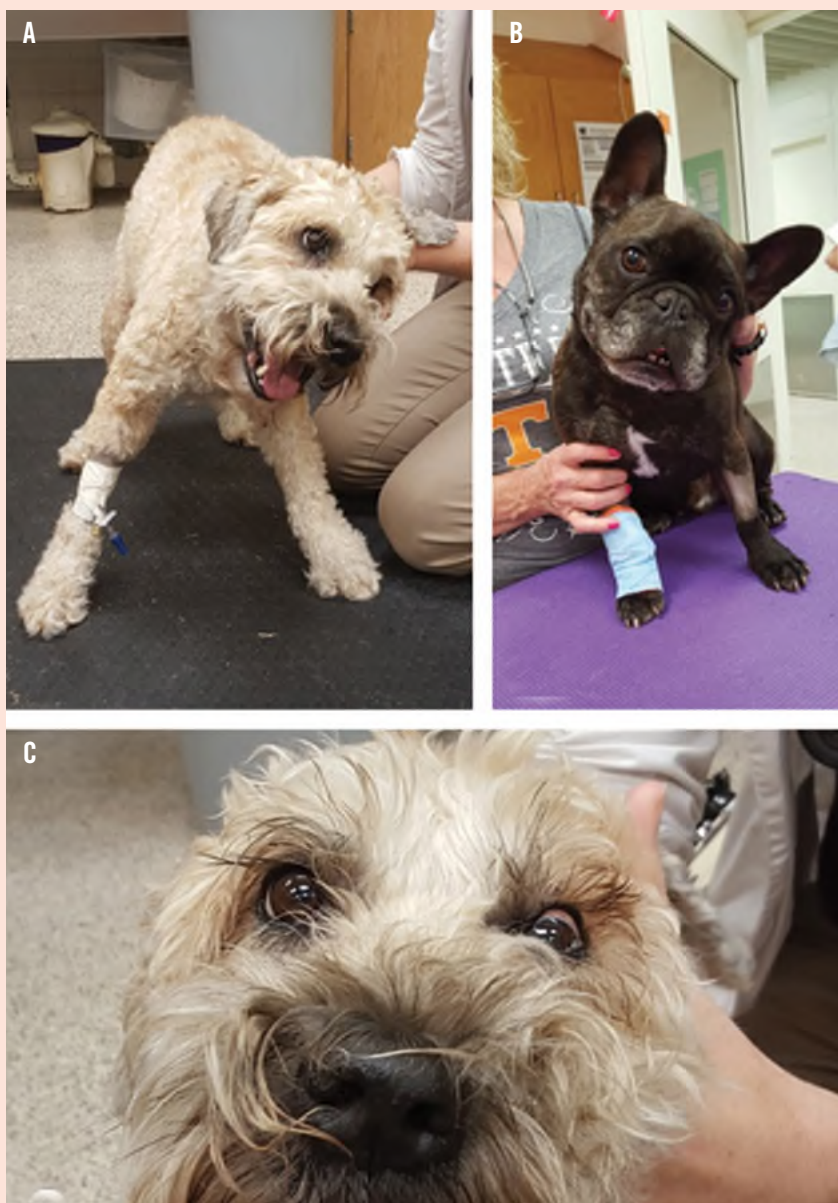**V**estibular disease is a common clinical presentation in dogs with neurologic dysfunction. The vestibular system is the system of balance and equilibrium and comprises the inner ear (sacculle and utricle), vestibular portion of the vestibulocochlear nerve (cranial nerve VIII), the brainstem, and the vestibulocerebellum (flocculonodular lobe, fastigial nucleus, and caudal cerebellar peduncle). Dysfunction in any of these regions will result in similar vestibular symptoms, including a head tilt, leaning or falling to one side, tight circling, pathologic nystagmus, and/or positional ventrolateral strabismus (see Figure 1). Typically, these clinical signs all occur on the same side as the lesion, with the exception of the fast phase of the nystagmus, which occurs away from the lesion. However, lesions of the vestibulocerebellum will cause vestibular symptoms on the opposite side of the lesion, hence the term paradoxical vestibular disease.

There are many causes of acute onset vestibular signs in older dogs. The first step in determining probable differentials is to determine whether the neuroanatomic localization is central or peripheral vestibular disease. What aids us in determining a specific neurolocalization with vestibular disease is not necessarily the vestibular symptoms (which can all look very similar no matter the specific localization), but rather the additional (i.e., non-vestibular) neurologic signs that can be caused by lesions in a given area. For example, with a lesion in the brainstem, you can expect to see not only vestibular signs, but also ipsilateral paresis, ipsilateral proprioceptive or postural reaction deficits, mentation change, and/or other ipsilateral cranial nerve deficits. With a lesion in the vestibulocerebellum, one might expect to see other cerebellar symptoms such as proprioceptive or postural reaction deficits, wide-based stance, truncal sway, hypermetria, dysmetria, or an intention tremor. Lastly, with a peripheral lesion, the only additional signs that may be seen are ipsilateral Horner's syndrome and/or ipsilateral facial nerve paralysis. Correctly localizing a vestibular lesion to the central or peripheral

*Continued on page 8*

FIGURE 1

Common neurologic examination findings in dogs with vestibular disease. A) leaning to the left and head tilt to the left. B) head tilt to the left. C) positional ventral strabismus OS



## NEUROLOGY

Continued from page 7

Table 1: Summary of the common causes of acute onset vestibular disease in geriatric dogs, expected neuroanatomic localization, and expected development of clinical signs

DISEASE	CENTRAL VS. PERIPHERAL	CHANGE OVER TIME
Idiopathic Vestibular Disease	Peripheral	Improvement starts after 2-3 days and continues over 1-2+ weeks
Otitis Media/Interna	Peripheral	Static or progressive
Ischemic Stroke	Central	Improvement at a variable rate from regression to normalcy within a few hours to improvement over several days or weeks
Neoplasia	Central	Static or progressive

vestibular system is critical in establishing appropriate differential diagnoses and thus an appropriate course of action. Common causes of acute onset vestibular signs in old dogs include idiopathic vestibular disease, otitis media/interna, ischemic stroke, and neoplasia. Other important but less common causes may include hypothyroidism, toxins/drugs (e.g., metronidazole), or meningoencephalitis. Important factors to consider when developing a differential list include the signalment of the dog; the rapidity of onset of clinical signs; whether the dog is exhibiting central or peripheral vestibular signs; whether the clinical signs have improved, remained static or gotten worse over time; and if the signs have improved, how rapidly have they improved (see Table 1).

In particular, it can be challenging to distinguish between idiopathic vestibular disease and ischemic stroke, which both occur in geriatric dogs, have a per-acute onset, and get better over time without targeted therapy. Doing a thorough neurologic examination is critical in determining a specific neuroanatomic localization (i.e., central versus peripheral vestibular), which is the major factor in clinically distinguishing these two entities. Another factor to consider is recurrence of clinical signs. While idiopathic vestibular disease can recur in dogs after initial improvement, it is less common than with strokes and the interval between episodes is typically longer with idiopathic vestibular disease (months or more) versus strokes (days to weeks or more).

Some might ask, if dogs get better after a stroke without treatment (just as they do with idiopathic vestibular disease), why is there a need to distinguish between these two diseases? About 50% of dogs that suffer from strokes have an identifiable underlying cause that predisposes them to having continued strokes, and thus puts them at risk for continued morbidity or even mortality. Possible underlying causes of strokes in dogs include:

- Hypertension
- Chronic kidney disease
- Cushing's disease
- Hypothyroidism
- Protein losing disease (enteropathy, nephropathy)
- Hypercoagulability
- Hyperviscosity (e.g., hyperglobulinemia secondary to multiple myeloma, polycythemia vera)
- Tumor emboli

If a dog suffers a stroke, it is important to identify and treat any underlying cause(s) to help reduce the risk of further strokes and other morbidity. Diagnostic evaluation of a possible or confirmed stroke case should include:

- Fundic exam
- CBC
- Chemistry panel
- Urinalysis
- Urine protein : creatinine ratio
- Blood pressure
- T4/TSH
- +/- ACTH stimulation or low-dose dexamethasone suppression test
- +/- abdominal and thoracic imaging
- +/- coagulation panel
- +/- hypercoagulability assessment (i.e., TEG)

In summary, there are many causes of acute onset vestibular disease in geriatric dogs, some of which can be relatively easily managed if correctly identified (e.g., otitis media/interna, idiopathic vestibular disease). However, it can be

very easy to make an incorrect presumptive diagnosis due to similarities in clinical presentation, thus putting the patient at risk for further morbidity or even mortality. History or examination findings that warrant consideration of referral to a specialist for imaging (typically MRI) include progression of clinical signs over time, neurologic examination findings suggestive of central vestibular disease, and/or recurring vestibular episodes.

For more information, please contact Angell's Neurology Service at 617-541-5140 or [neurology@angell.org](mailto:neurology@angell.org).

## REFERENCES

- Garosi LS. Cerebrovascular disease in dogs and cats. *Vet Clin North Am Sm Anim Pract*. 2010; 40(1):65-79.
- Garosi LS, Lowrie ML, Swinbourne NF. Neurological manifestations of ear disease in dogs and cats. *Vet Clin North Am Sm Anim Pract*. 2012; 42:6. 1142-60.
- Lowrie ML. Vestibular disease: anatomy, physiology, and clinical signs. *Compend Contin Educ Vet*. 2012; 34(7): E1.
- Lowrie ML. Vestibular disease: diseases causing vestibular signs. *Compend Contin Educ Vet*. 2012; 34(7): E2.
- Sanders, SG. Disorders of hearing and balance: the vestibulocochlear nerve (cn viii) and associated structures. Dewey CW, Da Costa RC. *A Practical Guide to Canine and Feline Neurology*. Ames, IA: Wiley Blackwell, 2016; 277-297.
- Sanders, SG. Cerebellar diseases and tremor syndromes. Dewey CW, Da Costa RC. *A Practical Guide to Canine and Feline Neurology*. Ames, IA: Wiley Blackwell, 2016; 299-307.





## Necrotizing Soft Tissue Infections (NSTI)

Roxanna Khorzad, DVM

angell.org/emergency  
emergency@angell.org  
617-522-7282

**N**ecrotizing soft tissue infections (NSTI) are a specific subgroup of soft tissue infections caused by ischemia, necrosis, and vascular occlusion that involve the skin, subcutaneous tissue, muscle, and fascia. The classification and terms for necrotizing soft tissue infections in humans have varied and are often confusing and inconsistent. Nomenclature that has been used includes necrotizing fasciitis, synergistic necrotizing cellulitis, streptococcal myonecrosis, gas gangrene, Fournier's gangrene, and Ludwig's angina.<sup>1</sup>

NSTI is a rapidly progressive disease that can lead to necrosis, hypotension, multi-organ dysfunction syndrome, and death.<sup>2</sup> These infections are often caused by bacteria or fungal organisms that rapidly spread along tissue planes. NSTI can be misdiagnosed frequently because of the challenge of differentiating between cellulitis and other superficial skin infections. Rapid identification, antimicrobial therapy, and aggressive surgical early debridement are the key to positive outcomes and improved morbidity and mortality. A few clinical signs associated with necrotizing soft tissue infections are soft tissue swelling, edema, and fever. A distinguishing feature between NSTI and soft tissue infections such as cellulitis is the presence of extreme pain associated with NSTI.

Most cases of NSTI begin with some trauma to the skin surface leading to bacterial spread through the tissue along the deep fascia. Infection spreads to venous and lymphatic channels, leading to edema, thrombosis of blood vessels, and ischemia. Animals will often times be hemodynamically unstable, tachycardic with a fever, and display signs of sepsis, pain, and swelling on the skin. Crepitus can be present but often in the late stage of the disease and occurs in only about 18% of cases of NSTI.<sup>1</sup> The patient can have an exaggerated degree of pain disproportionate to the degree of inflammation/injury.

Radiographs may be useful to show subcutaneous gas, but this is neither specific nor sensitive for

a diagnosis of NSTI. The diagnosis of NSTI is most often clinically based. Treatment is centered on surgical debridement and intravenous antibiotic therapy with treatment of sepsis. In humans with NSTI, mortality is near 100% without surgical exploration.<sup>1</sup>

Surgical exploration and debridement are key elements to positive outcomes with NSTI. The decision when and whether to surgically intervene is often a difficult choice, particularly when only mild external clinical signs are visible. Additional information from bloodwork such as leukocytosis with neutrophilia, acidosis, prolonged coagulation times, azotemia, elevated creatinine kinase and inflammation markers may be helpful in making a decision to pursue surgery.<sup>3</sup>

In human medicine a clinical score system is used to help diagnose NSTI: Laboratory Risk Indicator for Necrotizing Fasciitis (LRINEC). A score of 6 and above suggests NSTI. In this scoring system, 4 points are given to elevated serum C-reactive protein, 1-2 points for leukocytosis, 1-2 points for hemoglobinemia, 2 points for hyponatremia, 2 points for elevated creatinine, and 1 point for hypoglycemia.<sup>4</sup>

The maximum score is 13; a score >6 is suspicious for necrotizing fasciitis and >8 is strongly predictive.<sup>4</sup>

In severe cases where surgical debridement is unsuccessful, amputation may be required. One retrospective paper describes the mortality rate of 47 dogs with severe soft tissue infections to be 53%.<sup>3</sup>

There are four main microbiological categories of necrotizing soft tissue infections. Type I NSTI is polymicrobial associated with mixed anaerobes and aerobes; there are usually four or more organisms. Type II NSTI infections are monomicrobial and commonly  $\beta$ -hemolytic *Streptococcus* species. Type III NSTI infections are associated with gram-negative monomicrobials, often marine-related organisms or *Clostridia* infections. Type IV NSTI infections are fungal with *Candida* being the most common organism.<sup>5</sup>

Risk factors in humans developing NSTI include immunosuppressed states, trauma, alcohol or IV drug use, peripheral vascular disease, and obesity.<sup>6</sup> In humans, polymicrobial infections are more common and typically occur in the perineum and trunk. Monomicrobial infections tend to occur in the limbs and tend to affect more healthy individuals with no comorbidities.<sup>1</sup>

In a retrospective study of 47 cases of severe soft tissue infections in dogs, 34% of cases had pre-existing conditions such as immunomodulating diseases, blunt trauma, injections, and clean surgical procedures that could have contributed to development of severe soft tissue infections. The overall survival rate was 46.8%, with survivors having a higher body weight and higher respiratory rate on presentation. Non-survivors had a lower white blood cell count and higher lactate, BUN, aspartate aminotransferase, and bilirubin concentration. Histologically, survivors had a higher degree of necrosis compared with non-survivors.<sup>3</sup>

In human studies, WBC band formation greater than 10% as well as elevated WBC on admission were positive predictors of mortality.<sup>7</sup> There have not been enough cases in veterinary medicine to assess predictors of mortality and risk factors. Often times an initiating cause such as a penetrating wound, insect bite, etc., is not found. In veterinary medicine, necrotizing soft tissue infections are usually type II with *Streptococcus* species being the most common. The bacterium most commonly isolated in veterinary medicine is group G *Streptococcus* sp. in contrast to humans, which is group A *Streptococcus* sp.<sup>8</sup>

Although *Streptococcus* species infection is the most common, a few years ago Angell Animal Medical Center treated a four-month-old male intact Shar-Pei (Figures 1, 2, 3, 4) that presented in septic shock with rapidly progressive draining tract wounds on the ventral thorax extending to his thoracic limbs. A diagnosis of necrotizing severe soft tissue infection was

*Continued on page 10*

## EMERGENCY

*Continued from page 9*

FIGURE 1

➤ Day 1 presentation to Angell Animal Medical Center

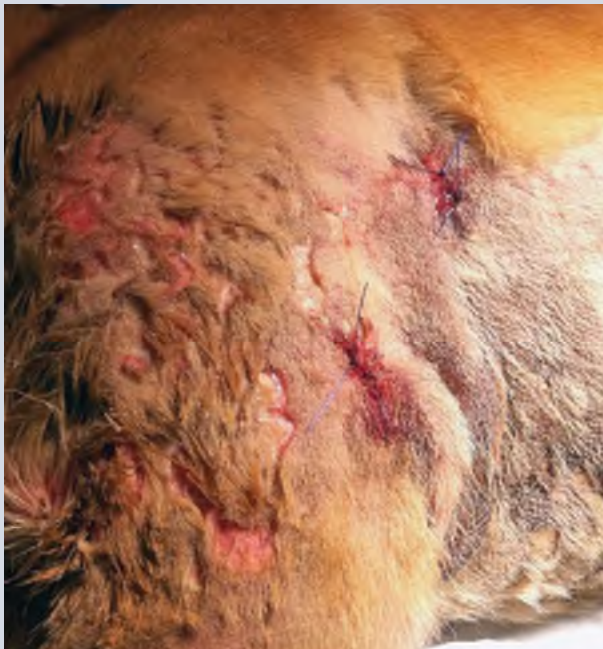

FIGURE 2

➤ Prior to first surgical debridement: four days after admission

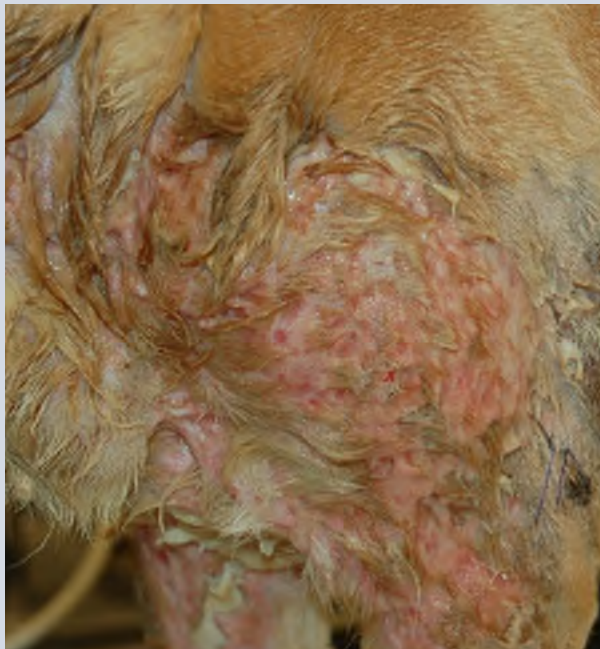

FIGURE 3

➤ Prior to first surgical debridement: six days after admission

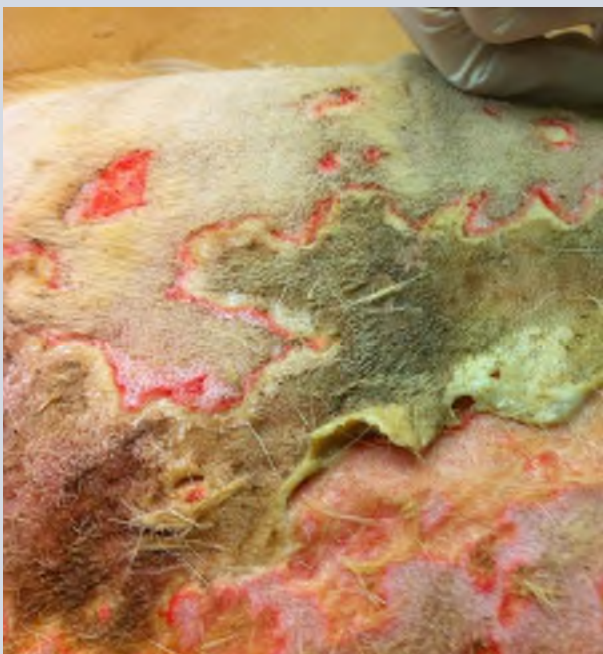
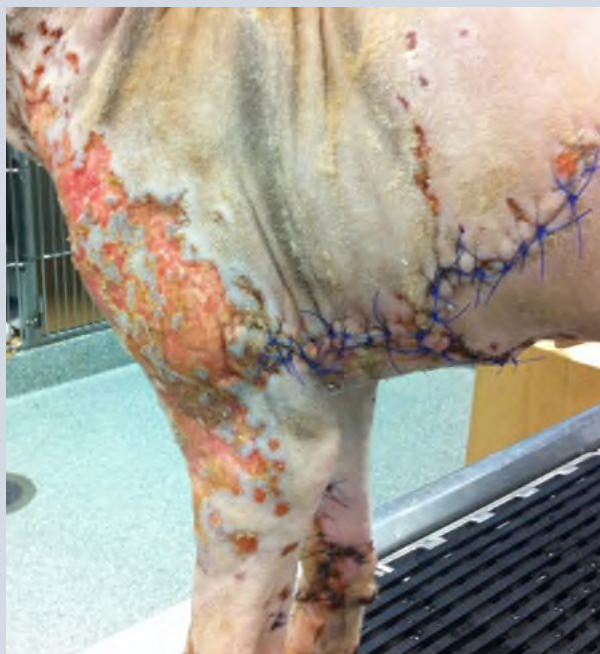

FIGURE 4

➤ Post-surgical debridement and exploration: day 14 hospitalization



## EMERGENCY

confirmed via histopathology and a positive culture of *Pseudomonas aeruginosa*, resistant to most conventional antimicrobials. He was therefore treated with imipenem, a carbapenem. The patient developed a large jejunal intussusception during treatment and required a resection and anastomosis. After a series of wound debridement surgeries and long-term antibiotic therapy, the patient ultimately recovered fully.

NSTI is considered a relatively rare condition in veterinary medicine that can be difficult to distinguish from cellulitis or other skin infections, and when left untreated can be fatal. It is very important for clinicians to have this as a differential when dealing with skin infections that are severe or when patients are in far more pain than their clinical appearance would suggest. An early diagnosis gives these patients the best chance of survival.

For more information about necrotizing soft tissue infections, please contact **Dr. Khorzad** at Angell's Emergency Critical Care Service at **617-522-7282** or **emergency@angell.org**.

## REFERENCES

- 1 Puvanendran R, et al. Necrotizing fasciitis. *Canadian Family Physician*. Vol. 55: Oct. 2009, 981-987.
- 2 Naidoo SL, Campbell DL, Miller LM, et al. Necrotizing fasciitis: A review. *J Am Anim Hosp Assoc*. 2005; 41:104-109.
- 3 Buriko Y, et al. Severe soft tissue infections in dogs: 47 cases (1996-2006). *J Vet Emerg Crit Care*. 2008; 18(6):608-618.
- 4 Su, Yi-Chun, et al. Laboratory risk indicator for necrotizing fasciitis score and the outcomes. *J. Surg*. 2008; 78:968-972.
- 5 Silverstein D, and Hopper K. *Small Animal Critical Care Medicine*, 2nd edition. Chapter 101, Necrotizing soft tissue infections. Saunders, 2015: 530-533.
- 6 Salcido R. Necrotizing fasciitis: reviewing the causes and treatment strategies. *Adv Skin Wound Care*. 2007; 20:228-293.
- 7 Hsiao CT, Weng HH, Yuan YD, et al. Predictors of mortality in patients with necrotizing fasciitis. *Am J Vet Med*. 2008; 26:170-175.
- 8 Lin JN, Chang LL, Lai CH, et al. Clinical and molecular characteristics of invasive and noninvasive skin and soft tissue infections caused by group A *Streptococcus*. *J Clin Microbiol*. 2011 Oct.; 49(10):3632-7.

Table 1: The laboratory risk indicator for necrotizing fasciitis

C-reactive protein, mg/L	<150	0
	>150	4
Total white cell count, per mm <sup>3</sup>	<15	0
	15-25	11
	>25	2
Sodium, mmol/L	>135	0
	<135	2
Creatinine, umol/L	<141	0
	>141	2
Glucose, mmol/L	< 10	0
	>10	1

Table 2: Categories of necrotizing soft tissue infections

TYPE	ORGANISMS INVOLVED
I	<b>Polymicrobial:</b> mixed anaerobes and aerobes
II	<b>Monomicrobial:</b> commonly $\beta$ -hemolytic <i>Streptococcus</i> species
III	<b>Monomicrobial:</b> gram negative, often times <i>Clostridia</i> infections
IV	<b>Fungal:</b> <i>Candida</i> infections

The patient 2-3 weeks following hospitalization





# ➤ ANGELL AT NASHOBA: LOW COST CARE FOR FINANCIALLY QUALIFIED CLIENTS

In 2016, Angell Animal Medical Center and Nashoba Valley Technical High School partnered to create **Angell at Nashoba**, a veterinary clinic for low income pet owners that also serves as a rigorous academic and experimental training program for students enrolled at Nashoba Valley Technical High School.

Nashoba just celebrated its one year anniversary! They've seen close to 1,000 patients, given over 300 rabies vaccinations, and spayed or neutered almost 60 pets. The clinic provides discounted:

-  Spay/neuter services
-  Vaccinations
-  Basic veterinary care

Open weekdays from 7:45am-4:00pm throughout the year, the clinic does not provide overnight care, specialty service care, nor 24/7 emergency service as Angell's Boston and Waltham facilities do, but will refer cases as appropriate to surrounding specialty veterinary referral hospitals.

To reach the clinic, please call **978-577-5992**. The clinic is located at: 100 Littleton Road, Westford, Massachusetts. For more information, visit [angell.org/nashoba](http://angell.org/nashoba).

➤ Medical Director Dr. Laurence Sawyer provides routine care to two Ragdoll cats



---


## Financial Qualifications for Clients

*To qualify for Angell at Nashoba services, clients must present a photo ID and one of the following:*

 Women, Infants, and Children (WIC) program card

 Spay and Neuter Assistance Program certificate

 Supplemental Nutrition Assistance Program (SNAP) card (formerly known as Food Stamps/EBT card)

 Letter/lease from the owner's local housing authority showing that the owner is a participant in public housing in the following communities: Lowell, Chelmsford, Littleton, Groton, Shirley, Ayer, Townsend, Pepperell, Westford





The person whose name is on the card or documents must be present (i.e., they can't send a relative or friend). The only exception is a spouse with the same last name and address.



# ➤ ANGELL IS FIRST IN NEW ENGLAND TO UPGRADE TO STEREOTACTIC RADIATION THERAPY

The Oncology service at Angell Animal Medical Center is excited to announce we have upgraded our radiation therapy delivery unit. Our new system is a Varian TrueBeam, which allows Angell Animal Medical Center to continue delivering 3-dimensional conformal and intensity modulated radiation therapy (IMRT). In addition, **Angell is the first site in New England to offer stereotactic radiation therapy for our patients.**

Stereotactic radiation therapy is a newer form of advanced radiation technology that uses highly conformal and focused irradiation beams directed precisely at a tumor volume. This technology has several proposed advantages over traditional fractionated radiation therapy including:

-  Reduced side effects
-  Fewer anesthetic events
-  Sparing normal tissue is accomplished by avoidance of normal tissue structures (vs. delivering smaller doses of fractions over a course of therapy that uses traditionally fractionated radiation)
-  Fewer doses (e.g., traditional delivery schemes for heart base tumors involve 18-20 doses vs. 3-5 doses of stereotactic radiation)

**Uses:** In veterinary medicine there are multiple publications advocating the use of stereotactic radiation therapy in conditions such as brain tumors, osteosarcoma, nasal tumors, heart base tumors, injection site sarcomas and oral squamous cell carcinoma.

Stereotactic radiation therapy can also be used in a palliative setting to maintain tumor control and quality of life.

For more information on Angell's Oncology services and team, please visit [angell.org/oncology](http://angell.org/oncology). Profiles of Lyndsay Kubicek, DVM, DACVR (Radiation Oncology), Mairin Miller, DVM, and J. Lee Talbott, DVM, DACVIM (Medical Oncology) are available at [angell.org/vets](http://angell.org/vets). The Oncology service can be reached at 617-541-5136 or [oncology@angell.org](mailto:oncology@angell.org).

➤ Drs. Lyndsay Kubicek (top), Mairin Miller (middle) and J. Lee Talbot (bottom) of Angell's Oncology service.



## STAFF DOCTORS AND RESIDENTS

We encourage you to contact Angell's specialists with questions.

Main Phone: 617-522-7282 (Boston), 781-902-8400 (Waltham) Veterinary Referrals: 617-522-5011

Angell at Nashoba: 978-577-5992

## CHIEF OF STAFF

**Ann Marie Greenleaf, DVM, DACVECC**  
agreenleaf@angell.org

24-HOUR EMERGENCY & CRITICAL CARE  
MEDICINE, BOSTON

**Kiko Bracker, DVM, DACVECC**  
*Service Co-Director*  
kbracker@angell.org

**Kate Dorsey, DVM**  
kdorsey@angell.org

**Roxanna Khorzad, DVM**  
rkhorzad@angell.org

**William (Glenn) Lane, DVM**  
wlane@angell.org

**Beth Lieblick, DVM**  
blieblick@angell.org

**Ashley Lockwood, DVM**  
alockwood@angell.org

**Hannah Marshall, DVM**  
hmarshall@angell.org

**Susan Magestro, DVM**  
smagestro@angell.org

**Emiliana Meroni, DVM**  
emeroni@angell.org

**Virginia Sinnott, DVM, DACVECC**  
vsinnott@angell.org

**Megan Whelan, DVM, DACVECC, CVA**  
*Service Co-Director*  
mwhelan@angell.org

24-HOUR EMERGENCY & CRITICAL CARE  
MEDICINE, WALTHAM

**Lauren Baker, DVM**  
lbaker@angell.org

**Alyssa Blaustien, VMD**  
ablaustein@angell.org

**Jordana Fetto, DVM**  
jfetto@angell.org

**Emily Finn, DVM**  
efinn@angell.org

**Jessica Hamilton, DVM**  
jhamilton@angell.org

**Amanda Lohin, DVM**  
alohin@angell.org

**Kate Mueller, DVM**  
kmueller@angell.org

**Courtney Peck, DVM**  
cpeck@angell.org

**Susan Smith, DVM**  
ssmith@angell.org

**Catherine Sumner, DVM, DACVECC**  
*Chief Medical Officer*  
csumner@angell.org

**Yao Yao, VMD**  
yyao@angell.org

## ANESTHESIOLOGY

**Stephanie Krein, DVM, DACVAA**  
skrein@angell.org

**Kate Cummings, DVM, DACVAA**  
kcummings@angell.org

## AVIAN &amp; EXOTIC MEDICINE (W/B)

**Brendan Noonan, DVM, DABVP**  
(Avian Practice)  
bnoonan@angell.org

**Elisabeth Simone-Freilicher, DVM, DABVP**  
(Avian Practice)  
esimonefreilicher@angell.org

**Anne Staudenmaier, VMD**  
astaudenmaier@angell.org

## BEHAVIOR (W/B)

**Terri Bright, Ph.D., BCBA-D, CAAB**  
tbright@angell.org

**Ellen Lindell, DVM, DACVB**  
elindell@angell.org

## CARDIOLOGY (W/B)

**Katie Hogan, DVM**  
khogan@angell.org

**Ashley Lange, DVM**  
alange@angell.org

**Nancy Laste, DVM, DACVIM (Cardiology)**  
*Director of Medical Services*  
nlaste@angell.org

**Rebecca Malakoff, DVM, DACVIM**  
(Cardiology)  
(Waltham)  
rmalakoff@angell.org

**Rebecca Quinn, DVM, DACVIM**  
(Cardiology and Internal Medicine)  
rquinn@angell.org

## DENTISTRY

**Erin Abrahams, DVM**  
eabrahams@angell.org

**Jessica Riehl, DVM, DAVDC**  
jriehl@angell.org

## DERMATOLOGY

**Klaus Loft, DVM**  
keloft@angell.org

## DIAGNOSTIC IMAGING\*

**Steven Tsai, DVM, DACVR**  
stsai@angell.org

**Ruth Van Hatten, DVM, DACVR**  
rvanhatten@angell.org

## INTERNAL MEDICINE (W/B)

**Daniela Ackley, DVM, DACVIM**  
(Waltham)  
dackley@angell.org

**Douglas Brum, DVM**  
dbrum@angell.org

**Maureen Carroll, DVM, DACVIM**  
mccarroll@angell.org

**Zach Crouse, DVM**  
zcrouse@angell.org

**Erika de Papp, DVM, DACVIM**  
edepapp@angell.org

**Jean Duddy, DVM**  
jduddy@angell.org

**Kirstin Johnson, DVM, DACVIM**  
kcjohnson@angell.org

**Shawn Kearns, DVM, DACVIM**  
skearns@angell.org

**Evan Mariotti, DVM**  
emariotti@angell.org



## STAFF DOCTORS AND RESIDENTS

**Susan O'Bell, DVM, DACVIM**  
Service Director  
sobell@angell.org

**NEUROLOGY (W/B)**

**Rob Daniel, DVM, DACVIM (Neurology)**  
rdaniel@angell.org

**Michele James, DVM, DACVIM (Neurology)**  
(Boston & Waltham)  
mjames@angell.org

**Jennifer Michaels, DVM, DACVIM (Neurology)**  
(Boston & Waltham)  
jmichaels@angell.org

**NUTRITION**

**Dana Hutchinson, DVM, DACVN**  
dhutchinson@angell.org

**ONCOLOGY**

**Lyndsay Kubicek, DVM, DACVR (Radiation Oncology)**  
lkubicek@angell.org

**Mairin Miller, DVM**  
mmiller@angell.org

**J. Lee Talbott, DVM, DACVIM (Medical Oncology)**  
jtalbott@angell.org

**OPHTHALMOLOGY**

**Daniel Biros, DVM, DACVO**  
dbiros@angell.org

**Martin Coster, DVM, MS, DACVO**  
mcoster@angell.org

**PAIN MEDICINE**

**Lisa Moses, VMD, DACVIM, CVMA**  
lmoses@angell.org

**PATHOLOGY (CLINICAL & ANATOMIC)\***

**Patty Ewing, DVM, MS, DACVP**  
pewing@angell.org

**Pamela Mouser, DVM, MS, DACVP**  
pmouser@angell.org

**SURGERY (W/B)**

**Sue Casale, DVM, DACVS**  
scasale@angell.org

**Michele Kudisch, DVM, DACVS (Waltham)**  
mkudisch@angell.org

**John Litterine-Kaufman, DVM**  
jlitterinekaufman@angell.org

**Michael Pavletic, DVM, DACVS**  
mpavletic@angell.org

**Meghan Sullivan, DVM, DACVS**  
msullivan@angell.org

**Nicholas Trout, MA, VET MB, MRCVS, DACVS, DECVS**  
ntrout@angell.org

**Emily Ulfelder, BVetMed**  
eulfelder@angell.org

**ANGELL AT NASHOBA**

**Laurence Sawyer, DVM**  
lsawyer@angell.org

(W/B) Services also available at our Waltham location

\*Boston-based radiologists and pathologists serve both Boston & Waltham locations








## ↘ COURTESY SHUTTLE TO/FROM BOSTON FOR ANGELL WEST PATIENTS

Our Waltham facility has an oxygen-equipped courtesy shuttle that will transport patients to and from Boston if further specialized care is needed.

Please call 781-902-8400 to book appointments or referrals, or visit [angell.org/waltham](http://angell.org/waltham) for a full list of expanding Waltham services.

\*Boston-based radiologists and pathologists serve both Boston and Waltham locations.

*MSPCA-Angell West hospital services\* currently include...*

-  24/7 EMERGENCY & CRITICAL CARE
-  AVIAN & EXOTIC MEDICINE
-  BEHAVIOR
-  CARDIOLOGY
-  INTERNAL MEDICINE
-  NEUROLOGY
-  SURGERY



Nonprofit Org.  
US Postage  
PAID  
Permit No. 1141  
Boston, MA

We mail one complimentary copy of our newsletter to each of our referring partners. Please circulate this copy within your practice.

Summer 2017 ■ Volume 11:2 ■ [angell.org](http://angell.org) ■ [facebook.com/AngellReferringVeterinarians](https://facebook.com/AngellReferringVeterinarians)

MSPCA-ANGELL

350 South Huntington Avenue  
Boston, MA 02130  
617-522-5011  
[angell.org](http://angell.org)

MSPCA-ANGELL  
WEST

293 Second Avenue  
Waltham, MA 02451  
781-902-8400  
[angell.org/waltham](http://angell.org/waltham)

ANGELL AT  
NASHOBA

100 Littleton Road  
Westford, MA 01886  
978-577-5992  
[angell.org/nashoba](http://angell.org/nashoba)

**Please consider adding Angell's main numbers to your after-hours phone message.**

■ [angell.org/directions](http://angell.org/directions) (free parking) ■ [angell.org/hours](http://angell.org/hours) ■ [angell.org/ce](http://angell.org/ce)

## ➤ ANGELL HAS EARNED FELINE-FRIENDLY GOLD ACCREDITATION AS A FELINE-FRIENDLY PRACTICE

As a part of our commitment to feline comfort and care, Angell has added three feline-friendly exam rooms (two exclusively for cats). To further reduce the stress on feline patients, Angell provides "Kitty Kruisers" at the hospital entrance to enable cats to avoid anxiety-invoking, eye-level proximity with canine patients and to avoid unsettling jostling that can occur when carrying heavy cat carriers by hand. Blankets are available to cover carriers to further enhance security and comfort, as well as a separate feline waiting room and express checkout in a feline-only area during weekdays. These efforts and more have earned Angell Gold Level accreditation in the Cat Friendly Practice Program® of the American Association of Practitioners (AAFP). The AAFP requires rigorous guidelines to be met for accreditation.

➤ Buttercup in her Kitty Kruiser

