angell animal medical center

Partners In Care

Summer 2023 | angell.org | facebook.com/mspcaangell

VETERINARY REFERRAL NEWS FROM ANGELL ANIMAL MEDICAL CENTER

EMERGENCY & CRITICAL CARE

Post-Cardiac Arrest

Alison Allukian, DVM
angell.org/emergency | emergency@angell.org | 617-522-7282

Cats and dogs have only a 6 to 7% rate of survival to discharge following cardio-pulmonary arrest (CPA).[1,2] In CPA, there are two main phases of patient loss. The first phase is during initial CPA, where the patient does not have return of spontaneous circulation (ROSC), in which about 65% of patients will be lost. The second phase of patient loss is after ROSC. Of those patients that have ROSC, about 85% will be euthanized or die before hospital discharge (Figure 1).[1,2] It is during this time that interventional strategies after ROSC has the potential to save more lives. Given the complexity of these cases, post-cardiac arrest patients require intensive monitoring in a 24-hour critical care facility to prevent re-arrest and to manage post-cardiac arrest syndrome.

Post-cardiac arrest syndrome: definition and pathogenesis

Post-cardiac arrest (PCA) syndrome is a complex pathological response that occurs as a sequela to global body ischemia followed by reperfusion. The four main components of PCA syndrome include brain injury, myocardial dysfunction, systemic ischemia/reperfusion injury, and pre-existing co-morbidities.[2,3,4]

(CONTINUED ON PAGE 2)

AVIAN & EXOTIC MEDICINE

Recognizing Signs of Pain in Exotic Animal Species

Anne Staudenmaier, VMD, DABVP (Avian Practice)
angell.org/waltham/avian-and-exotic | avianexotic@angell.org | 617-541-5139

Pain in Exotic Animal Species

Recognition and control of pain in any species is a key component of well-rounded medical care. Untreated pain has been shown in human medicine to slow wound healing and negatively impact mental health. Unfortunately, pain can be hard to appreciate in animals, especially exotic animal species. Most of these animals, including predatory species like ferrets or birds of prey, are prey species themselves and often hide signs of pain extremely well to decrease the risk of attack and death.

Pain is the unpleasant sensory and emotional experience associated with actual or potential tissue damage and requires processing by the central nervous system. When evaluating

(CONTINUED ON PAGE 4)

INSIDE: REFERRAL CONTACT INFO ON A REMOVABLE POSTCARD

CONTINUED FROM PAGE 1

Figure 1

Two phases of patient loss (From Silverstein: Small Animal Critical Care).

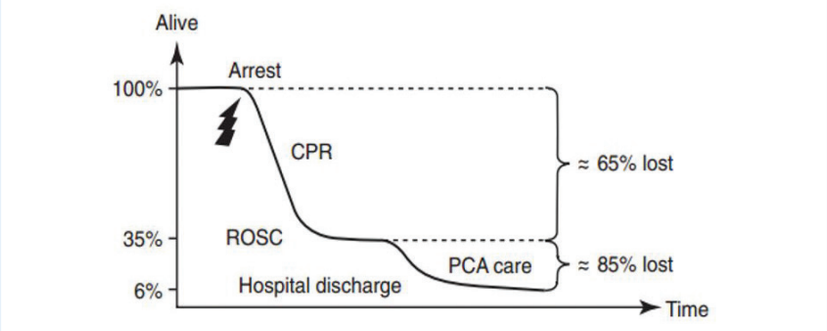

While ischemia creates the initial insult, paradoxically, the return of perfusion causes further damage to the organ itself and may induce systemic damage to distant organs (Figure 2). Ischemia is when oxygen supply exceeds the demand for normal tissue function.[4] It results in anaerobic glycolysis and significantly decreased production of energy to two ATP + lactate. Elevating lactate levels will lower the pH in the tissue, which feedbacks negatively to inhibit ATP production. ATP is broken down into hypoxanthine and xanthine, which later becomes important in reperfusion injury and the production of free radicals. The Na-K ATPase and calcium membrane pumps no longer work with no ATP production. This results in an influx of intracellular water and cellular swelling.[4] Increased intracellular calcium results in conversion of the enzyme xanthine dehydrogenase to xanthine oxidase. With the return of blood flow, there is an influx of oxygen into the tissues, which catalyzes xanthine oxidase to degrade hypoxanthine and xanthine, thus liberating the highly reactive superoxide anion (O_2-) and uric acid as by-products. Superoxide is subsequently converted to the hydroxyl radical (OH-). Consequently, it results in peroxidation of the cell's lipid membranes and the production and systemic release of pro-inflammatory eicosanoids, disruption of cell permeability, and ultimately cell death.

Neuronal tissue is sensitive during anaerobic glycolysis and will deplete its ATP resources within two to four minutes compared to 20 to 40 minutes in the gastrointestinal tract and myocardium.[2] Myocyte dysfunction results from ischemia and reperfusion similar to what occurs at the cellular level in the nervous system.[2] Neuronal injury can manifest as delirium to coma, seizures, myoclonus, cognitive dysfunction, cortical blindness, or brain death. Myocardial dysfunction is characterized by increased central venous pressure and can clinically manifest as reduced cardiac output, arrhythmias, hypotension, cardiogenic shock, or even cardiovascular collapse in severe cases.[2, 3]

Targeted therapy

Monitoring the post-cardiac arrest patient uses the same principles as those you would apply to the critical patient. The goal immediately after ROSC is to sustain spontaneous circulation and perfusion of vital organs (i.e., brain, myocardium), attenuating further injury and preventing re-arrest.

"Sepsis-like syndrome"

Systemic ischemic-reperfusion injury is a sepsis-like syndrome because it shares many of its characteristics in relation to coagulation, inflammation, and the endothelium. Treatment is highly individualized but is similar to sepsis therapy and targeted at early hemodynamic optimization, glycemic control, and situational adrenal dysfunction (critical illness-related corticosteroid insufficiency or CIRCI). Hemodynamic goals to reach are a mean arterial pressure of 80mmHg or higher, a central venous oxygen saturation of 70% or more, and a lactate of less than 2.5mmol/L.5 Strategies include the administration of intravenous fluids with the addition of vasopressors, inotropes, and blood products to reach these goals with frequent re-assessment of these endpoints.[2,3,5] Hyperglycemia is common in human PCA patients, and animal studies demonstrate that it worsens ischemic brain injury.[3] Human studies have shown no difference in mortality between PCA patients with tight glycemic control (72 to 108 mg/dL) versus moderate (108 to 140mg/dL) glycemic control.[3] Currently, moderate glycemic control is suggested for human PCA patients, and a similar strategy may be considered in cats and dogs.[2,3] While steroid administration in sepsis and PCA in humans is controversial, CIRCI has been identified in several human clinical studies after ROSC as associated with increased mortality.[3,5] Administration of low-dose hydrocortisone in dogs and cats with vasopressor-dependent shock after CPA, with or without documented CIRCI, is reasonable.[3,5]

Neuroprotective strategies

If mechanical ventilation and advanced critical care capability are available, mild therapeutic hypothermia (MTH) is recommended in patients that remain comatose after ROSC. MTH helps attenuate further injury to both the brain and heart in PCA. In human medicine, patients are actively cooled between 89.8 to 92° F core body temperature with cooling blankets, ice packs, IV infusions of ice-cold saline, and endovascular cooling devices. It is started immediately after ROSC, but the ideal duration of MTH is unknown, with more severely injured patients likely to require a longer duration. MTH is one of the only treatments proven in clinical trials to benefit patients with PCA due to its neuroprotective effects. It decreases mitochondrial injury, reduces cerebral metabolism, and decreases the production of reactive oxygen species. In dogs and cats, the target MTH is the same for people with slow rewarming (0.25 to 0.5°C per hour) if mechanical ventilation and critical capabilities are possible.[5] These patients must be sedated, intubated, and ventilated to avoid shivering and increased muscle tone. However, permissive hypothermia is an alternative in spontaneously hypothermic patients after CPA. The presence of coma and the absence of pupillary light reflex 24 to 72 hours after ROSC significantly increase the likelihood of a poor neurological outcome.

Other neuroprotective strategies include monitoring for non-convulsive seizures (only identified by electroencephalography) and anti-convulsant treatment, as seizures increase cerebral metabolism and oxygen demand.

Myocardial dysfunction

Myocardial injury and resulting dysfunction are also likely attenuated by hypothermia. Other than MTH, no other treatments have been identified to be clinically effective in attenuating myocardial dysfunction.[4] Echocardiogram is used for diagnosis, and serial echocardiograms for progression, response to treatment, and resolution. Dobutamine administration is the treatment of choice for improving systolic function and output in cats and dogs.[2] Cardiac arrhythmias should also be addressed as needed based on their severity. Fortunately, myocardial dysfunction is reversible and typically resolves in 48 hours.

Re-oxygenation

While re-oxygenation after global ischemia is the goal of PCA care, controlled re-oxygenation is important to avoid hypoxemia and hyperoxemia. Oxygenation guidelines recommend maintaining a fraction of inspired oxygen (FiO_2) that produces an arterial oxygen saturation of 94 to 96%.[5] In the early stages of reperfusion, hyperoxemia harms post-ischemic neurons by causing excessive

Post-Cardiac Arrest

CONTINUED FROM PAGE 2

Figure 2

Ischemia and Reperfusion Injury (From Cowled: Mechanisms of Vascular Disease)

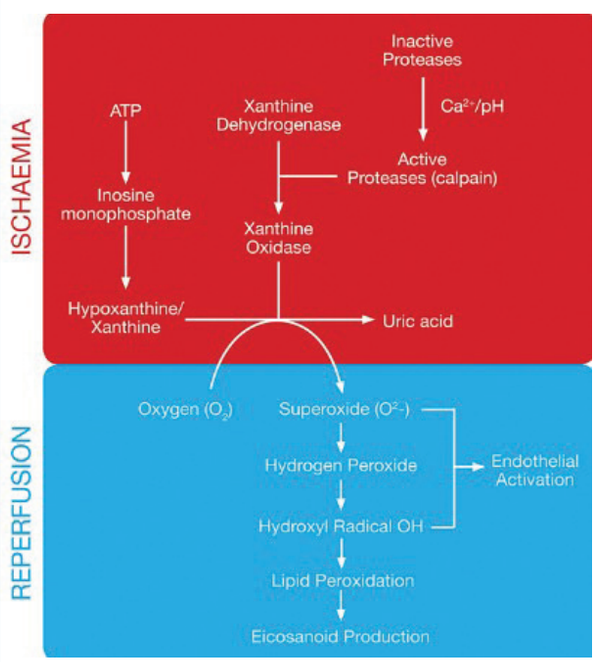

oxidative stress. Evidence suggests that "arterial hyperoxemia soon after ROSC increases oxidative brain injury and neurodegeneration, and worsens functional neurological outcome and negatively impacts overall survival."[2]

Positive pressure ventilation is not routinely recommended in all PCA patients but is usually needed in the PCA patient who is hypoventilating or cannot maintain normocapnia or normoxemia.[5]

Precipitating factors

Persistent precipitating pathology and pre-existing co-morbidities will influence prognosis as they will persist after ROSC and add great variability to the PCA patient population. Limited information is available about what these factors are in small animal populations. Precipitating factors need an individualized approach using critical care principles to support oxygenation, ventilation, and circulation to realize a patient's potential for a positive and meaningful outcome.

REFERENCES

1. Hoffmeister EH, et al. Prognostic indicators for dogs and cats with cardiopulmonary arrest treated by cardiopulmonary cerebral resuscitation at a university teaching hospital, JAVMA 235(1): 50-57, 2009.
2. Boller M, et al. 2015. Post-Cardiac Arrest Care in Silverstein D. Small Animal Critical Care.
3. Neumar, Robert W et al. Post-Cardiac Arrest Syndrome: epidemiology, pathophysiology, treatment, and prognostication. A consensus statement from the International Liaison Committee on Resuscitation (American Heart Association, Australian and New Zealand Council on Resuscitation.) Circulation 2008; 118 (23): 2452-2483.
4. Cowled Prue et al. 2011. Pathophysiology of Reperfusion Injury in Fitridge R, et al, Mechanisms of Vascular Disease: *A Reference Book for Vascular Specialists [Internet].* Adelaide (AU): University of Adelaide Press.
5. RECOVER evidence and knowledge gap analysis on veterinary CPR. Part 7: Clinical Guidelines. Fletcher, Daniel J et al. Journal of Veterinary Emergency and Critical Care 22 (S1) 2012, p S102-S131.

Recognizing Signs of Pain in Exotic Animal Species

CONTINUED FROM PAGE 1

Figure 1

Comfortable rabbit with wide facial features (top) versus angular, narrowed facial features indicating discomfort (bottom)



pain in our exotic species, it is important to appreciate that any animal can perceive noxious (unpleasant) stimuli. Nociception is the process by which the nervous system encodes these stimuli and requires no input from the central nervous system – think of the reflex of pulling your hand away from a hot stove. Pain is associated with and results in learned avoidance – we can think of this as a person learning to stay away from hot stoves after getting burned. All animals, including invertebrates, have shown evidence of learned avoidance in studies. Therefore, we *must* assume that all sentient organisms have the capacity to experience pain and must approach any potentially painful procedure or disease process with this in mind, even if we cannot outwardly see any obvious signs of discomfort.

Pain in Small Mammals

Recognizing pain in our small mammal species is often the easiest of all exotic species. They are most similar to dogs and cats and display facial expression changes associated with pain. It is still important to note that rabbits and rodents are prey animals and very good at hiding signs of extreme discomfort. A freeze response is quite common in these animals when approached by predators – including people – and often masks changes to facial expressions.

That being said, the grimace scale developed by Dr. Matthew Leach and the National Centre for the Replacement Refinement and Reduction of Animals in Research provides a reliable and objective assessment of facial changes associated with pain in rabbits, mice, and rats and can be extrapolated to other small mammals as well. A rounded "fluffy" face, whiskers with a downward curl, wide orbits, and ears facing sound sources are associated with a comfortable animal. Narrowing of the eye (orbital tightening), flattening of the cheeks causing the face to appear more angular, rotation of the ears (toward the back/hind end in rabbits and curled forward in rodents), and stiffening of the whiskers to stand out from the face are all signs of significant pain. Generally, the more angular the face, the more significant the pain is for the animal.

Pain in Avian Species

As we move away from mammals, signs of discomfort can be more difficult to assess. Humans rely heavily on facial expressions and cues to pick up on pain. Outside of the class Mammalia, facial muscle movements are not utilized as frequently for communication or expression.

Birds' display of pain can differ depending on the type of bird: parrots and poultry tend to be social species and show different signs than birds of prey and other solitary species. Over-preening of a painful area and decreases in "self-care" behaviors, like grooming, vocalizing, and playing, are common signs of pain in most birds. Separating oneself from the flock in social species and changes in behavior are often seen with discomfort, as well. Again, since birds are often prey species, clinicians may be required to observe the bird from a distance or rely on owner recognition of abnormalities at home, as signs are often hidden in the clinic unless the bird is significantly debilitated.

Pain in Reptiles, Amphibians, and Invertebrates

Pain recognition in reptiles, amphibians, and invertebrates can be challenging, even for experienced clinicians. Research in these species is limited, and fewer facial muscles and rigid structure to the scales/exoskeleton make looking for changes in facial expression impossible when evaluating for pain. Several surveys given to clinicians and owners of these species for cases associated with pain in other animals found increased aggression, changes in mobility, gaping of the mouth, changes in coloration, and changes in appetite as the most common signs reported. While nonspecific, these signs must be associated with discomfort, especially in diseases considered painful in mammals.

Conclusion

It can often seem daunting to be able to recognize discomfort in animals so far removed from our traditional dogs and cats. What remains most important for the clinician seeing exotic animal species is remembering that signs of pain are often well hidden by most of these animals. Being cognizant that any condition considered painful in dogs and cats should be regarded as painful in other species can go a long way in recognizing and managing pain, hopefully improving clinical outcomes and quality of life for these animals.

Figure 2

Over-preening and feather-destructive behavior on a parrot wing secondary to underlying pain.

AVIAN & EXOTIC MEDICINE

Recognizing Signs of Pain in Exotic Animal Species

CONTINUED FROM PAGE 4

REFERENCES

1 Ayers H. Pain recognition in reptiles and investigation of associated behavioural signs. *The Veterinary Nurse*. 2016; 7(5): 292-300.

2 Keating SC, Thomas AA et al. Evaluation of EMLA for preventing pain during tattooing of rabbits: changes in physiological, behavioural and facial expression responses. *PLoS One*. 2012; 7(9):e44437.

3 Mikoni N, Sanchez-Migallon Guzman D, Fausak E and Paul-Murphy J. Recognition and assessment of pain-related behaviors in avian species: an integrative review. *Journal of Avian Medicine and Surgery*. 2022; 36(2):153-172.

4 Oliver V, De Rantere D et al. Psychometric assessment of the rat grimace scale and development of an analgesic intervention score. *PLoS One*. 2014; 9(5):e97882.

5 Reijgwart ML, Schoemaker NJ et al. The composition and initial evaluation of a grimace scale in ferrets after surgical implantation of a telemetry probe. *PLoS One*. 2017; 7(4):e35656.

6 Upton D and Solowiej K. Pain and stress as contributors to delayed wound healing. *Wound Practice and Research*. 2010; 18(3): 114-122.

↘ Emergency & Critical Care Service at Angell West; Urgent Care Available by Appointment

The Emergency & Critical Care service at the MSPCA-Angell West (Waltham, MA) is available 24/7 for clients whose pets need immediate medical care for life-threatening trauma or disease.

Referring veterinarians may alert staff to an incoming case by calling 781-902-8400. Due to expected high case load, there may be times when Angell West diverts cases. Please call to ensure availability.

For more information, please visit ***angell.org/emergency****.*

For non-emergent cases, the Urgent Care service at Angell West is available Mondays, Tuesdays, and Wednesdays, 8am-6pm by calling 781-902-8400. Urgent Care appointments are available through the Angell West Avian and Exotics service by calling 617-989-1561. **Clients can call up to one day in advance to book an Urgent Care appointment; this is not a walk-in service.**

For more information, please visit ***angell.org/urgent.***



Pectus Excavatum in Puppies and Kittens

Sue Casale, DVM, DACVS
angell.org/surgery | surgery@angell.org | 617-541-5048

Pectus excavatum, from Latin meaning "hollow breast," is a chest wall deformity seen frequently in humans and less often in veterinary patients.[1] It has been described in dogs, cats, lambs, calves, rabbits, and sea otters.[2,3] It is a congenital defect where the caudal ribs and sternum do not grow properly, resulting in a concavity starting around the third to fifth rib and continuing to the xiphoid process.[1,2] This deformity causes compression of the right side of the heart with a deviation of the heart to the left side of the thorax.[4] Pectus excavatum is the most common chest wall deformity seen in people and animals, accounting for 90% of human cases.[1] In people, it occurs in approximately one in 400 live births and is more common in males, with as high as a 9:1 ratio reported.[1,4] It is not considered common in animals, and no sex predilection has been described. Pectus excavatum was first described in people in the early 1600s, and several case reports from the late 1800s were published.[1] The first surgery for pectus excavatum was reported in 1911 and involved the removal of rib cartilage.[1] The first reported case of pectus excavatum in an animal was in 1968 in a Siamese cat.[5] The first report in dogs was in 1973 in three Setter-cross littermates.[6] Since then, there have been numerous case reports of the condition, but because it is fairly rare, the literature is still limited.

↘ Pectus excavatum, seen here, is a congenital defect resulting in a chest wall deformity.

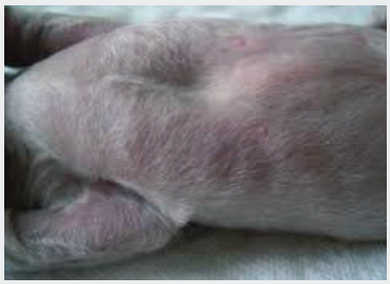

The etiology of pectus excavatum is unknown. Early theories ranged from hypertension of the diaphragm and nutritional disturbances causing a weakness of the sternum to increased intrauterine pressure, causing the fetus' chin to compress the thorax.[1] The current thought is that a defect in metabolism in the sternocostal cartilage leads to biomechanical weakness and overgrowth.[1] The condition has been shown to be genetic in people, with 43% of patients having a family history.[4] There is an association between scoliosis and connective tissue disorders like Marfan, Noonan, and Ehlers-Danlos syndromes.[4] Predisposition for pectus excavatum is seen in Bengal and Burmese cats as well as brachycephalic dogs, most commonly in the Maltese and English Bulldog.[7-10] Acquired pectus excavatum has been reported in people secondary to respiratory obstruction, and there is a single case report describing acquired pectus excavatum in a dog secondary to laryngeal paralysis.[11,12] Recently, a rat model for pectus excavatum has been reported where removal of the last four costal cartilages results in collapse of the sternum.[13]

Pectus excavatum is present at birth and is detectable within days in puppies and kittens.[2,12] The defect worsens with growth, and in people, it is sometimes not obvious until adolescence.[1,4] Once growth ceases, the condition does not progress. The clinical signs can be variable, with most cases in humans presenting with mild signs or concern about cosmesis.[4] In severe cases, disabling cardio and respiratory compression are present and clinical signs worsen with age. Dyspnea, chest pain, fatigue, palpitations, tachycardia, and exercise intolerance have all been reported in people.[4] Dyspnea is the most common clinical sign in animals.[12] Exercise intolerance, inappetence, recurrent respiratory infections, weight loss, cough, cyanosis, and heart murmurs are also reported.[12,14]

Pectus excavatum is diagnosed on physical examination; however, imaging helps to determine the severity of the condition. The anthropometric or clinical index measures the depth of the defect and compares it to the depth of the thorax.[15,16,17] This is a simple test that requires no additional equipment. Radiographs show the degree of deformity and can be used to calculate several different indices which assess

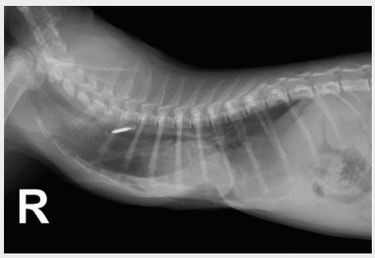

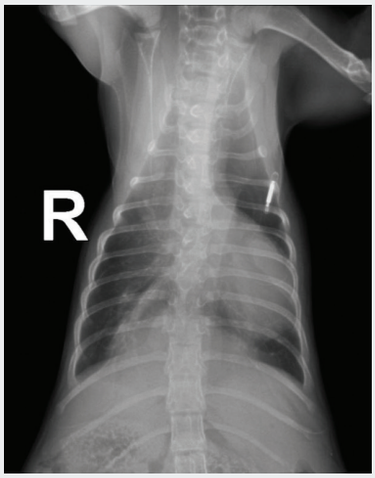

the amount of compression. The frontosagittal index (FSI) compares the width of the thorax at its widest point with the depth of the thorax at its most narrow point, and a ratio is determined.[16] The vertebral index (VI) compares the distance between the dorsal border of the spine and the sternum at the narrowest point with the depth of a vertebral body.[16] In animals, two-view thoracic radiographs can be used to calculate both the FSI and the VI and, when combined with clinical signs, help to determine if surgery is recommended. The Haller index (HI), also called the pectus index, was first described in 1987 and is calculated by dividing the transverse diameter of the chest by the narrowest anterior-posterior distance on a computed tomography (CT) scan axial slice.[16,18] The Haller index is the most

Pectus Excavatum in Puppies and Kittens

CONTINUED FROM PAGE 6

An external splint to address pectus excavatum

commonly used pectus excavatum index used in people. It can also be calculated using plain film and has been shown to correlate well with CT calculations.[16] Indices may not correlate with clinical signs in some cases. CT scan has been shown to result in a lower vertebral index and a higher frontosagittal index in kittens when compared to radiographic measurements.[19] CT was useful in determining if the xiphoid was midline or lateralized with the thought that midline defects cause more clinical signs.[19] CT scan also helped determine safe corridors for surgical suture placement.[19]

Treatment for pectus excavatum depends on the severity of the clinical signs. Pain is a common complaint in human patients, and non-steroidal anti-inflammatory medication and acupuncture have been reported to help.[4] Physical therapy has been recommended to help strengthen the chest muscles and help develop the ribcage. Daily medial and lateral compression of the chest or compression bandages have been described for neonatal puppies and kittens; however, this is unlikely to improve severe deformities.[2] In people, using a vacuum bell has been successful in milder cases and in young patients who still have a compliant thorax.[20] Several hours of daily use is required, and patients wear the device for up to two years after the deformity is corrected. Surgery is needed for severe pectus excavatum or in older patients. The two most commonly performed surgeries are the Ravitch procedure and the less invasive Nuss procedure. The Ravitch procedure involves an open surgical approach by removing the deformed cartilage and implanting metal bars to support the sternum. This is a lengthy procedure with potentially significant morbidity. The Nuss procedure is performed under thoracoscopic guidance, and a curved metal bar is placed and then flipped into position to raise the sternum.[21,22,23] In veterinary patients, the choice of surgery is dependent on age. In older animals, an open approach is required to correct the deformity. Ostectomy of a portion of the costal cartilage is required to allow the sternum to be realigned, and an internal splint, such as a bone plate, is used to keep the sternum in this position.[24] An open approach to release the sternum, combined with an external splint, has also been described.[25,26] Animals under four months of age will typically have a compliant thorax, and external splints with circumsternal sutures can be used.[27] The sutures are tied to the splint to keep the thorax in a normal position, and the splint is left in place for three to four weeks.[27,28,29] Complications associated with surgery include inadvertent puncture of the lungs or heart, pneumothorax, hemorrhage, and re-expansion pulmonary edema, which can be fatal.[28,30] Minor complications include bandage sores and abrasions from the splint or reaction to the sutures.

Anesthesia in patients with pectus excavatum can be challenging.[31] Ninety-five percent of patients present with some degree of ventricular compression.[31] Heart murmurs and arrhythmias are common.[14,31] Underlying respiratory disease, including infections, should be treated before surgery, and assisted ventilation is needed during anesthesia. Because surgery is often performed in very young puppies and kittens, their body temperature should be carefully monitored as their thermoregulation is not fully developed, and they have little fat. Their metabolism rate is higher than adult patients, so they require shorter fasting times and higher fluid rates.[14] Enzymes systems should be fully developed by four weeks allowing the use of injectable medications.[14]

Pectus excavatum is a treatable condition with a favorable prognosis in puppies and kittens. Severe cases can do well with surgery. A procedure with circumsternal sutures and an external splint is the most commonly performed in young animals. Surgery is best accomplished between eight and 12 weeks when the thorax is still compliant but the patient is old enough to tolerate anesthesia.

REFERENCES

1. Brochhausen C, Turial S, Muller FKP, et al. Pectus excavatum: history, hypotheses and treatment options. Interac CV Thorac Surg 2012; 14: 801-806
2. Singh M, Parrah JUD, Moulvi, BA et al. A review on pectus excavatum in canines: a congenital anomaly. Iran J Vet Surg 2013; 8(1): no 18 59-64
3. Mann N, MacLean J, et al. Pectus excavatum and swimmer puppy syndrome with concurrent congenital cardiac anomalies in two domestic rabbits. J Ex Pet Med 2019; 29: 212-216
4. Abid I, Ewais MM, Marranca J, et al. Pectus excavatum: a review of diagnosis and current treatment options. J Am Osteopath Assoc 2017; 117(2):106-113
5. Grenn HH, Lindo DE, Pectus excavatum (funnel chest) in a feline. Can Vet Jour 1968; 9(12):279-282
6. Pearson JL, Pectus excavatum in the dog (a case report). Vet Med 1973; 125-128
7. Charlesworth TM, Sturgess CP, Increased incidence of thoracic wall deformities in related Bengal kittens. J Fel Med Surg 2012; 14(6): 365-368
8. Sturgess CP, Waters L, et al. Investigation of the association between whole blood and tissue taurine levels and the development of thoracic deformities in neonatal Burmese kittens. Vet Record 1997; 141: 566-570
9. Komsta R, Osinski Z, Debiak P, et al. Prevalence of pectus excavatum (PE), pectus carinatum (PC), tracheal hypoplasia, thoracic spine deformities and lateral heart displacement in thoracic radiographs of screw-tail brachycephalic dogs. PLOS ONE 2019
10. Hassan EA, Hassan MH, Torad FA, Correlation between clinical severity and type and degree of pectus excavatum in twelve brachycephalic dogs. J Vet Med Sci 2018; 80(5):766-771
11. Kurosawa TA, Ruth JD, et al. Imaging diagnosis- acquired pectus excavatum secondary to laryngeal paralysis in a dog. Vet Rad Ultra 2012; 53(3):329-332
12. Fossum TW, Boudrieau RJ, Hobson HP, Pectus excavatum in eight dogs and six cats. JAAHA 1989; 25:595-605
13. David VL, Ciornei B, Horhat FG, et al. Rat model of pectus excavatum. Life 2020; 10:96
14. Boudrieau RJ, Fossum TW, et al. Pectus excavatum in dogs and cats. Compend Cont Ed 1990; 12(3): 341-355
15. Rebeis EB, Milanez de Campos JR, et al. Anthropometric index for pectus excavatum. Clinics 2007; 62(5):599-606
16. Martinez-Ferro M, Indexes for pectus deformities. In Chest Wall Deformities and Corrective Procedures Springer Inter Pub, Switzerland, 2016

SURGERY

Pectus Excavatum in Puppies and Kittens

CONTINUED FROM PAGE 7

17 Sujka JA, St. Peter SD, Quantification of pectus excavatum: anatomic indices. Sem Ped Surg 2018; 27(3):122-126

18 Poston PM, Patel SS, Rajput M, et al. The correction index: setting the standard for recommending operative repair of pectus excavatum. Ann Thorac Surg 2014; 97:1176-1180.

19 Charlesworth TM, Schwarz T, Sturgess CP, Pectus excavatum: computed tomography and medium-term surgical outcome in a prospective cohort of 10 kittens. J Fel Med Surg 2016; 18(8):613-619

20 Haecker FM, Sesia S, Non-surgical treatment of pectus excavatum. J Vis Surg 2016;2:63

21 Hebra A, Calder BW, Lesher A, Minimally invasive repair of pectus excavatum. J Vis Surg 2016;2:73

22 Sakamoto Y, Yokoyama Y, et al. Outcomes of the Nuss procedure for pectus excavatum in adults. J Plast Recon Aesth Surg 2020

23 Xie Y, Ning J, Application of polydioxanone sutures in the Nuss procedure. Thorac Cardiovasc Surg 2021

24 Risselada M, de Rooster H, Liuti T, et al. Use of internal splinting to realign a noncompliant sternum in a cat with pectus excavatum. JAVMA 2006; 228(7): 1047-1052

25 Mestrinho LA, Ferreira CA, et al. Open surgical correction combined with an external splint for correction of a non-compliant pectus excavatum in a cat. J Fel Med Surg 2011; 14(2):151-154

26 Crigel MH, Moissonnier P, Pectus excavatum surgically repaired using sternum realignment and splint techniques in a young cat. J Small Ani Pract 2005; 46:352-356

27 McAnulty JF, Harvey CE, Repair of pectus excavatum by percutaneous suturing and temporary external coaptation in a kitten. JAVMA 1989; 194(8): 1065-1067

28 Fossum TW, Boudrieau RJ, et al. Surgical correction of pectus excavatum, using external splintage in two dogs and a cat. JAVMA 1989; 195(1):91-97

29 DeGroot W, Tobias KM, External splinting for pectus excavatum in kittens. Clinician's Brief, May 2018

30 Soderstrom MJ, Gilson SD, Gulbas N, Fatal reexpansion pulmonary edema in a kitten following surgical correction of pectus excavatum. JAAHA 1995; 31:133-136

31 Patvardhan C, Martinez G, Anaesthetic considerations for pectus repair surgery. J Vis Surg 2016;2:76

It's Not a Tumor: Approach to Vestibular Syndrome in Old Dogs

Jennifer R. Michaels, DVM, DACVIM (Neurology)
angell.org/neurology | neurology@angell.org | 617-541-5140

Vestibular syndrome is one of the most common neurological clinical presentations in dogs. Vestibular syndrome refers to the collection of clinical signs caused by disruption of the normal function of the vestibular system. As with other clinical syndromes, specific considerations are considered when evaluating geriatric patients.

The function of the vestibular system is to maintain balance and equilibrium. It can be broken down into peripheral and central components. The peripheral vestibular system comprises structures of the inner ear and the vestibular portion of cranial nerve VIII. The central vestibular system is comprised of the brainstem and cerebellum.

Classic clinical signs of vestibular syndrome include head tilt, vestibular ataxia (characterized by leaning, falling, circling, or alligator rolling), positional ventral or ventrolateral strabismus, and pathologic nystagmus. These signs occur in the direction of the lesion, with the exception of the fast phase of nystagmus, which is away from the lesion. The exception to this rule is paradoxical vestibular syndrome caused by specific cerebellar lesions, which result in vestibular signs in the opposite direction as expected.



	Peripheral	Brainstem	Cerebellum
Additional Potential Deficits	• Horner's syndrome • Facial nerve dysfunction	• Mentation change • Other cranial nerve deficits • Weakness • Proprioceptive deficits (postural reaction delays, proprioceptive ataxia)	• Cerebellar ataxia (hypermetria, dysmetria) • Intention tremor • Truncal sway • Proprioceptive deficits (postural reaction delays, proprioceptive ataxia)

One of the key points to remember is that the clinical signs of the vestibular syndrome itself are identical, no matter the location of the lesion. The distinction between peripheral and central disease depends upon evaluating and identifying other neurological signs that the lesion could cause.

Diseases Causing Peripheral Vestibular Syndrome

Hypothyroidism is a common endocrine disorder in geriatric dogs. Approximately 7.5% of dogs with hypothyroidism will present neurological signs, including peripheral vestibular dysfunction, facial nerve paralysis, or lower motor neuron para- or tetraparesis. These clinical syndromes can occur individually or together. Signs can be acute onset or insidious, progressive or non-progressive. It is important to note that many patients with neurological dysfunction secondary to hypothyroidism do not have the classic systemic clinical signs. Diagnosis and treatment are standard for hypothyroidism (measuring thyroid hormone levels; levothyroxine 0.02 mg/kg PO q24 hours). Most affected dogs will respond positively to supplementation, with improvement in clinical signs usually occurring over several weeks.

Otitis media/interna is one of the most common causes of peripheral vestibular syndrome in dogs. Although the proportion of affected dogs with otitis is higher in younger dogs, it still comprises a significant proportion of peripheral vestibular disease in older dogs. Most otitis media/interna cases are caused by bacterial infections descending from the external ear canal. Clinical signs can be either acute onset or insidious, progressive or non-progressive, including facial nerve dysfunction and/or Horner's syndrome.

A definitive diagnosis of otitis media/interna requires advanced imaging of the head (CT or MRI), myringotomy, deep ear flush, and culture of the middle ear, although a strong presumptive diagnosis can be made in some cases. Otic examination and otic cytology are critical diagnostic tools in these cases, allowing for visualization of an inflamed or bulging tympanic membrane, ruptured tympanic membrane, or purulent material within the ear as well as cytologic evidence of infection. Treatment of otitis media/interna involves systemic antibiotic therapy for six to eight weeks. Ideally, antibiotic choices are based on a culture of the middle ear; however, Clavamox (16 to 20 mg/kg PO Q 12 hours) is a good empirical choice. Cases in which a full diagnostic workup is strongly recommended include dogs that do not respond to empirical antibiotic therapy, patients that were successfully treated but experienced a recurrent infection, or patients with chronic ear disease that has been managed long-term with multiple rounds of antibiotic therapy. These patients are much more apt to have resistant infections. Given that most affected dogs also have otitis externa, topical therapy is also important for managing current signs and future risk of recurrence. Avoiding products with otic toxic ingredients (aminoglycoside antibiotics and chlorhexidine) is critical.

The prognosis for otitis media/interna is good, and most dogs will show improvement in clinical signs within one week of starting appropriate antibiotic therapy. However, it can take several weeks for them to reach maximal neurological improvement. Many affected dogs will have residual neurological signs, most commonly a mild head tilt +/- facial nerve dysfunction.

It's Not a Tumor: Approach to Vestibular Syndrome in Old Dogs

CONTINUED FROM PAGE 9

Idiopathic vestibular disease, also known as old dog vestibular disease or geriatric vestibular disease, is the most common cause of peripheral vestibular syndrome in geriatric dogs. Clinical signs are classically peracute onset and regressive. There is no directed treatment for dogs with idiopathic vestibular disease; treatment centers on supportive care such as anti-nausea medications, anti-anxiety medications, +/- IV fluids, and nursing care. The prognosis with idiopathic vestibular disease is generally good, with most patients showing signs of improvement after two to three days and complete recovery occurring in two to three weeks.

Diseases Affecting the Central Vestibular System

Primary brain tumors account for 85% of diagnosed intracranial neoplasms, with the remaining 15% being metastatic cancers. Clinical signs can be acute but are often insidious and almost always progressive. Unfortunately, diagnosis of intracranial neoplasia does require advanced imaging. Otherwise, we are limited to a presumptive diagnosis based on the patient's age and clinical history. Treatment options for intracranial neoplasia depend highly on the tumor location and type. Anti-inflammatory steroids (prednisone 1mg/kg/day) are the only empirical therapy option and work to reduce perilesional edema in the brain, often temporarily improving neurological symptoms. When considering all brain tumor types and locations, the median survival time with palliative treatment with steroids alone is approximately two to four months. However, infratentorial location, which would account for the majority of dogs relevant to this discussion, has been identified as a negative prognostic indicator with a lower median survival time of one month. Definitive therapies for brain tumors include chemotherapy and radiation therapy, which can afford many more months or even years of survival, although these treatments require a definitive diagnosis.

Ischemic strokes occur due to the occlusion of a blood vessel supplying an area of the brain. Classically, clinical signs are peracute onset and almost always regressive, with spontaneous improvement occurring over several days to several weeks. Strokes can cause a variety of neurological signs, which are referrable to the area of the brain affected. However, the rostral cerebellar artery is most commonly affected in dogs, resulting in vestibulocerebellar symptoms.

In dogs, approximately 50% of ischemic strokes are associated with some underlying risk factor. Risk factors include hypertension, hypothyroidism, Cushing's disease, chronic kidney disease, protein-losing disease (PLN, PLE), diabetes mellitus, hyperviscosity syndromes, hypercoagulability disorders, or tumor embolus. The remaining 50% of strokes are considered idiopathic. Although a definitive stroke diagnosis requires advanced imaging, a fairly strong presumptive diagnosis can often be made based on clinical history. Investigation for underlying risk factors is critical, and the minimum diagnostic evaluation should include CBC, chemistry panel, thyroid hormone panel, urinalysis, UPC, and blood pressure. Additional diagnostic testing that may be indicated depending on the specific patient, as well as the results of the initial diagnostic testing, may include VCM or TEG (measures of coagulation and methods of evaluating for hypercoagulability), chest X-rays, abdominal ultrasound, and/or ACTH stimulation test or low dose dexamethasone suppression test.

There are no directed treatments for an ischemic stroke. Treatment centers around supportive care similar to what was discussed for idiopathic vestibular disease and managing any underlying causes to prevent a recurrence. The prognosis for a stroke is generally good, with most patients showing spontaneous regression of clinical signs within the first few days, although the recovery speed is highly variable (days to weeks).



Nutritional Support for Critically Ill Animals

Catherine Sumner, DVM, DACVECC
angell.org/waltham/emergency-and-critical-care | emergency@angell.org | 781-902-8400

Among the patients presenting to the emergency service with various types of critical illness, one common clinical sign is inappetence, ranging from decreased food intake (hyporexia) for days or weeks to, in some patients, a progression to anorexia (complete food refusal). Patients with critical disease enter a negative energy balance where they mobilize protein, thus depleting their lean body mass. This can result in decreased wound healing, adverse effects on immune function, and an unfavorable prognosis. Patients with a negative energy balance may have more complications and an extended hospital stay. It is well documented that addressing the animal's nutritional needs is critical to effectively managing and recovering these patients.

Additionally, a lack of enteral nutrition can predispose a patient to gastrointestinal bacterial translocation, leading to sepsis. Brunetto et al. (JVECC 2010) investigated the relationship between nutritional support and discharge from the hospital in dogs and cats, and they found that there appeared to be a positive association between providing nutrition and hospital discharge. Other veterinary studies have shown a more rapid clinical improvement and shorter hospitalization in patients receiving early nutritional support.

A multimodal approach is necessary when developing a nutritional treatment plan for a patient. It is important to address any pain and discomfort the animal may be experiencing, as this could cause decreased food intake. However, using opiate medications for pain can worsen nausea and cause constipation. Additionally, opiate medication administration can result in a sedated patient who is even less likely to take in nutrition voluntarily. Thus, it is important to balance pain control needs and medication administration, as well as consider local analgesic options (e.g., local blocks, soaker catheters) to decrease overall systemic need.

Many of these patients are treated with injectable anti-nausea medications such as maropitant, dolasetron, and metoclopramide, which is more effective as a pro-motility agent. Sometimes, patients are placed on more than one of these medications concurrently. Critically ill patients often receive antibiotics, opiates, and other medications that can worsen nausea, ileus, and other gastrointestinal signs. It can be useful to administer these medications simultaneously as anti-nausea medications to decrease the potential for adverse side effects. Historically, critically ill patients have also been treated aggressively with acid suppressant drugs, such as histamine-2 receptor blockers (i.e., famotidine) and proton pump inhibitors (i.e., pantoprazole). However, recently there has been a movement towards more judicious use of acid suppressant drugs, as there is data to support that they are less effective than initially thought. PPIs are most used but are most effective in patients with ulcerative gastrointestinal disease.

Another consideration is the use of appetite stimulants. Historically, patients have received mirtazapine and cyproheptadine as appetite stimulants. Recently, a selective ghrelin receptor agonist medication, capromorelin, has been released to the market, which acts as a powerful appetite stimulant. Typically, ghrelin is produced by cells in the gastrointestinal tract and acts in the brain on hypothalamic cells to increase hunger, the secretion of gastric acid, and gastrointestinal motility. It also acts in the pituitary gland to increase growth hormone secretion. Capromorelin is currently FDA-approved for use in canine patients, appears to have few side effects, has no minimum age or weight requirements, and can be used in the short term or as a chronic medication (with no limit to how long it can be used). Recommended oral dosing is 3 mg/kg, administered once a day.

Options for providing nutrition include enteral (via the gastrointestinal tract) and/or parenteral (via an intravenous route). Enteral support is the favored option whenever possible, as it has physiologic benefits for the gastrointestinal tract, maintaining the intestinal villi and mucosa. Enteral nutrition can be provided via voluntary food ingestion by the patient, syringe feeding, or an enteral feeding device. While it is important to provide nutrition early in a patient's hospitalization, it is essential to address hypothermia and hypotension, as these can result in decreased gastrointestinal perfusion and motility.

Feeding tube options include a nasoesophageal or nasogastric tube, esophagostomy tube, gastrostomy tube, or jejunostomy tube. In our practice, nasoesophageal, nasogastric, and esophagostomy tubes are commonly used and will be discussed in this review. In many cases, we find that it is important to initiate a discussion about a potential feeding tube with the family early in a patient's hospitalization, as it is often a step that requires consideration and generates numerous questions. Nasoesphageal/nasogastric tubes are easy to place, requiring only sedation rather than full general anesthesia. However, due to their small diameter, a liquid diet is necessary, and they can only be used for short-term care. Also, some animals find them to be uncomfortable and irritating, and occasionally, a patient may sneeze the tube out or vomit up the tube. If the tube is displaced during emesis, it is important to remove it quickly, as the patient may chew the tube and ingest part of it (if it is not detached).

EMERGENCY & CRITICAL CARE

Nutritional Support for Critically Ill Animals

CONTINUED FROM PAGE 11

An esophagostomy tube would be recommended if the patient requires longer-term nutritional support and the owner is amenable. Esophagostomy tube placement is a procedure that can easily be performed in general practice, as it does not take a significant amount of time and does not require specialized surgical skills. These tubes are placed while the patient is under general anesthesia, so it is important to ensure that the patient is stable for general anesthesia. Commercially available wet food diets can be used with these tubes. Many practitioners use a mouth gag when placing these tubes, but this is not advised as it can lead to compression of the maxillary artery. Complications are rare with these tubes but can include infection at the insertion site and esophageal irritation.

In some situations, enteral nutrition may not be the appropriate choice, including intractable vomiting, gastrointestinal conditions of severe malabsorption or maldigestion or ileus, and an inability to protect the patient's airway (along with a concern for vomiting). In situations where the patient's airway is unprotected, another option would be an enteral feeding tube lower in the gastrointestinal tract (i.e., a jejunostomy tube). Otherwise, parenteral nutrition can be considered, but a discussion of this modality is beyond the scope of this article.

Addressing nutritional needs is a crucial part of managing patients with critical illness. It is important to obtain a thorough diet history during the patient's presentation and develop a plan to provide nutrition early in the patient's hospitalization.

FURTHER READING:

Journal of Veterinary Emergency and Critical Care, Volume 16, Issue s1, 2006. This entire issue is dedicated to the topic of critical care nutrition.

Color Atlas of Canine Lymph Node Cytology

Patty Ewing, DVM, MS, DACVP (Anatomic and Clinical Pathology)
angell.org/lab | pathology@angell.org | 617-541-5014

Introduction

Lymph node fine-needle aspiration (FNA) cytology is a convenient, rapid, relatively inexpensive, and high-yield diagnostic procedure in dogs. Highly cellular aspirates are readily obtained in most cases. FNA of peripheral lymph nodes is performed for the following purposes: 1) diagnosis of inflammation, infectious disease, reactive hyperplasia, lymphoma, or metastatic neoplasia; 2) staging and monitoring relapse or treatment response in known malignancy such as lymphoma; and 3) obtaining samples for clonality, immunophenotyping or immunocytochemistry evaluations. This article will review common cytologic findings for canine peripheral lymph nodes that are easy to access by general practitioners without imaging modalities.

Normal Lymph Node

A normal lymph node is small and may be challenging to locate and/or aspirate. FNA may obtain only lipids and adipocytes if the lymph node is small. When adequate cellular samples are obtained from a normal lymph node, small, well-differentiated lymphocytes will account for at least 85% of the total nucleated cell population (see Figure 1). The remaining lymphoid cells (intermediate to large size) will account for <10% to 15% of the population.[1] Low numbers of plasma cells and macrophages are commonly found. Infrequent neutrophils, eosinophils, and mast cells may also be present in a normal lymph node.

Figure 2. Aspirates of reactive peripheral lymph nodes. Left. Note mixed lymphoid population with a predominance of small lymphocytes (black arrows), fewer large lymphoid cells/lymphoblasts (red arrows), and moderately increased numbers of plasma cells and Mott cells (green arrows). (Diff-Quik, 500x magnification) **Right.** Higher magnification view of another hyperplastic/reactive lymph node showing the appearance of a Mott cell (plasma cell with Russell bodies/immunoglobulin packets) compared to plasma cells without Russell bodies (yellow arrows). (Diff-Quik, 1000x magnification)

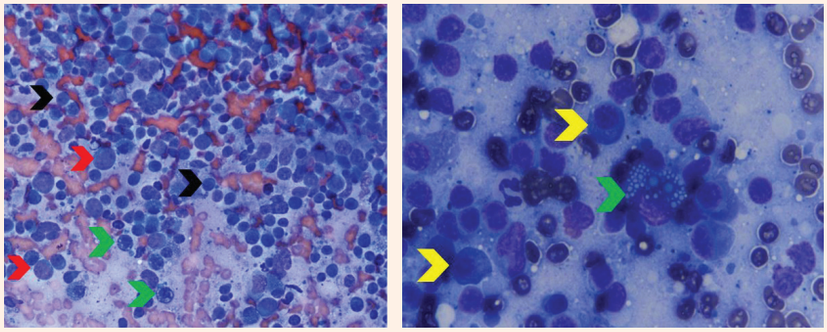

Reactive or Hyperplastic Lymph Node

A reactive or hyperplastic lymph node develops when antigens in sufficiently high concentration reach the draining lymph node and stimulate the immune system. Based on cytology alone, no definitive separation between a normal and reactive lymph node is evident. An enlarged lymph node is generally considered "reactive," even if the cellular composition is similar to that of a normal lymph node. However, in most instances, the proportion of intermediate to large lymphoid cells will be increased to greater than 15%, and plasma cells will be increased to greater than 5% of the nucleated cell population in some areas of the smear[2] (see Figures 1 and 2). Plasma cells will occasionally contain Russell bodies (see Figure 2), which are immunoglobulin packets (referred to as Mott cells). Immature plasma cells or lymphocytes transforming into plasma cells may be observed. Macrophages may represent greater than 2% of the nucleated cell population (see Figure 1).

Figure 1. Aspirates from a normal popliteal lymph node (left) and reactive prescapular lymph node (right). Left. Greater than 85% of lymphoid cells are small lymphocytes (black arrows), and less than 5% are large lymphoid cells/lymphoblasts (red arrows). The green arrow identifies a plasma cell that can be present in low numbers in normal lymph nodes (Wright-Giemsa, 750x magnification) **Right.** The hyperplastic/reactive lymph node has a mixed lymphoid population with a predominance of small lymphocytes (black arrow), fewer large lymphoid cells/lymphoblasts (red arrow), moderately increased numbers of plasma cells (green arrows), and mildly increased neutrophils (yellow arrows) and macrophages (blue arrow). The orange arrow with a blue outline identifies a lymphoglandular body, a cytoplasm fragment from a ruptured lymphocyte. They can be found in both reactive lymph nodes and lymph nodes with lymphoma. (Diff-Quik, 600x magnification)

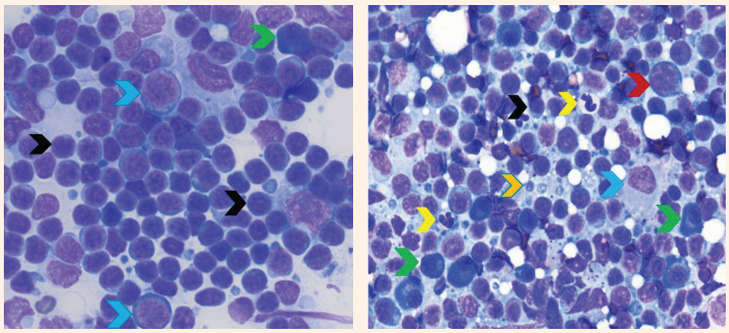

Lymphadenitis

Inflammation of the lymph node, known as lymphadenitis, may be primary or secondary (lymph node draining a site of inflammation). Inflammatory cells may include neutrophils, eosinophils, macrophages, or a combination of these cell types. If macrophages are epithelioid or multinucleated giant type, the inflammation is designated as granulomatous.[1] Table 1 outlines differential diagnoses that should be considered

Color Atlas of Canine Lymph Node Cytology

CONTINUED FROM PAGE 13

with specific types of inflammation in the lymph node. When lymphadenitis is identified, a diligent search for bacterial, fungal, and protozoal organisms is warranted (see Figure 3). Additional testing for infectious disease may include culture, PCR, and/or serology.

Table 1. Differentials for Lymphadenitis by Cell Type

Predominant inflammatory cell type	Differential Diagnoses
Neutrophilic	Bacterial Immune-mediated disease Inflammation associated with neoplasia, vasculitis, cutaneous ulceration, trauma, or tissue necrosis
Eosinophilic	Allergic/hypersensitivity disorders Hypereosinophilic syndrome Paraneoplastic syndrome (lymphoma, mast cell tumor, and carcinoma)
Granulomatous/Pyogranulomatous	Immune-mediated disease Foreign body reaction Mycobacteriosis Protozoal (Leishmaniasis, Toxoplasmosis) Salmon poisoning disease (Neorickettsia helminthoeca) Pythiosis Protothecosis Fungal (Blastomycosis, Histoplasmosis, Cryptococcosis, Coccidioidomycosis)

Figure 3. Aspirates of lymph nodes with lymphadenitis and infectious agents (blastomycosis-left; leishmaniasis-right). Left. Note relatively few lymphocytes (black arrows) and high numbers of neutrophils blue arrows) and macrophages (green arrows). The yellow arrows identify *Blastomyces* dermatitidis yeast. Note the yeast are approximately 10 to 20 microns, dark blue with a thick wall and thin, non-staining capsule. (Diff-Quik, 500x magnification) **Right.** Note mixed lymphoid population and numerous small purple "parachute"-shaped *Leishmania* spp. amastigotes are present within the cytoplasm of a macrophage and free within the background (yellow arrows). (Diff-Quik, 1000x magnification)

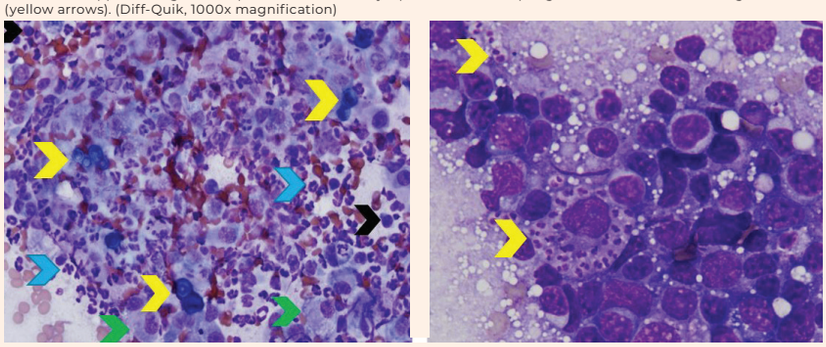

Lymphoma

Cytologic evaluation of lymph node aspirates is usually sufficient for diagnosing the majority of canine lymphomas. Aspiration of popliteal and prescapular lymph nodes is preferred over mandibular lymph nodes when generalized lymphadenopathy is present because mandibular lymph nodes are frequently enlarged and reactive due to constant exposure to antigens.[2] A lymphoma diagnosis can often reliably be made when more than 50% of the lymphoid population comprises immature lymphoid cells (see Figure 4). Greater certainty of a lymphoma diagnosis is made when 80% or more of the lymphoid cells are immature lymphoid cells.[1] A lymphoma diagnosis is easiest to make when the immature cells are medium and large in size (1.5 to 3 times or more than RBCs) with finely granular (dispersed) chromatin and visible nucleoli. Mitotic figures may be more numerous than seen in reactive lymph nodes, but this finding alone is not a reliable indicator of malignancy. This morphologic type of high-grade lymphoma consisting of immature medium to large lymphoid cells accounts for the majority of lymphomas in dogs, but up to 20% are small cell lymphomas.[1] Lymph nodes with small cell or indolent lymphoma or those with an early lymphoma cell infiltrate (<50% of lymphoid cells are immature) are more challenging to diagnose cytologically and often require additional diagnostic evaluations (flow cytometry, PCR for assessment of clonality, or histopathology and immunophenotyping). A retrospective study of indolent lymphomas reported that a distinctive form of a small-cell subtype of T-cell lymphoma, designated T-zone lymphoma, comprises up to 61.7% of canine indolent small-cell lymphomas. T-zone lymphoma is most commonly observed in Golden Retrievers and Maltese dog breeds but can occur in many others as well as mixed breeds.[3] Consider submission to a pathologist for confirmation.

Metastatic Neoplasia

Metastatic neoplasia is suspected when cell types not normally present in lymph nodes or excessive numbers of cell types normally present (such as mast cells) are identified in lymph node aspirates. Neoplastic cells are usually obtained if metastasis has progressed to cause clinically enlarged lymph nodes; however, small foci in normal-sized lymph nodes may be missed on aspiration.[1] The sensitivity of detecting low numbers of metastatic cells may be increased by using molecular techniques to detect the presence of tumor antigen mRNA.[4] The most common types of metastatic neoplasia observed in canine lymph nodes at Angell Animal Medical Center include mast cell neoplasia, carcinoma, and malignant melanoma.

Distinguishing between a benign mast cell population and mast cell tumor neoplasia can sometimes be challenging. One study found that mast cell tumor metastasis is most commonly observed in patients with lymph node enlargement, mast cell clustering (three or more aggregating mast cells), or the presence of mast cells with atypical morphology (see Figure 5).[5] More than 3% of mast cells should also raise suspicion of mast cell tumor metastasis.

One study found that detection of metastatic melanoma to regional lymph nodes via FNA can be highly sensitive (92%) but was influenced by several factors, including the use of immunostains, lymph node location, and lesion location.[6] Metastatic melanoma cells may be poorly or sparsely pigmented (see Figure 5), making confirmation of melanocytic origin challenging. Additionally, melanocyte pigment should not be confused with that in melanophages with phagocytized melanin pigment originating from lesions drained by the lymph node. Neoplastic melanocytes usually have less cytoplasmic volume and less vacuolated cytoplasm than melanophages. Hemosiderin, bile, carbon, and other pigments in macrophages may be confused with melanin.[1] Immunocytochemistry using a marker such as Melan-A may help confirm a diagnosis of metastatic amelanotic melanoma.[2]

Carcinomas frequently metastasize to lymph nodes. Metastatic epithelial cells may occur singly or in cohesive aggregates (see Figure 6). They are often large polygonal cells that bear no resemblance to cellular components of reactive or hyperplastic lymph nodes and, thus are relatively easy to identify.[1]

Color Atlas of Canine Lymph Node Cytology

CONTINUED FROM PAGE 14

Figure 4. Aspirates from lymph nodes with high-grade B cell lymphoma (left) and low-grade (T-zone) lymphoma (right). Left. Greater than 80% of cells are atypical medium to large lymphoid cells with dispersed chromatin and multiple prominent nucleoli (red arrows). Note the size of large lymphoid cells relative to small lymphocytes (black arrows) and neutrophils (yellow arrow). The green arrow identifies a mitotic figure. Immunophenotyping confirmed B cell origin. (Diff-Quik, 600x magnification) **Right.** Note that >85% of cells are morphologically distinct small-sized lymphocytes with round nuclei, loosely clumped chromatin, and increased amounts of pale blue cytoplasm, often extending from one pole of the cell in a hand mirror configuration (yellow arrows). Immunophenotyping by flow cytometry confirmed T-zone lymphoma. (Diff-Quik, 500x magnification)

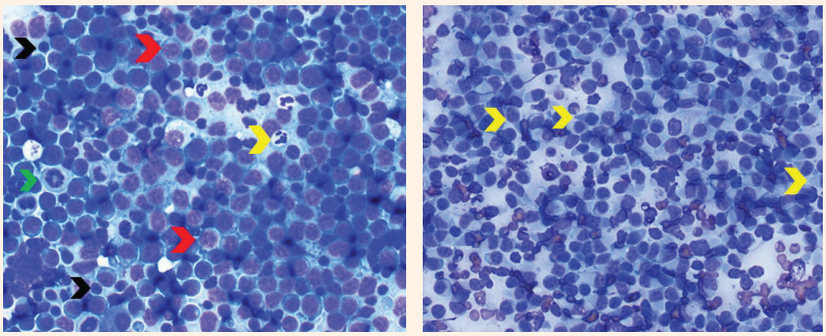

Figure 5. Aspirates of lymph nodes with metastatic amelanotic melanoma (left) and mast cell neoplasia (right). Left. Note the paucity of lymphocytes (black arrows) and numerous neoplastic large round or pyriform-shaped cells with large round to oval nuclei with stippled chromatin and multiple irregular nucleoli of variable size (red arrows). A low proportion of neoplastic cells have fine dark green pigment (melanin) in their cytoplasm (yellow arrows). (Diff-Quik, 750x magnification) **Right.** Note numerous sparsely granulated mast cells (yellow arrows) exhibiting marked morphologic atypia (large round nucleus, one or multiple large rounds to irregular nucleoli, moderate anisocytosis, and anisokaryosis) among mixed lymphoid cells (black arrows). The green arrow identifies a plasma cell, and the red arrows identify eosinophils. (Diff-Quik, 750x magnification)

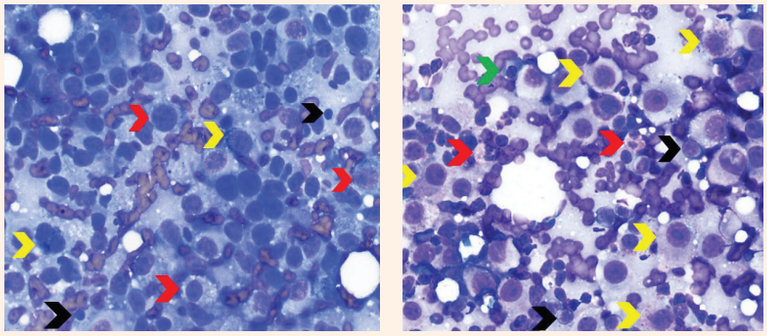

Figure 6. Metastatic squamous cell in mandibular lymph node (left) and metastatic anal sac adenocarcinoma in inguinal lymph node (right). Left. Note singly occurring very large polygonal epithelial cells (yellow arrows) exhibiting morphologic atypia (one or two oval nuclei with multiple irregular nucleoli, moderate anisocytosis and anisokaryosis, and large vacuoles in the cytoplasm) among numerous mixed lymphoid cells. Black arrows identify small lymphocytes. Red arrows identify large lymphoid cells/lymphoblasts. Green arrows identify neutrophils. (Diff-Quik, 500x magnification) **Right.** Note the absence of lymphoid cells, which may occur when neoplastic cells replace lymph node parenchyma. Yellow arrows identify cohesive aggregates of polygonal to round epithelial cells. Some of the neoplastic epithelial cells are forming acini (black arrows) (Wright-Giemsa, 750x magnification)

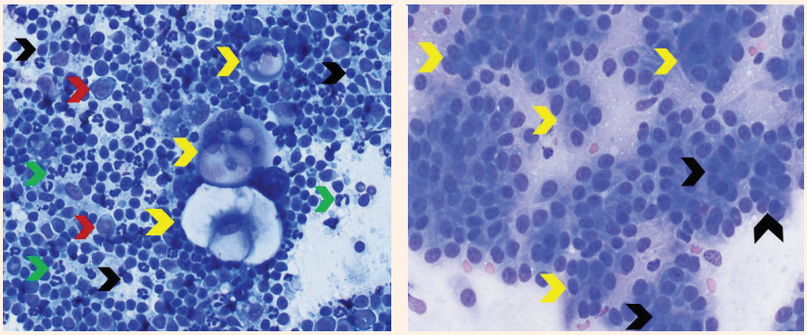

Spindle-cell sarcomas metastasize to lymph nodes less commonly than carcinomas and mast cell tumors. They are the most difficult to recognize because of their individualized cell presentation and overlap in appearance with reparative fibroblasts that may be present in lymph nodes.[2] The finding of anaplastic spindle cells exhibiting marked morphologic atypia can support a diagnosis of metastatic spindle-cell sarcoma.

Summary

Cytologic evaluation of canine peripheral lymph nodes is frequently rewarding due to the ease of sample collection, affordability, and high diagnostic yield. With practice and experience, cytologic differentiation of lymphoid hyperplasia, lymphoma, lymphadenitis, and metastatic neoplasia is achievable in many cases.

REFERENCES

1. Valenciano, A and Cowell R: Cowell and Tyler's Diagnostic Cytology and Hematology of the Dog and Cat, 5th edition. St. Louis, MO: Elsevier, 2020, p. 171-181.
2. Raskin R and Meyer D: Canine and Feline Cytology—A Color Atlas and Interpretation Guide, 2nd edition. St. Louis, MO: Saunders Elsevier, 2010, p. 77-104.
3. Seelig D, Webb T, Avery P, Avery A. Canine T-zone lymphoma: unique immunophenotypic features, outcome and population characteristics. *JVIM*. March, 2014;28(3).
4. Zavodovskaya R, Chein MB, London CA. Use of kit internal tandem duplications to establish mast cell tumor clonality in 2 dogs. *JVIM* 2004:18(6):915-917.
5. Kirk EL, et al. Cytological lymph node evaluation in dogs with mast cell tumors: association with grade and survival. *Vet Comp Oncol*. 2009;7(2):130-138.
6. Doubrovsky A. et al. Diagnostic accuracy of fine needle biopsy for metastatic melanoma and its implication for patient management. *Ann Surg Oncol*. 2008;15(1):323-332.

Angell Fall 2023 Continuing Education

Save the dates for our next webinars.

Sunday, October 22, 2023
8:15am – 2:45pm
Live Webinar
5 CE Credits *(pending RACE approval)*

SPEAKERS:

- **Shawn Kearns, DVM, DACVIM-SA** *(Internal Medicine)*
- **Ashley Lockwood, DVM, DACVECC-SA** *(Emergency and Critical Care)*
- **Klaus Loft, DVM** *(Dermatology)*
- **Jennifer Peterson-Levitt, DVM, DACVS-SA (Surgery)**

Wednesday, November 1, 2023
6:15pm –8:45pm
Live Webinar
2 CE Credits *(pending RACE approval)*

SPEAKERS:

- **Maureen Carroll, DVM, DACVIM-SA** *(Internal Medicine)*
- **Martin Coster, DVM, MS, DACVO** *(Ophthalmology)*



JOIN US FOR A LIVE, INTERACTIVE WEBINAR!
For more information, please visit **angell.org/ce**

↘ Angell Offers Low-Cost, Need-Based Clinics

Angell at Essex (Danvers, MA) and **Angell at Nashoba** (Westford, MA) clinics are dedicated to providing quality care to the general public as well as offering deeply-discounted services for qualified low-income families. The clinics provide primary veterinary care, spay/neuter services, vaccinations, and surgery and dental services.

The clinics do not provide overnight care, specialty service care, or 27/4 emergency care. Appropriate cases will be referred to Angell's Boston or Waltham facilities or a surrounding specialty veterinary referral hospital.

To see if your clients qualify for financial assistance, please visit **angell.org/essex** or **angell.org/nashoba**

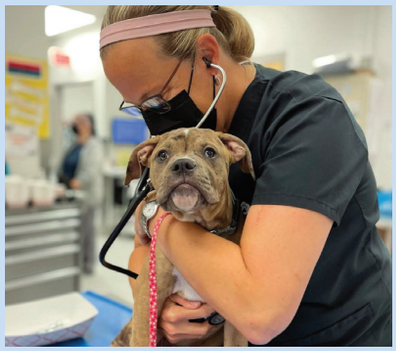

angell® at nashoba

To schedule an appointment with the Angell at Nashoba clinic, please call **978-577-5992**.

angell® at essex

To schedule an appointment with the Angell at Essex clinic, please call **978-304-4648**.

Angell at Nashoba on campus at Nashoba Valley Technical High School (Westford, MA).

Angell at Essex on campus at Essex North Shore Agricultural and Technical School (Danvers, MA).

↘ MSPCA-Angell Clinics in Boston, Methuen, and on Cape Cod

Offering subsidized veterinary care to help keep pets and families together.

The clinics provide spay/neuter services as well as acute outpatient surgical care, but they do not provide primary, overnight, or emergency veterinary care. The clinics are meant for families who cannot afford urgent medical care and are faced with a painful choice between euthanasia, surrender, or bringing an animal home against medical recommendations. By providing subsidized, low-cost veterinary care, the clinic provides a new pathway for families in need. We welcome your referrals to our clinics.

mspca angell® clinic

Boston | Cape Cod | Nevins Farm

MSPCA-Angell Cape Cod and Boston
Monday – Friday, 8am-4pm

MSPCA-Angell Nevins Farm in Methuen
Monday – Saturday, 8am-4pm



To refer low-income clients, please visit angell.org/referrals

MSPCA-Angell Clinic Boston: 617-541-5007 | MSPCA-Angell Clinic Cape Cod: 508-815-5226 | MSPCA-Angell Clinic Nevins Farm: 978-379-6605

STAFF DOCTORS AND RESIDENTS

■ We encourage you to contact Angell's specialists with questions.

Main Phone: 617-522-7282 (Boston) | Main Phone: 781-902-8400 (Waltham) | Veterinary Referrals: 617-522-5011
Angell at Nashoba: 978-577-5992 | Angell at Essex: 978-304-4648

CHIEF OF STAFF

Ann Marie Greenleaf, DVM, DACVECC
agreenleaf@angell.org

24-HOUR EMERGENCY & CRITICAL CARE MEDICINE, BOSTON

Alison Allukian, DVM
aallukian@angell.org

Laura Badeski, DVM
lbadeski@angell.org

Kiko Bracker, DVM, DACVECC
Service Director
kbracker@angell.org

David Carabetta, DVM, DACVECC
dcarabetta@angell.org

Callie Cazlan, DVM
ccazlan@angell.org

Elton Chan, DVM
echan@angell.org

Sara Doyle, DVM
sdoyle@angell.org

Rose Feldman, VMD
rfeldman@angell.org

Scout Ford, VMD
sford@angell.org

Molly Graham, DVM
mgraham@angell.org

Hana Huff, DVM
hhuff@angell.org

Audrey Koid, DVM, DACVECC
akoid@angell.org

Brandi Lauer, DVM
blauer@angell.org

Katherine McKean, DMV
kmckean@angell.org

Patrick Odom, DVM
podom@angell.org

Abbey Petronzio, DVM
apetronzio@angell.org

Nathalie Suciu, DVM
nsuciu@angell.org

Julia VanDerslice, DVM
jvanderslice@angell.org

Sam Vitali, DVM
svitali@angell.org

Megan Whelan, DVM, DACVECC, CVA
Chief Medical Officer
mwhelan@angell.org

24-HOUR EMERGENCY & CRITICAL CARE MEDICINE, WALTHAM

Jordana Fetto, DVM
jfetto@angell.org

Mina Gergis, DVM
mgergis@angell.org

Ashley Lockwood, DVM, DACVECC
alockwood@angell.org

Amanda Lohin, DVM
alohin@angell.org

Courtney Peck, DVM, DACVECC
Chief Medical Officer, Waltham
cpeck@angell.org

Lena Seegars, DVM
lseegars@angell.org

Jessica Seid, DVM
jseid@angell.org

Catherine Sumner, DVM, DACVECC
Chief of Staff, Waltham
csumner@angell.org

ANESTHESIOLOGY

Sandra Allweiler, DVM, DACVAA, CMVA, CCRT
sallweiler@angell.org

Kate Cummings, DVM, DACVAA
kcummings@angell.org

Becca Reader, BA, DVM, DACVAA
rreader@angell.org

AVIAN & EXOTIC MEDICINE (W/B)

Elena Buernrostro, DVM
ebuernrostro@angell.org

Brendan Noonan, DVM, DABVP (Avian Practice)
bnoonan@angell.org

Elisabeth Simone-Freilicher DVM, DABVP (Avian Practice)
esimonefreilicher@angell.org

Anne Staudenmaier, VMD, DABVP (Avian Practice)
(Waltham)
astaudenmaier@angell.org

Patrick Sullivan, DVM, DABVP (Avian Practice)
psullivan@angell.org

BEHAVIOR (W/B)

Terri Bright, PhD, BCBA-D, CAAB
tbright@angell.org

CARDIOLOGY

Alice Chirn, MA, BVetMed
achirn@angell.org

Katie Hogan, DVM, DACVIM (Cardiology)
khogan@angell.org

Clint Lynn, DVM
clynn@angell.org

Michelle Oranges, DVM
moranges@angell.org

Jordan Vitt, DVM, DACVIM (Cardiology)
jvitt@angell.org

DENTISTRY

Jessica Riehl, DVM, DAVDC
jriehl@angell.org

Joyce Tai, DVM, MS
jtai@angell.org

DERMATOLOGY (W/B)

Klaus Loft, DVM
kloft@angell.org

Meagan Painter, DVM, DACVD
(Waltham)
mpainter@angell.org

Brooke Simon, DVM
bsimon@angell.org

DIAGNOSTIC IMAGING (W/B)

Naomi Ford, DVM, DACVR
nford@angell.org

Steven Tsai, DVM, DACVR
stsai@angell.org

Ruth Van Hatten, DVM, DACVR
rvanhatten@angell.org

INTERNAL MEDICINE (W/B)

Nyla Bent, DVM
nbent@angell.org

Douglas Brum, DVM
dbrum@angell.org

Maureen Carroll, DVM, DACVIM
mccarroll@angell.org

Zach Crouse, DVM, DACVIM
zcrouse@angell.org

Lisa Gorman, DVM, DACVIM
(Waltham)
lgorman@angell.org

Jessica Hayes, DVM
jhayes@angell.org

Shawn Kearns, DVM, DACVIM
skearns@angell.org

Evan Mariotti, DVM, DACVIM
emariotti@angell.org

Susan O'Bell, DVM, DACVIM
Service Director
sobell@angell.org

Juliana Picard, DVM
jpicard@angell.org

Ursula Ramalho, DVM
uramalho@angell.org

Annie Sheu-Lee, DVM
asheulee@angell.org

Lindsey Summers, DVM
lsummers@angell.org

Daniela Vrabelova Ackley DVM, DACVIM
(Waltham)
dvrabelova@angell.org

STAFF DOCTORS AND RESIDENTS

CONTINUED FROM PAGE 18

NEUROLOGY

Rob Daniel, DVM, DACVIM (Neurology)
rdaniel@angell.org

Michele James, DVM, DACVIM (Neurology)
mjames@angell.org

Jennifer Michaels, DVM, DACVIM (Neurology)
jmichaels@angell.org

ONCOLOGY

Kristine Burgess, DVM, MLA, DACVIM (Medical Oncology)
kburgess@angell.org

Megan Cray, VMD, DACVS (Surgical Oncology)
mcray@angell.org

Kendra Lyons, DVM (Medical Oncology)
klyons@angell.org

Jillian Walz, DVM, DACVIM (Medical Oncology) , DACVR (Radiation Oncology)
jwalz@angell.org

OPHTHALMOLOGY

Daniel Biros, DVM, DACVO
dbiros@angell.org

Martin Coster, DVM, MS, DACVO
mcoster@angell.org

PATHOLOGY (CLINICAL & ANATOMIC)*

Patty Ewing, DVM, MS, DACVP
pewing@angell.org

Pamela Mouser, DVM, MS, DACVP
pmouser@angell.org

SURGERY (W/B)

Lori Agulian, DVM
(Waltham)
lagulian@angell.org

Kristen Behrens. DVM
kbehrens@angell.org

Sue Casale, DVM, DACVS
scasale@angell.org

Caroline Choi, DVM
cchoi@angell.org

Kathryn Heidgerd, VMD
kheidgerd@angell.org

Michael Pavletic, DVM, DACVS
mpavletic@angell.org

Jennifer Peterson-Levitt DVM, DACVS-SA
(Boston & Waltham)
jpetersonlevitt@angell.org

Nicholas Trout MA, VET MB, DACVS-SA, ECVS
ntrout@angell.org

URGENT CARE BY APPOINTMENT ONLY, WALTHAM

Natasha Pakravan, DVM
npakravan@angell.org

ANGELL AT ESSEX

Heidi Broadley, DVM
hbroadley@angell.org

Sara Gardiner, DVM
sgardiner@angell.org

ANGELL AT NASHOBA

Mary-Kate O'Toole, DVM
mkotoole@angell.org

Laurence Sawyer, DVM
lsawyer@angell.org

(W/B) Services also available at our Waltham location
*Boston-based pathologists and radiologists serve both Boston and Waltham locations
**Available only in Waltham

↘ Courtesy Shuttle for Patients Needing Further Specialized Care

Angell Animal Medical Center offers the convenience of our MSPCA-Angell West facility in Waltham, MA. The Waltham facility offers Urgent Care and specialized service appointments. If needed, an oxygen-equipped courtesy shuttle can transport animals to Boston for further specialized care and then return them to Waltham. Whether in Boston or in Waltham, our specialists regularly collaborate and plan treatments tailored to our patients' emergency, surgical, and specialty needs.

WE OFFER A BROAD RANGE OF EXPERTISE AND DELIVER THIS CARE WITH THE ONE-ON-ONE COMPASSION THAT OUR CLIENTS AND PATIENTS DESERVE.

angell®
animal medical center

Nonprofit Org.
US Postage
PAID
Permit No. 1141
Boston, MA

We mail one complimentary copy of our newsletter to each of our referring partners. Please circulate this copy within your practice.

Summer 2023 | angell.org | facebook.com/mspcaangell

MSPCA-ANGELL
350 South Huntington Avenue
Boston, MA 02130
617-522-5011
angell.org

MSPCA-ANGELL WEST
293 Second Avenue
Waltham, MA 02451
781-902-8400
angell.org/waltham

ANGELL AT ESSEX
565 Maple Street
Danvers, MA 01923
978-304-4648
angell.org/essex

ANGELL AT NASHOBA
100 Littleton Road
Westford, MA 01886
978-577-5992
angell.org/nashoba

MSPCA-ANGELL CLINICS
Boston | Cape Cod | Methuen
angell.org/clinics

ANGELL.ORG/DIRECTIONS (FREE PARKING) | ANGELL.ORG/HOURS | ANGELL.ORG/CE

Please consider adding Angell's main numbers to your after-hours phone message.

Our Service Locations

BOSTON & WALTHAM	BOSTON ONLY
Avian & Exotic Medicine 617-989-1561	**Anesthesiology** 617-541-5048
Behavior 617-989-1520	**Cardiology** 617-541-5038
Dermatology 617-524-5733	**Dentistry** 617-522-7282
Diagnostic Imaging 617-541-5139	**Neurology** 617-541-5140
Internal Medicine 617-541-5186	**Oncology** 617-541-5136
Surgery 617-541-5048	**Ophthalmology** 617-541-5095
Urgent Care* 781-902-8400	**Pathology** 617-541-5014

*Available only in Waltham

24/7 Emergency & Critical Care | Boston: 617-522-5011 | Waltham: 781-902-8400