

We encourage you to email Angell's specialists with questions. We hope you will use Angell as a resource and we look forward to working with you as we continue our legacy of providing compassion and care to animals.

**350 South Huntington Ave.  
Boston, MA 02130  
Main Phone: 617 522-7282  
Veterinary Referrals:  
617 522-5011**

**Chief of Staff**

**Ann Marie Manning, DVM, DACVECC**  
amanning@angell.org

**Avian & Exotic Animal  
Medicine**

**Connie J. Orcutt, DVM, DABVP-Avian**  
corcutt@angell.org

**Jennifer E. Graham, DVM,  
DABVP-Avian, DACZM**  
jgraham@angell.org

**Cardiology**

**Nancy J. Laste, DVM, DACVIM**  
nlaste@angell.org

**Rebecca L. Malakoff, DVM, DACVIM**  
rmalakoff@angell.org

**Clinical & Anatomical  
Pathology**

**Patty Ewing, DVM, DACVP**  
pewing@angell.org

**Dentistry**

**William Rosenblad, DVM**  
wrosenblad@angell.org

**Curtis A. Stiles, DVM**  
cstiles@angell.org

**Dermatology**

**Kathy Tater, DVM, DACVD**  
kctater@angell.org

**Diagnostic Imaging**

**Kathy A. Beck, DVM, DACVR**  
kbeck@angell.org

**Jessica Basseches, DVM, DACVR**  
jbasseches@angell.org

**Joan Regan, VMD, DACVR**  
jregan@angell.org

**Emergency & Critical  
Care Medicine**

**Kiko Bracker, DVM, DACVECC**  
kbracker@angell.org

**Jennifer Holm, DVM, DACVECC**  
jholm@angell.org

**Catherine Rogers, DVM, DACVECC**  
crogers@angell.org

**Megan Whelan, DVM, DACVECC**  
mwhelan@angell.org

**Internal Medicine**

**Douglas Brum, DVM**  
dbrum@angell.org

**Maureen Carroll, DVM, DACVIM**  
mccarroll@angell.org

**Erika de Papp, DVM, DACVIM**  
edepapp@angell.org

**Jean Marie Duddy, DVM**  
jduddy@angell.org

**Shawn Kearns, DVM, DACVIM**  
skearns@angell.org

**Stephen Martinez, DVM**  
smartinez@angell.org

**Chris Rollings, DVM, DACVIM**  
crollings@angell.org

**Neurology**

**Debbie Ruehlmann, DVM,  
MS, DACVIM**  
druehlmann@angell.org

**Allen Sisson, DVM, MS, DACVIM**  
asisson@angell.org

**Nutrition**

**Rebecca L. Remillard, PhD, DVM,  
MS, DACVN**  
rremillard@angell.org

**Oncology**

**Christine Anderson, DVM, MS,  
DACVIM, DACVR**  
cranderson@angell.org

**Ophthalmology**

**Daniel J. Biros, DVM, DACVO**  
dbiros@angell.org

**Pain Medicine**

**Lisa Moses, VMD, DACVIM, CVMA**  
lmoses@angell.org

**Surgery**

**Michael M. Pavletic, DVM, DACVS**  
mpavletic@angell.org

**Sue Casale, DVM**  
scasale@angell.org

**David W. Knapp, DVM, DACVS**  
dknapp@angell.org

**Catherine J. Reese, DVM, DACVS**  
creese@angell.org

**Nicholas J. Trout, MA, VET MB,  
MRCVS, DACVS, DECVS**  
ntrout@angell.org

**Angell Animal Medical Center  
Referral Guide**

**Cardiology Service**

Referral Liaison: Robin Grammer  
Referral Line: 617 541-5038 Referral Fax: 617 989-1653  
Email: cardiology@mspca.org Web site: www.mspca.org/cardiology

**Dermatology Service**

Referral Liaison: Rebecca Stlaske  
Referral Line: 617 524-5733 Referral Fax: 617 989-1613  
Email: dermatology@mspca.org Web site: www.mspca.org/dermatology

**Neurology Service**

Referral Liaison: Lisa Canale  
Referral Line: 617 541-5140 Referral Fax: 617 989-1666  
Email: neurology@mspca.org Web site: www.mspca.org/neurology

**Oncology Service**

Referral Liaison: Gary Vanasse  
Referral Line: 617 541-5136 Referral Fax: 617 541-5130  
Email: oncology@mspca.org Web site: www.mspca.org/oncology

**Pain Medicine Service**

Referral Liaison: Lisa Canale  
Referral Line: 617 541-5140 Referral Fax: 617 989-1666  
Email: painmedicine@mspca.org Web site: www.mspca.org/painmedicine

**For all other referrals, please continue to call Eleanor Cousino,  
Angell Referral Coordinator at 617 522-5011.**

**Is your client new to Angell? Send them to  
www.mspca.org/directions for detailed directions to our location.**



350 South Huntington Avenue  
Boston, Massachusetts 02130

[www.mspca.org](http://www.mspca.org)

Nonprofit Org  
US Postage  
**PAID**  
Permit No. 56959  
Boston MA



**PARTNERSINCARE**

VOLUME THREE: NUMBER ONE

WINTER 2009

**Update: Pfizer Announces Changes to  
Popular Drug**

**P**fizer Animal Health is discontinuing the production and sale of Domitor (medetomidine) in the near future. In its place, the company is marketing Dexdomitor (dexmedetomidine).

While Domitor is a racemic mixture of 50% active molecules and 50% inactive molecules, Dexdomitor is composed entirely of active molecules. This means that Dexdomitor is roughly twice as potent as the same milligram dose of Domitor. Pfizer has made the concentration of Dexdomitor 0.5 mg/ml, in contrast to the concentration of Domitor at 1 mg/ml. This means that when you calculate a dose in mcg/kg and figure out the ml dose, it will be the same volume as if you were using Domitor. While this is easy for people who calculated their doses on a ml/kg basis (as listed on the bottle), it may be quite dangerous for those who calculate a mcg/kg dose.

Antesedan is still dosed in the same way: draw up the same volume of Antesedan as Dexdomitor and give to effect.

Please adjust all your sedation and anesthesia protocols using Domitor to reflect a 50% mcg dose reduction when switching over to Dexdomitor.

There are anecdotal reports that the sedation effects do not last as long when using Dexdomitor. If you do need to re-dose, be cautious about additional doses since the cardiovascular effects do not seem to be different.

**If you have any questions regarding the change in this drug, please contact Lisa Moses, VMD, DACVIM, CVMA of Angell's Emergency and Critical Care Unit and the Pain Medicine service. She can be reached by e-mail at [painmedicine@mspca.org](mailto:painmedicine@mspca.org).**

**Practice Tip: Dissolution Diets for Patients  
with Pancreatitis**

**Christine Willis, DVM of the Internal Medicine service**

Diets available for dissolution/management of canine uroliths (struvite and urate) are commonly higher in fat and have lower protein content (Hill's s/d, u/d and Royal Canin SO). On average, these diets contain 40–50% of their metabolizable energy content from fat and 5–15% from protein. Normal adult-maintenance dog foods contain approximately 30% of the metabolizable energy from fat; therefore, extra care should be used when prescribing these diets to overweight dogs or breeds already predisposed to pancreatitis (Miniature Schnauzers, Bichon Frises, Yorkshire Terriers, Malteses, Shelties, Chihuahuas, Jack Russell Terriers and Labrador Retrievers).

The feeding of a high-fat diet (more than 40% ME) can be associated with the onset of pancreatitis. Although no direct evidence is available to prove this association, several theories are proposed and clinical experience alludes to such a relationship. It is recommended that serum triglyceride levels be evaluated before initiating a dissolution diet. An obese, hyperlipidemic patient or a patient with a history of pancreatitis should probably not be fed this type of diet. For example, a potential alternative may include Hill's w/d, k/d or Purina NF plus potassium citrate or a tailored, homemade diet.

Should an animal develop pancreatitis while receiving a dissolution/management diet, the treatment remains the same: supportive care (IV fluids, anti-emetics and pain management) while withholding food. When it is appropriate to offer food, it should be of a lower fat content than before — a food with moderate fat (30% ME) could be fed rather than the more stringent low-fat (20% ME) options.

**To learn more about Angell's Internal Medicine service, please visit [www.mspca.org/internalmedicine](http://www.mspca.org/internalmedicine). To refer a patient, please contact Referral Coordinator Eleanor Cousino at 617 522-5011.**

**Combining  
Advanced  
Imaging with  
Cutting-Edge  
Medicine for  
Chronic Ear  
Cases**

**A** challenge in all chronic ear cases is identifying the extent of the ear condition. Advanced imaging through Bulla CT scans and video otoscopy are important tools in the comprehensive evaluation of a chronic ear case.

Bulla CT scans are an excellent way to evaluate the middle ears for otitis media and the canal walls for mineralization. Cases involving the middle ear often need to be managed differently than cases involving only the external ear canal. It is impossible to see into the middle ear without imaging if the bony tympanic bulla. Since the tympanic membrane is able to regrow after past rupture, visualizing an intact tympanic membrane is not a reliable way of ruling out middle ear disease. Imaging through a Bulla CT scan is also one of the best ways to differentiate otic mineralization from severe otic swelling. Since, unlike mineralization, soft tissue swelling is reversible with medication, knowing whether otic mineralization is present helps a clinician develop a long-term management plan. Imaging also aids in the evaluation of the tissue surrounding the ears. This can be important when an otic neoplasm or otitis media is diagnosed and the clinician is determining if the problem extends beyond the ear.

Video otoscopes are endoscopes specially fitted to evaluate the lumen and lining of the otic canal. Having an extremely bright light source that can fit within the canal, the video

**INSIDE**

- Avian & Exotics Case Study P2**
- Neurology & Neurosurgery Case Study P3**
- Angell Referral Guide P4**



**Kathy Tater, DVM, DACVD of  
Angell's Dermatology service.**

otoscope provides superior imaging of structures within the canal, compared to handheld otoscopes. This is especially helpful for identifying lesions in areas that would be poorly illuminated by handheld otoscopes, such as the deep, horizontal canal in a large dog.

For the diagnosis and management of chronic ear disease, the Angell Animal Medical Center offers the Angell Ear Clinic, a subspecialty clinic of the Angell Dermatology service. It was established in 2006 by Angell's board-certified Veterinary Dermatologist, Kathy Tater, DVM, DACVD. Through the Angell Ear Clinic, patients with chronic ear disease are seen by appointment on Thursday mornings. After an initial consultation, patients are admitted to our hospital and additional procedures are performed under anesthesia on the same day. Since most chronic ear cases have an underlying cause, a full evaluation of a pet's dermatologic condition is also provided.

# CASESTUDY

## Avian and Exotics

**Jennifer Graham, DVM, DABVP-Avian, DACZM**  
**Connie Orcutt, DVM, DABVP-Avian (Section Head)**  
**Michelle Nobrega-Lee, DVM (Resident)**

### PATIENT:

Eight-year-old intact male Umbrella Cockatoo named Chi-Chi

### PRESENTING COMPLAINT

Chi-Chi was presented to the Avian and Exotics service at Angell Animal Medical Center for a chronic cloacal prolapse that had been unresponsive to treatment (reduction followed by placement of transverse sutures). He had a history of chronic masturbatory behavior.



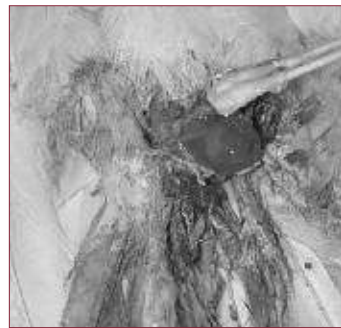Chi-Chi immediately after castration.

### PHYSICAL EXAMINATION

On examination, Chi-Chi was stable but had a cloacal prolapse. The prolapsed tissue was viable. Malodorous stool was noted during the exam, with fecal material matted on the feathers surrounding the vent.

### DIAGNOSIS/TREATMENT

A fecal Gram's stain revealed an increased number of spore-forming bacteria (likely secondary infection from the chronic prolapse). It was noted that previous diagnostics (blood work and radiographs) had been unremarkable. Based on the history, it was suspected that the prolapse was related to behavioral issues including the chronic masturbatory behavior (which is a fairly common condition in male Umbrella Cockatoos). It was determined that the best chance for resolving the chronic prolapse would be to castrate Chi-Chi, as well as perform a cloacopexy or ventplasty procedure. Castration is an extremely difficult procedure in birds as the testes are internal and closely adhered to the vena cava. Chi-Chi did well under anesthesia and the surgery was successful.



The cloacal prolapse in Chi-Chi.

### RECOVERY

On recovery, the prolapse was reduced and Chi-Chi was observed closely, to make sure he was able to pass feces through the smaller vent opening. In addition to antibiotics, he was also treated with butorphanol and meloxicam for pain management. Recovery was normal, and there were no post-operative complications. Chi-Chi was allowed to recover for two weeks, prior to a ventplasty (analogous to canthoplasty of the eyelids) to reduce the size of the vent opening and decrease the chance of future prolapse. During this time he was treated with antibiotics for management of the spore-forming bacteria, as well as to prevent peri-operative infection.

### KEY FACTORS

Cloacal prolapse in birds can be caused by a variety of etiologies. Possible causes for prolapse include:

- egg binding
- impaction
- chronic bacterial cloacitis
- chronic masturbatory behavior/sexual displays for owner
- neuropathy
- early weaning, causing infantile food solicitation behaviors

We recommend obtaining a thorough history to rule out behavioral causes for prolapsing. Initial diagnostics, including blood work, radiographs, fecal cytology and bacterial cultures may be necessary to rule out other underlying causes. Salpingohysterectomy in females and castration of males may be important adjunct treatments to reduction/treatment of the prolapse. However, these procedures are technically difficult and should only be performed by an avian specialist or someone with adequate knowledge and experience. Behavioral modification is a vital component of treatment, and behavioral modification drugs may be helpful in reducing the likelihood of prolapse recurrence. Owners should be aware that prognosis for complete resolution of the problem may be poor.

### ABOUT THE ANGELL ANIMAL MEDICAL CENTER'S AVIAN AND EXOTICS DEPARTMENT

The Avian and Exotics service at Angell Animal Medical Center treats approximately 4,000 animals each year. Small mammals and birds each make up about 45% of species treated by the department and about 10% of patients are reptiles.

**Drs. Graham, Orcutt and/or Nobrega-Lee are available seven days a week on a referral basis. In addition, avian and exotic patients are seen by the Emergency service at Angell Animal Medical Center after regular clinic hours.**

**To refer a client, please call Referral Coordinator Eleanor Cousino at 617 522-5011 or visit [www.mspca.org/avianandexotic](http://www.mspca.org/avianandexotic) for more information.**

CONTINUED FROM PAGE 1

### Combining Advanced Imaging with Cutting-Edge Medicine for Chronic Ear Cases

All Bulla CT scans for Angell Ear Clinic patients are reviewed by our team of specialists, Dr. Tater and one of Angell's three board-certified radiologists. Each video otoscopy procedure is performed by Dr. Tater to thoroughly clean the ear and view the interior of the canal. If otitis media are diagnosed, a culture sample from the bulla is obtained and a culture and sensitivity are performed by our on-site microbiology laboratory. Ear Clinic patients do not need to stay overnight in the hospital and most pets are able to be discharged that afternoon or evening.

**To refer a patient to the Angell Dermatology service's Ear Clinic, please call Dermatology secretary Rebecca Stlaske at 617 524-5733, Tuesday through Friday from 7:30 a.m. to 5:00 p.m. For more information about the service, please visit [www.mspca.org/dermatology](http://www.mspca.org/dermatology).**

# CASESTUDY

## NEUROLOGY & NEUROSURGERY

**Allen Sisson, DVM, MS, DACVIM**

### PATIENT:

Two-year-old, neutered, 210-pound English Mastiff named Jack

### HISTORY AND PRESENTING COMPLAINT

For one year, Jack's left fore and left pelvic limb occasionally knuckled or slipped to the side when walking. Forty-eight hours before presentation, he began to limp on his left forelimb. Twelve hours before presentation, he limped severely on the left forelimb and both pelvic limbs were unsteady. Jack was presented to the referring veterinarian a few hours later and frequently collapsed on all four legs; he could barely walk. By the time he arrived at the Angell Animal Medical Center later the same day, he was unable to stand or walk and was brought in on a stretcher.

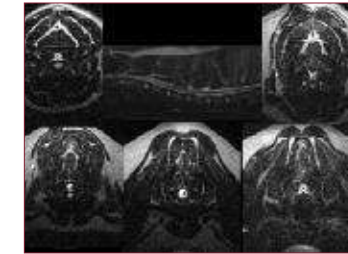
### PHYSICAL AND NEUROLOGICAL EXAMINATION

Jack's physical examination was normal. On neurological examination he was alert, responsive and friendly. Jack was able to maneuver into a sternal position unassisted and he could attempt to stand; however, he could not stand with all four legs. When his weight was fully supported by the examiners, he had purposeful gaiting movements in all four legs; however, he could not bear any weight on his limbs and the left thoracic limb was in a constant, fully knuckled posture. His cranial nerves were all normal. He had no conscious proprioception and no hopping ability in all four limbs. Jack's thoracic limb reflexes were absent and his pelvic limb reflexes were hyper-reflexic. His cervical spine was not painful on manipulation. These findings indicated a C1-T2 worse on the left spinal cord lesion, most likely C6-T2, due to the thoracic limb hyporeflexia. Differential diagnosis included cervical vertebral instability static or dynamic stenosis (Wobblers Syndrome), cervical intervertebral disc herniation, neoplasia, spinal cord hemorrhage or myelitis (immune mediated or infectious).

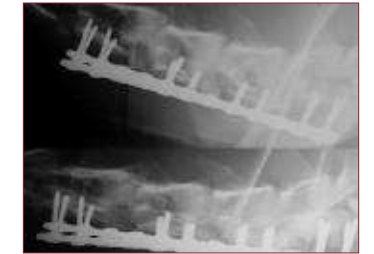### DIAGNOSIS/TREATMENT

Hemogram, serum general chemistry profile and urinalysis results were normal. Jack was anesthetized and an MRI of the cervical spine was performed. Articular facet degenerative osteoarthritis was identified at all cervical disc spaces. Significant cord compression was identified at C3-4, C4-5, C5-6 and C6-7. Articular facet lateral impingement was the greatest factor at C3-4 and C4-5; however, a large cystic lesion was identified on the right extending from C5-6 to C6-7, displacing the cord to the left side. This cystic structure was believed to be a synovial cystic lesion, associated with the articular facets. Articular facet degenerative change also contributed to narrowing of the canal at the C5-6 and C6-7 sites. There was no significant cord compression at C7-T1. However, mild degenerative change was present, associated with the articular facets at this site as well. Static stenosis cervical vertebral instability, secondary to articular facet osteoarthritis spinal cord compression (Wobblers syndrome) from C3 to C7, was diagnosed.

A ventral cervical approach was made from C3 to C7. Interbody bone cement plugs using methyl methacrylate were placed at all four intervertebral disc spaces where the spinal cord was compressed, while those sites were held in traction. As additional stabilization at the caudal three sites, two parallel, monocortical, bone screw locking plates were placed on either side of the ventral midline of vertebral bodies C4 to C7. A cancellous bone graft harvested from the right proximal humerus was placed ventral to the locking bone plates at all operated cervical sites.



Sagittal T2 weighted cervical MRI center. Clockwise from upper left: transverse (axial) views of C3-C4, C4-C5, C7-T1 (normal site), C6-C7, C5-C6.



Lateral immediately post-operative (top) and seven weeks post-operative (bottom) cervical radiographs showing interbody bone cement plugs and locking bone plates in place.

### RECOVERY

Jack recovered extremely well from surgery, with steady improvement in his ability to ambulate each day after surgery. Within 72 hours he was able to walk, using his front limbs normally. One week post-operatively, he could walk using all four legs without assistance. Ten days post-operatively, he had recovered enough strength to go home, walking unassisted but with significant pelvic limb ataxia. Jack returned to Angell for a follow-up examination and cervical radiographs seven weeks post-operatively. On examination he was able to stand and walk unassisted with a normal thoracic limb gait and only very mild pelvic limb ataxia, occasionally scuffing the left pelvic limb nails and crossing over the pelvic limbs slightly on turns. Cervical radiographs taken at that time found all the implants remained well in place. The owners reported that by two-and-a-half months post-surgery, Jack's gait was normal and he was very active, running and going up and down stairs without restrictions. It has now been nine months since surgery and he continues to do well.



Jack at home, eight months post-operative.

**Angell Animal Medical Center's Neurology/Neurosurgery service is open from 8:00 a.m. to 5:00 p.m., Monday through Saturday. Patients are seen by appointment and through referral by their primary veterinarian. Appointments and referrals are made by calling the Neurology secretary at 617 541-5140.**

### In Memoriam

It is with great sadness that we share the news that Dr. Sharon Drellich of Angell's Emergency and Critical Care Unit passed away on December 19, 2008. She fought a long, courageous battle with cancer. She was not only an extremely talented veterinarian, but a true role model as she maintained a positive attitude every day despite her illness.

Sharon was a graduate of Tufts University School of Veterinary Medicine. She completed an internship in small animal medicine and surgery at the Animal

Medical Center in New York. From there, she completed her residency in emergency and critical care medicine at the University of California. She became board certified by the American College of Veterinary Emergency and Critical Care in 2000.

That same year, Sharon began working at Angell. She took on the role of Angell's Internship Director, and oversaw the clinical education of new veterinarians as they rotated through all of Angell's specialty services. She will be greatly missed by the staff and her clients.