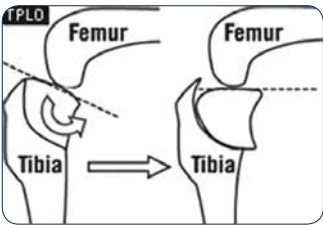


Cranial Cruciate Ligament Injuries: What Do I Do?



By Cathy Reese,
DVM, DACVS

Cranial cruciate ligament injuries are one of the most common orthopedic conditions that we see. We perform several cruciate ligament repair surgeries daily at Angell. It is also one of the most hotly debated topics in the orthopedic community, as it is still questionable as to what is the best surgical repair for this injury. While no one has the definitive answer to that question, I can tell you what I tell owners and how we decide which surgery is the best for their individual pet.

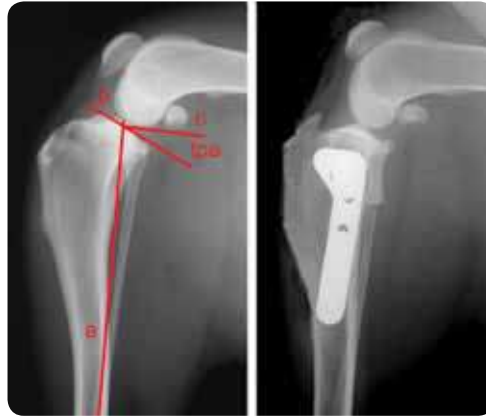

➤ TPLO diagram.

At Angell, we offer three different methods of surgical repair for cranial cruciate ligament injuries: the extracapsular lateral fabellotibial suture method, the tibial plateau

leveling osteotomy (TPLO), and the tibial tuberosity advancement (TTA). There are numerous other surgical techniques, too, such as the fibular head transposition, the Tightrope extracapsular repair, the cranial tibial wedge osteotomy, the proximal tibia intra-articular osteotomy, and the triple tibial osteotomy, but we do not perform these at Angell. Which method of repair we perform is based upon the dog's size, age, and activity level; owner's opinion; and sometimes finances.

The extracapsular lateral fabellotibial suture method, or "lateral suture" method, has been the gold standard for cranial cruciate ligament repair since Dr. Gretchen Flo first described the Modified Retinacular Imbrication Technique (MRIT) in 1975. The lateral suture method is a modification of the MRIT in which only lateral fabellotibial sutures



➤ Radiographs of a TPLO.

The TPLO was described by Dr. Barclay Slocum in 1993. It functionally stabilizes the stifle during weight-bearing by eliminating cranial tibial thrust or cranial tibiofemoral shear force through reduction of the tibial plateau angle (TPA).

are placed, as opposed to medial and lateral fabellotibial sutures as done in the MRIT. I usually recommend the lateral suture technique for small dogs, cats, and geriatric/inactive dogs. I have had success with this technique in large-breed dogs as well, so it should not be ruled out as a choice for repair in these patients, especially if the owner has financial constraints. The concern with doing the lateral suture repair in a large-breed or active dog is that the repair is not sturdy enough, but with appropriate exercise restriction and post-operative rehabilitation, it can be very successful.

The TPLO was described by Dr. Barclay Slocum in 1993. It functionally stabilizes the stifle during weight-bearing by eliminating cranial tibial thrust or cranial tibiofemoral shear force through reduction of the tibial plateau angle (TPA). A radial osteotomy is made of the proximal tibia, and the proximal fragment is rotated until the TPA is

> Continued on Page 3

Inside

Non-healing Superficial Corneal Ulcers in Dogs	2
Canine Sino-nasal Aspergillosis	3
Drug Shortages and Recalls: Why Do They Happen So Often?	5
The Technician's Corner: Handheld Ultrasound for Cystocentesis	5
Referral Contact Information	7

Courtesy Consultations

We encourage our referring veterinary partners to call or e-mail our Angell specialists to consult on difficult cases.

Angell specialists are available for consultation Monday–Friday 9:00 a.m.–5:00 p.m.

Additionally, Angell emergency doctors are available for consultation on weekends and after hours (7:00 a.m.–11:00 p.m.).

Please see Page 7 and the back cover of this newsletter for full contact information.

Online Referral Forms

Please visit angell.org/referrals

Non-healing Superficial Corneal Ulcers in Dogs



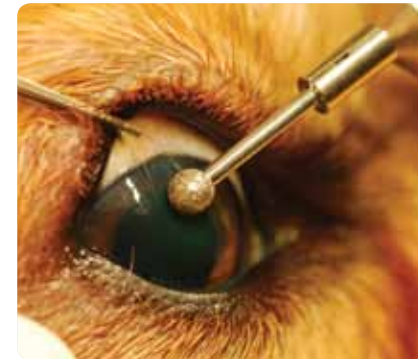By Dan Biros,
DVM, DACVO

Otherwise known as spontaneous chronic corneal epithelial defects (SCCEDs), these clinical cases often frustrate the clinician because the normal wound-healing process for superficial corneal ulcers is thwarted, and often the affected dogs have prolonged periods of discomfort and in some cases progressive keratitis despite aggressive medical treatment. Other names for this condition include Boxer ulcers, non-healing erosions, persistent corneal erosions, indolent ulcers, or idiopathic persistent corneal erosions. While recognized frequently in Boxers, almost all canine breeds can experience this condition.

Diagnosis is in part directly related to the history of a superficial ulcer with or without corneal neovascularization, conjunctival hyperemia, and irregular or inconsistent patterns of shifting size and shape. On clinical examination there is frequently a discreet superficial ulceration, geographic or multifocal, with loose epithelial wound edges best appreciated after application of fluorescein stain (see photos). Sometimes loose flaps of epithelial sheets or fragments of epithelia from the wound edges are seen freely hanging from the ulcer's edge, misguided and unsuccessful attempts at wound healing. Most cases are unilateral, but bilateral ulcers may present. Pain in SCCEDs is highly variable, and while some dogs have significant blepharospasm, epiphora, and even mild uveitis (as evidenced by miosis with some degree of aqueous flare), other ulcers are found incidentally on physical examination as a corneal opacity initially, later discovered to be an ulcer once the fluorescein stain is applied. Without procedural intervention (described later) the corneal ulcer remains, and secondary inflammatory responses may occur including corneal neovascularization: in severe cases, granulation and necrosis of the cornea may develop.

Etiologies for the condition vary widely. Many believe that while the condition is termed spontaneous there is a claim that the condition can be triggered by any physical trauma to the cornea, including but not limited to distichia (which many Boxers have), trichiasis, ectopic cilia, entropion, or other scratches or lacerations from external stimuli (foreign bodies, etc.). While most wounds will heal readily once the inciting cause is removed, SCCEDs linger much longer due to abnormal wound healing and can often create a corneal wound that changes shape and size beyond the initial injury. It is not clear if viral, fungal, and/or bacterial

infections play a significant role in the development of SCCEDs, but infectious agents may be present in the early stages of the disease or appear later as opportunists in the ulcerated cornea. By and large, however, SCCEDs are not considered the results of ongoing infection, which distinguishes this group of corneal ulcers from others. In SCCEDs, the corneal stroma is rarely lost in these conditions, and cytology and culture of the wound generally



➤ Diamond burring is a newer technology available to ophthalmologists.

are unremarkable for infectious organisms.

With or without the presence of any physical causes for trauma to the corneal surface, these "spontaneous" wounds are known to have an abnormal surface characterized by a broken, inconsistent basement membrane with fibronectin deposition. Other studies claim that the basement

membranes appear normal, so there is considerable controversy as to the nature of the persistent ulcers. In another study, a specific superficial stromal hyalinized zone suggested that there is chronic inappropriate remodeling of the corneal surface in dogs with SCCEDs. Further, substance P and calcitonin gene-related, peptide-associated nerve fibers were found in increased numbers surrounding the corneal wounds. Whether the presence of these peptides is a reaction to the wounding or associated with the persistence of the ulcer is not clear. Matrix metalloproteinases (MMPs) have also been incriminated in the formation of SCCEDs. Specifically, MMP-9 has been found in these chronic wounds, but at much lower levels than in acute corneal injury, making them unlikely to be linked to the chronicity of the wound, but perhaps as more of a result of the injury that is present. Key to the argument of causes of SCCEDs is the role of epithelial migration factors including E-cadherin, beta-catenin, beta-actin, and desmoplakin, which do not appear to be expressed in normal canine corneal epithelium. Tetracycline has been proposed as a treatment for SCCEDs since it increases transforming growth factor-beta expression, which in turn can increase the production of these epithelial migration factors. Further studies would be necessary to prove these hypotheses. The bottom line with etiology is that the basement membrane of the cornea is damaged and irregular as a result of delayed wound healing. As we will see, the grid keratotomies or diamond burr procedures can significantly aid in the wound healing, likely by removing structural barriers to the epithelial migration and adhesion and allowing some of the inflammatory cells to gain access to the wound site, and provide the adhesion factors necessary to repair the wound.

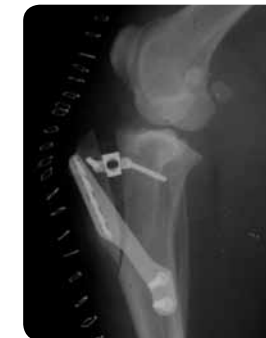> Continued on Page 6

> Cranial Cruciate Ligament Injuries: What Do I Do? (Continued from Page 1)

approximately five degrees. The tibia is stabilized in this position with a bone plate and screws. After the TPLO is done, there will still be a positive cranial drawer test, but there should be no cranial tibial thrust.

The tibial tuberosity advancement (TTA) was described by Dr. Slobodan Tepic in 2002. It stabilizes the stifle during weight-bearing by advancing the tibial tuberosity to the point that the angle between the patellar tendon and tibial plateau is 90 degrees. This effectively neutralizes tibiofemoral shear force and eliminates cranial tibial thrust. These patients will still have a positive cranial drawer test after repair, but should not have any cranial tibial thrust.

In my experience, dogs that undergo either the TPLO or TTA procedures appear to experience a faster return to weight-bearing than the lateral-suture patients.



➤ Radiograph of a TTA.

This could translate into less muscle atrophy in the recovery period and a shorter rehabilitation period. Some have theorized that these techniques provide greater stability to the stifle than the lateral suture method and thereby have less arthritis development in the future, although to my knowledge this has not been clinically documented.

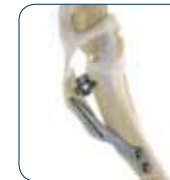I usually recommend the TPLO or TTA in large-breed, active dogs. I choose one over the other based on the pre-operative TPA measurements, and presence or absence of tibial torsion. Tibial torsion and high TPAs can be effectively corrected with a TPLO, but not with a TTA due to limitations in implant size. So, if the patient has a moderate TPA and a straight tibia, then I choose the TTA. If the TPA is high and there is tibial torsion present, then I choose the TPLO. The TTA is in my opinion a slightly less invasive type of osteotomy, as the weight-bearing axis of the tibia is preserved, and there is no caudal soft tissue dissection, which results in less post-operative swelling and presumably less discomfort.

However, if you ask three different orthopedic surgeons what they do for a cranial cruciate ligament tear, you'll probably get three different answers!

For more information, please visit angell.org/surgery. Dr. Cathy Reese may be contacted at creese@angell.org. Angell's surgeons are available for consultation via phone or e-mail (surgery@angell.org) Monday–Friday 9:00 a.m.–5:00 p.m. To reach an Angell surgeon by phone or to refer a patient to the Angell Surgery service, please call **Kim Swank** at **617 541-5048**. ■



➤ TTA diagram.



➤ TTA example.

Canine Sino-nasal Aspergillosis



By Chris Rollings,
DVM, DACVIM

Sino-nasal aspergillosis is an important cause of hemorrhagic, mucopurulent nasal discharge in dogs living in New England. Because infectious diseases (especially fungal infections) are less common in New England compared to other regions of the country, this disease is likely under-diagnosed in our area.

There are over 180 species of the opportunistic and saprophytic genus of fungus *Aspergillus*. Morphologically, *Aspergillus* is characterized by having septate and laterally branching hyphae. Canine sino-nasal aspergillosis is typically caused by *Aspergillus fumigatus*, although infections with *A. niger* and *A. flavus* have been reported. *Aspergillus* is a ubiquitous fungus and can survive in vastly different environments and climates. Infection occurs through inhalation of airborne spores known as conidia.

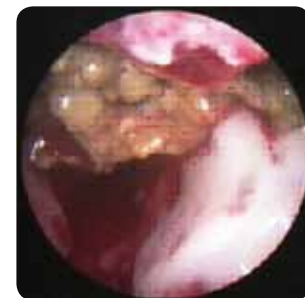Canine sino-nasal *Aspergillus* infection occurs when invasive hyphae attach to the nasal mucosa. Exposure to inhaled conidia is common, and so there has been much interest in trying to elucidate why some dogs develop severe infection while most never progress beyond asymptomatic colonization. Rare cases have a documented disruption in normal nasal defense mechanisms that likely precedes infection (ex.: neoplasia, nasal trauma, nasal foreign body), but most have no such predisposing condition. It was initially suspected that affected dogs had some sort of systemic immunodeficiency, and initial studies were suggestive of impaired lymphocyte proliferative responses. This has subsequently been found to be an effect rather than a cause of *Aspergillus* infection. It has more recently been accepted that most infected dogs do not have an underlying systemic immunodeficiency, and recent work has shown an appropriate TH-1 dominated response to infection. Interestingly, nasal biopsies from *Aspergillus*-infected dogs have been found to have increased IL-10 mRNA expression. IL-10 is an immunomodulating cytokine important in suppressing inflammation. While increased IL-10 production would have a protective role in terms of ameliorating tissue destruction associated with the potent inflammatory response, it may contribute to persistence of infection as has been documented in experimental models of chronic infectious diseases (ex.: leishmaniasis).

Canine sino-nasal aspergillosis is typically a disease of dolicocephalic and mesocephalic breeds. It can be seen in dogs of any age, and there is no obvious sex predisposition. Almost all affected dogs have mucopurulent nasal discharge (unilateral or bilateral), and up to a third of these dogs have concurrent epistaxis. Sneezing is common, and up to a third of dogs have nasal pain. Physical exam findings include increased or decreased nasal airflow (depending on the presence or absence of exudate), and some dogs (just under 25% in one retrospective study) have nasal depigmentation and ulceration. The latter findings are thought to be secondary to toxins produced by the fungus.

> Continued on Page 4

A definitive diagnosis of sino-nasal aspergillosis can be challenging, as it typically requires general anesthesia and fairly expensive testing. Routine labwork is often normal, although some affected dogs will have an inflammatory leukogram. Serology has recently been shown to be quite useful as an initial screening test for this disease. Agar-gel immunodiffusion is the most commonly employed method of serologic testing, and a recent study found a 98% specificity and a 67% sensitivity. While a negative serology does not rule out infection, a positive serology is highly suggestive of *Aspergillus* infection. Nasal imaging is a very useful modality in diagnosing sino-nasal aspergillosis. Intraoral nasal radiographs typically reveal increased soft-tissue opacity and turbinate destruction. CT evaluation (the preferred imaging study) typically reveals turbinate lysis and may reveal a frontal sinus proliferative mass effect. Importantly, a CT scan is necessary for evaluating the cribriform plate prior to topical antifungal treatment.

Confirmation of *Aspergillus* infection requires visualization of destructive rhinitis with fungal plaques on rhinoscopy, and/or histopathological evidence of fungal hyphae on biopsy. Fungal culture has a reported false-positive rate of up to 30 to 40%



➤ Intranasal fungal plaque (rhinoscopy).

(likely asymptomatic colonization), although a recent paper reported a 100% specificity if the culture was obtained from a visualized fungal plaque. In one recent paper, 17% of canine sino-nasal *Aspergillus* cases had visible plaques only in the frontal sinuses, so it is important to evaluate this area with imaging and sinuscopy when possible. The frontal sinuses can be accessed with a flexible endoscope in medium to large dogs or via trephination/rigid sinuscopy.

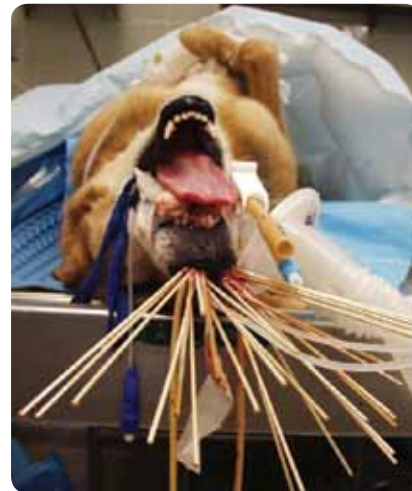Treatment of canine sino-nasal aspergillosis is often performed during the same anesthesia used for diagnostics. While systemic antifungals can be effective (itraconazole treatment is reported to have 60 to 70% success rate with a minimum of 10 weeks of therapy), topical antifungal administration is considered the treatment of choice as long as the cribriform plate is intact at the time of topical antifungal administration. Several different protocols have been reported, all with similar response rates. The first reported and most commonly used protocol involves occluding the caudal nasopharynx and external nares and instilling 60 ml of 2% clotrimazole in polyethylene glycol to each nasal cavity. The dog's recumbency is changed every 15 minutes to distribute the clotrimazole throughout the nasal cavity and into the frontal sinuses (left and right lateral recumbencies and two separate dorsal recumbencies). While it is recommended to trephine the sinus concurrently if there is sinus involvement, there are no studies at this point that prove additional benefit. Proper

placement of occluding catheters and proper rostral drainage after the procedure are crucial to prevent complications such as swelling of the oropharynx. Neurologic complications have been reported after topical antifungal treatment with cribriform-plate compromise. One to two percent enilconazole has been used similarly with equal success. Recently, a depot clotrimazole protocol (using clotrimazole cream) has been reported. This procedure has a similar success rate to the above protocols, with the advantage of decreased anesthesia time. This protocol involves frontal sinus trephination.

Clinical cure rates with the above topical protocols are reported to be in the 85% to 90% range. A recent study that used follow-up rhinoscopy to attempt to confirm resolution of fungal disease after topical clotrimazole administration found persistent fungal disease in 50% of these patients (approximately one to four months after initial treatment). Previous studies relied on clinical signs pre- or post-exam to calculate the percentage of efficacy. It is therefore recommended to repeat rhinoscopy/sinuscopy one month after treatment to ensure disease resolution, or repeat treatment prior to extensive fungal regrowth if plaques are still present. Some dogs may have recurrent antibiotic responsive nasal discharge after aspergillosis cure, likely secondary to irreversible damage to the normal nasal defense mechanisms from previous fungal infection.

At Angell Animal Medical Center, we typically diagnose several cases of sino-nasal *Aspergillus* infection per year. We have had several cases where we have only been able to diagnose this disease via sinuscopy with visualized biopsy (i.e., no plaques visible on rhinoscopy). Please feel free to contact the Angell Internal Medicine department if you have a case that you would like to send for workup and treatment of this disease.

For more information, please visit angell.org/internalmedicine. Dr. Chris Rollings may be contacted at crollings@angell.org. Angell's specialists are available for consultation via phone or e-mail (internalmedicine@angell.org) Monday–Friday 9:00 a.m.–5:00 p.m. To reach an Angell internist by phone or to refer a patient to the Angell Internal Medicine service, please call Eleanor Cousino at 617 522-5011. ■



➤ Topical clotrimazole treatment for sino-nasal aspergillosis.

> See References on Page 7

Drug Shortages and Recalls: Why Do They Happen So Often?



By Mary Grace, R.Ph., M.S.

It would seem the most difficult part of treating your patient should be diagnosing their illness — not obtaining the appropriate medication to treat the illness. Yet that is the position in which many veterinarians have recently found themselves. It seems like every month another important and common medication, both human and veterinary, is unavailable due to a drug shortage or a drug recall. The Food and Drug Administration (FDA) estimates that there were close to 300 drug recalls in just the first six months of 2010. Last year alone, cyclosporine ophthalmic ointment, furosemide injectable, ketamine, propofol, buprenorphine, Terramycin®, and Vetsulin® have all been on the backorder list at one time or another, leaving both veterinarians and clients to seek alternative therapies.

The most common reasons for drug recalls include concerns over the quality of raw materials, inaccurate labeling, or faulty packaging and suspected contamination of the final product.

Drug recalls are classified based on the probability that the affected product will cause serious harm or death in the patient.

Class I: A reasonable probability exists that the use of the product will result in serious, adverse health consequences or death.

Class II: A remote probability of adverse health consequences from the product exists.

Class III: Use of the product is not likely to cause adverse effects.

The most common reasons for drug recalls include concerns over the quality of raw materials, inaccurate labeling, or faulty packaging and suspected contamination of the final product. Much of this may be attributable to the rush to market a generic version of a drug when the brand-name product loses patent protection. The first company to bring the generic product to market wins the right to exclusively market that drug for 180 days. This “first-one-on-the-block” situation can be quite lucrative for the drug manufacturer, as it is a perfect opportunity to gain and maintain market share. It does not, however, allow for a very long learning curve. Often the manufacturing process is not optimized and consequently a drug recall follows.

> Continued on Page 7

THE TECHNICIAN'S CORNER

Handheld Ultrasound for Cystocentesis

By Ann Marie Wylie, CVT



How many times have you needed a urine sample on an overweight FUS cat and the bladder was not palpable? Or what about the dog with signs of a UTI, that urinated on its way into the hospital? Angell clinic technicians and



➤ Ann Marie Wylie (right) visualizes a dog's bladder using the SpeqView handheld ultrasound.

veterinarians now have a handheld ultrasound available for these situations. Just over a year ago we purchased the SpeqView personal ultrasound by Signosics.

The SpeqView is designed for veterinary use, and delivers affordable and conventional ultrasound to the point of care. It offers quick imaging studies that aim to identify the presence or

absence of obvious pathology. The SpeqView can provide images of abdominal, vascular, cardiac, small organ, musculoskeletal, and fetal anatomy. It is not intended for complete or detailed studies of any of these areas. You can freeze, store, measure, and review images.

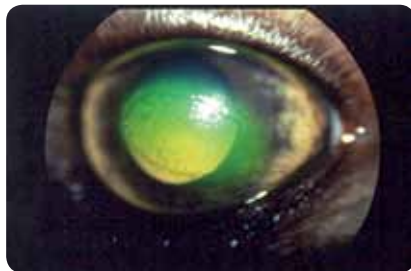
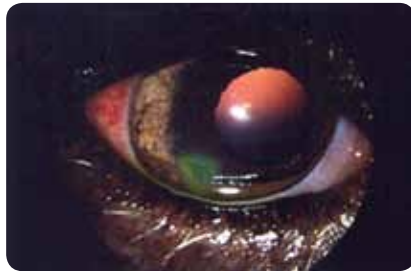
Our main application is visualizing bladders for cystocentesis. With our handheld ultrasound we can quickly and easily visualize the bladder and obtain our sterile samples via cystocentesis. The SpeqView operates in both B mode, providing conventional sector-shaped images, and M mode, providing sweeping, panoramic images. We use it in M mode for cystocentesis. The probe is swept over the abdomen, and the bladder is easily identified as a black strip in the ultrasound image. We “mark” the location of the bladder with a fingertip, remove the probe, and obtain our sample with the conventional, aseptic cystocentesis technique.

Cystocentesis is considered by most to be the ideal way to obtain a urine sample. These samples are free of bacteria, cells, and debris from the lower urinary tract. Samples obtained via cystocentesis may be contaminated with blood as a result of the needle puncture, but this does not interfere with the culture. Catheterization is an option in dogs, but there is concern for iatrogenic urinary tract infection. Free-catch and tabletop samples can contain bacterial contamination from the environment or the lower urinary tract.

If a patient resists abdominal palpation, we can visualize the bladder with minimal palpation using the handheld ultrasound. It is also quite useful in obese cats and large dogs, where bladder palpation is difficult. There is a nominal fee charged to the client for the use of the ultrasound. Having this technology available allows us to provide more thorough care for our patients.

For more information, please e-mail Ann Marie Wylie at awylie@angell.org or internalmedicine@angell.org. Angell's doctors are available for consultation via phone or e-mail Monday–Friday 9:00 a.m.–5:00 p.m. To reach an Angell doctor, please call Eleanor Cousino at 617 522-5011. ■

> **Non-healing Superficial Corneal Ulcers in Dogs**
(Continued from Page 2)



➤ Examples of indolent ulcers.

Treatment of SCCEDs (see Table) includes topical medication to promote healing (refrigerated serum, stable for 10–14 days), prevent infection (e.g., Terramycin QID), and treat pain (Atropine to effect up to QID). Topical anti-inflammatories (both steroids and NSAIDs) should be avoided. If a patient is on cyclosporine topically for dry eye or is found to have concurrent dry eye, the cyclosporine may be used topically alongside the other eye

medication. Oral medication, including NSAIDs, and (in sensitive patients) oral narcotics, is also administered as the ulcer heals for pain relief. Procedures that are often integral to wound healing include gentle debridement of all loose and devitalized epithelia at the wound edges, usually accomplished with a soft (sterile) cotton swab with manual restraint and topical anesthesia. This accomplishes a "resetting" of the wound healing and important removal of excessive and unnecessary tissue that is an impediment to recovery. An eyelid speculum can help immobilize the eyelids (including the nictitating membrane) during this procedure and the next. A grid keratotomy or a diamond burring procedure usually follows the thorough debridement, to clear the superficial stroma of material thought to be a barrier to healing as discussed above. I perform a grid keratotomy with a 20-gauge needle, a trustworthy technician to hold the animal, and topical anesthesia, usually two drops of proparacaine administered five minutes apart and allowed to work for at least five minutes prior to debridement and gridding. Diamond burring is a newer technology available to ophthalmologists and is proving to be equivalent to the grid procedure (see photo). Bandage contact lens placement is an additional aid in the treatment of the most stubborn ulcers. I usually will apply a bandage lens as a secondary effort when the above procedures are not effective. The lens is left in place for up to a week or longer. Invariably, some lenses do not stay in for that long, which is a disadvantage to its placement. The lens would be an equivalent of a third eyelid flap or tarsorrhaphy, older methods for corneal protection that are rarely used today. An Elizabethan collar or Comfy Cone helps reduce the ability of most patients to self-traumatize the affected eye during recovery.

Spontaneous Chronic Corneal Epithelial Defects (SCCEDs)

Clinical signs

- Superficial fluorescein uptake
- Irregular ulcer patterns of shifting size and shape
- Epithelial fragments or loose flaps
- +/- Corneal neovascularization
- +/- Conjunctival hyperemia
- +/- Blepharospasm
- +/- Epiphora
- +/- Secondary uveitis

Treatments

- Gentle debridement of all loose and devitalized corneal epithelia under topical anesthesia
- Grid keratotomy or diamond burr procedure (best reserved for ophthalmologist)
- Topical medication (e.g., Teramycin, atropine, autologous serum)
- Cyclosporine (if KCS present)
- Pain management (systemic)
- Avoid topical anti-inflammatories (NSAID and steroid)
- Bandage contact lens placement (secondary procedure)
- Oral doxycycline and tetracycline (hypothetical)

Prognosis for SCCEDs is widely variable, but in general favorable with time and medication. Some ulcers heal rapidly with treatment, and others are less rapid to heal, taking weeks or longer. The most important thing for clients to remember is that patience is important, as these ulcers can be quite stubborn. Even after healing, ulcers may reappear spontaneously in the same eye or the other eye. Repeat gridding or burring following additional soft swab debridement may be necessary for the most resistant ulcers. Usually after the first treatment the ulcer is rechecked in 5–7 days and medication is adjusted. Rechecks are usually every 1–2 weeks until the ulcer is fully healed. The most sensitive period is usually 1–5 days after the grid keratotomy/burring procedures. Duration of sensitivity may depend on the size of the ulcer, degree of existing keratitis at the time of the procedure, and the use of topical and systemic pain medication.

For more information, please visit angell.org/eyes. Dr. Dan Biros may be contacted at dbiros@angell.org. Angell's ophthalmologists are available for consultation via phone or e-mail (ophthalmology@angell.org) Monday–Friday 9:00 a.m.–5:00 p.m. Evening and early-morning appointments are also available. To reach an Angell ophthalmologist by phone or to refer a patient to the Angell Surgery service, please call Sandra Russo at 617 541-5095. ■

> **Drug Shortages and Recalls: Why Do They Happen So Often?**
(Continued from Page 4)

While drug recalls are inconvenient and may be costly, one can argue that the high number of recalls has actually improved the safety of the drug supply in this country. The FDA has the power to mandate drug recalls, thus holding manufacturers accountable for producing high-quality, safe, and efficacious products. Unfortunately, sometimes practitioners are not even aware of a drug recall until, while attempting to reorder a medication, they are informed that a shortage of the product exists.

Drug shortages can also cause significant disruption in the course of treatment for a patient. The major reasons for drug shortages include:

- Limited availability of raw ingredients required to manufacture the product
- FDA actions that halt production of the product
- A voluntary recall by the manufacturer
- Limited manufacturing capacity
- Rumors of shortage, leading to hoarding of product
- Poor inventory-management practices by manufacturers and/or distributors
- Business decisions made by drug companies to discontinue drugs

The FDA cannot force any company to manufacture a drug. The agency can, however, work with manufacturers with the intent of bringing the product back to market. Sometimes this is accomplished by the development of special distribution networks, and other times through a strict approval process. This is especially true when the product in short supply is deemed by the FDA to be medically necessary and there are no equivalent products available.

When commonly used medications are unavailable, clinical practice can be severely impacted. Research must be conducted to find alternative products, and treatment protocols must be adjusted to accommodate them. Straying from familiar protocols increases the chance that an error will be made or a drug interaction will occur.

Various websites are available to keep practitioners and patients up-to-date on drug recalls and shortages:

- fda.gov/safety/recalls
- fda.gov/drugs/drugsafety/drugshortages
- avma.org/productsafety/recalls

The pharmacy at Angell is staffed by a registered pharmacist and six full-time certified pharmacy technicians. They can be reached at 617 524-5700. ■

> **Canine Sino-nasal Aspergillosis References**
(Continued from Page 4)

Day, Michael J. "Canine sino-nasal aspergillosis; parallels with human disease." *Medical Mycology* 2008, pp. 1–9.

Greci, V. et al. "Retrospective Study of One Hour Intranasal Infusion of 1% Clotrimazole Solution for Treatment of Sinonasal Aspergillosis in Dogs: 47 cases (February 1998–October 2007)." *British Small Animal Veterinary Congress*, 2008.

Harkin, Kenneth. "Aspergillosis: An overview in dogs and cats." *Veterinary Medicine*, July 2003, pp. 602–617.

Johnson, Lynelle R. et al. "Results of rhinoscopy alone or in conjunction with sinuscopy in dogs with aspergillosis: 46 cases (2001–2004)." *JAVMA* Vol. 228, March 1, 2006, pp. 738–742.

Peeters, Dominique. "Canine Sinonasal Aspergillosis: Immunopathogenesis." *ACVIM Proceedings*, 2009.

Peeters, Dominique, et al. "Distinct tissue cytokine and chemokine mRNA expression in canine sino-nasal aspergillosis and idiopathic lymphoplasmacytic rhinitis." *Veterinary Immunology and Immunopathology*, Vol. 117, 2007, pp. 95–105.

Pomrantz, Jill S. et al. "Comparison of serologic evaluation via agar gel immunodiffusion and fungal culture of tissue for diagnosis of nasal aspergillosis in dogs." *JAVMA* Vol. 230, May 1, 2007, pp. 1319–1323.

Pomrantz, Jill S. "Update on the Efficacy of Topical Clotrimazole in the Treatment of Canine Nasal Aspergillosis." *ACVIM abstract*, 2007.

Schuller, Simone. "Long-Term Outcomes in Dogs with Sinonasal Aspergillosis Treated with Intranasal Infusions of Enilconazole." *JAAHA* 2007; 43: pp. 33–38.

Sissener, T. R. et al. "Combined clotrimazole irrigation and depot therapy for canine nasal aspergillosis." *JSAP* 47, 2006, pp. 312–315.

REFERRAL CONTACT INFORMATION

Cardiology Service

Referral Contact: Sandra Russo
Referral Line: 617 541-5038
Referral Fax: 617 989-1653
E-mail: cardiology@angell.org
angell.org/cardiology

Clinical and Anatomical Pathology Service

Referral Contact: Laboratory Staff
Referral Line: 617 541-5014
Referral Fax: 617 522-7356
E-mail: pathology@angell.org
angell.org/lab
*Sample submission forms and information at angell.org/lab

Dentistry Service

Referral Contact: Michael Johnson
Referral Line: 617 524-5643
Referral Fax: 617 989-1636
E-mail: dentistry@angell.org
angell.org/dentistry

Dermatology Service

Referral Contact: Rebecca Stlaske
Referral Line: 617 524-5733
Referral Fax: 617 989-1613
E-mail: dermatology@angell.org
angell.org/dermatology

Emergency Service

Referral Line: 617 522-7282 press 1
Referral Fax: 617 989-1633
E-mail: emergency@angell.org
angell.org/emergency

For all other referrals, please contact Eleanor Cousino, Angell Referral Coordinator, at 617 522-5011, or by fax at 617 989-1635.

Neurology Service

Referral Contact: Lisa Canale
Referral Line: 617 541-5140
Referral Fax: 617 989-1666
E-mail: neurology@angell.org
angell.org/neurology

Oncology Service

Referral Contact: Oncology Staff
Referral Line: 617 541-5136
Referral Fax: 617 541-5130
E-mail: oncology@angell.org
angell.org/oncology

Ophthalmology Service

Referral Contact: Sandra Russo
Referral Line: 617 541-5095
Referral Fax: 617 989-1647
E-mail: ophthalmology@angell.org
angell.org/eyes

Pain Medicine Service

Referral Contact: Lisa Canale
Referral Line: 617 541-5140
Referral Fax: 617 989-1666
E-mail: painmedicine@angell.org
angell.org/painmedicine

Surgery Service

Referral Contact: Kim Swank
Referral Line: 617 541-5048
Referral Fax: 617 989-1660
E-mail: surgery@angell.org
angell.org/surgery



350 South Huntington Ave.
Boston, MA 02130

angell.org/specialties

Nonprofit Org.
US Postage
Paid
Permit No. 1141
Boston, MA

Are your clients new to Angell? Send them to angell.org/directions for detailed directions to our location. Ample free parking on site.

We encourage you to e-mail Angell's specialists with questions. We hope you will use Angell as a resource, and we look forward to working with you as we continue our legacy of providing compassion and care for animals.

Main Phone: 617 522-7282
Veterinary Referrals: 617 522-5011

Chief of Staff

Ann Marie Manning,
DVM, DACVECC
amanning@angell.org

Avian & Exotic Animal Medicine

Jennifer E. Graham,
DVM, DABVP (Avian/Exotic
Companion Mammal), DACZM
jgraham@angell.org

Cardiology

Nancy J. Laste,
DVM, DACVIM (Cardiology)
nlaste@angell.org

Rebecca I. Malakoff,
DVM, DACVIM (Cardiology)
rmalakoff@angell.org

Clinical & Anatomical Pathology

Patty Ewing,
DVM, MS, DACVP
pewing@angell.org

Pamela Mouser,
DVM, MS, DACVP
pmouser@angell.org

Dentistry

William Rosenblad,
DVM
wrosenblad@angell.org

Curtis A. Stiles,
DVM, DAVDC
cstiles@angell.org

Dermatology

Kathy Tater,
DVM, DACVD
dermatology@angell.org

Diagnostic Imaging

Jessica Basseches,
DVM, DACVR
jbasseches@angell.org

Kathy A. Beck,
DVM, DACVR
kbeck@angell.org

Joan Regan,
VMD, DACVR
jregan@angell.org

Emergency & Critical Care Medicine

Kiko Bracker,
DVM, DACVECC
kbracker@angell.org

Jennifer Holm,
DVM, DACVECC
jholm@angell.org

Megan Whelan,
DVM, DACVECC
mwhelan@angell.org

Internal Medicine

Doug Brum,
DVM
dbrum@angell.org

Maureen Carroll,
DVM, DACVIM
mccarroll@angell.org

Erika de Papp,
DVM, DACVIM
edepapp@angell.org

Jean Marie Duddy,
DVM
jduddy@angell.org

Shawn Kearns,
DVM, DACVIM
skearns@angell.org

Susan O'Bell,
DVM, MPH, DACVIM
sobell@angell.org

Chris Rollings,
DVM, DACVIM
crollings@angell.org

Neurology

Andrew Farabaugh,
DVM
afarabaugh@angell.org

Allen Sisson,
DVM, MS, DACVIM (Neurology)
asisson@angell.org

Nutrition

Rebecca I. Remillard,
PhD, DVM, MS, DACVN
rremillard@angell.org

Oncology

Christine Anderson,
DVM, MS, DACVIM (Oncology),
DACVR (Radiation Oncology)
cranderson@angell.org

Jennifer Mahoney,
DVM
jmahoney@angell.org

Carrie Wood,
DVM,
DACVIM (Oncology)
cawood@angell.org

Ophthalmology

Daniel J. Biros,
DVM, DACVO
dbiros@angell.org

Martin Coster,
DVM, MS, DACVO
mcoster@angell.org

Pain Medicine

Lisa Moses,
VMD, DACVIM, CVMA
lmoses@angell.org

Surgery

Sue Casale,
DVM, DACVS
scasale@angell.org

David W. Knapp,
DVM, DACVS
dknapp@angell.org

Michael M. Pavletic,
DVM, DACVS
mpavletic@angell.org

Catherine J. Reese,
DVM, DACVS
creese@angell.org

Nicholas J. Trout,
MA, VET MB, MRCVS,
DACVS, DECVS
ntrout@angell.org