



INTERNAL MEDICINE
PAGE 1 Therapies for Refractory Urethral Sphincter Mechanism Incompetence
INTERNAL MEDICINE
PAGE 1 Approach to the Coughing Cat
EMERGENCY
PAGE 5 Feline Hyperaldosteronism
OPHTHALMOLOGY
PAGE 7 Navigating Corneal Ulcerative Disasters in Dogs
INTERNAL MEDICINE
PAGE 10 Leptospirosis
PATHOLOGY
PAGE 15 Canine and Feline Cutaneous Round Cell Tumors



INTERNAL MEDICINE

Therapies for Refractory Urethral Sphincter Mechanism Incompetence

Zachary Crouse, DVM, DACVIM (SAIM) | internalmedicine@angell.org
angell.org/internalmedicine | 617 541-5186



Urethral sphincter mechanism incompetence (USMI) is the most common cause of acquired urinary incontinence in adult dogs.^{1,2} USMI can affect up to 20% of neutered female dogs³ and is more common in large breed dogs.¹ The urethral sphincter is composed of urethral smooth muscle, surrounding connective tissues, and vasculature.³ The pathophysiology of USMI is complex and involves loss of estrogen receptors on the smooth muscle, as well as changes to collagen content and conformation of the patient (pelvic bladder, short urethra, recessed vulva).^{1,3} While loss of estrogen does not contribute

to USMI in male dogs, hormones still appear to play a role in development of USMI in males, as USMI occurs more frequently in neutered male dogs than intact male dogs.³

Dogs with USMI typically leak urine when asleep or in lateral recumbency, but they may also have urine leakage during excitement or activity.² A thorough history, physical exam with attention to conformation of the urogenital tract, urinalysis, and culture are essential to exclude other causes of incontinence. A complete blood count and serum chemistry may be indicated,

(CONTINUED ON PAGE 2)



INTERNAL MEDICINE

Approach to the Coughing Cat

Jean Duddy, DVM | angell.org/internalmedicine
internalmedicine@angell.org | 617 541-5186

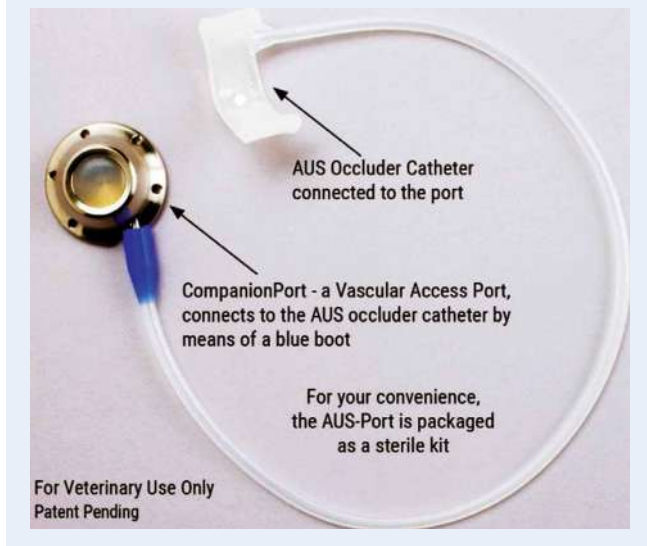
The first challenge when treating a coughing cat is determining if the cat is actually coughing. Gagging (such as with a hairball) or choking will need to be ruled out. Since owners often cannot tell the difference, it is very helpful to have your pet's owner use a cell phone to video this at home. It is not very often that we have a cat come into our exam room and cough for us.

A cough is a defensive mechanism or reflex of the respiratory system. It is used to dispatch foreign material from the airways. A cough occurs due to stimulation of mechanoreceptors or chemoreceptors within the respiratory tract itself. These cough receptors are located throughout the entire respiratory tract from the pharynx to the bronchioles. So a cough is very nonspecific and does not tell us if the cause is upper or lower airway issues.

(CONTINUED ON PAGE 3)

FIGURE 1

Hydraulic occluder device, Norfolk Vet Products



and further urogenital imaging (abdominal ultrasound, cystoscopy, or CT) may be necessary to exclude anatomic causes of incontinence.^{2,3} Dogs with USMI should have a compatible history and unremarkable lab work. Physical exam and imaging studies may show anatomic abnormalities contributing to USMI, such as a pelvic bladder or recessed vulva, but should exclude separate causes of incontinence, such as ectopic ureters.

After a diagnosis of USMI has been made, medical therapy is considered the first line of treatment. Estriol (Incurin, see package insert for dosing instructions) and diethylstilbestrol (DES, 0.1-1.0 mg/dog po q24 for 5-7 d then weekly or as needed) are estrogen compounds that can be used to increase the number and sensitivity of the estrogen receptors in the female dog's urethral sphincter. Estriol is effective in 89% of cases of USMI, and DES is effective in 65% of cases. When using an estrogen compound, a CBC should be checked prior to starting treatment and after one month on the chosen drug, although bone marrow suppression is not listed as an expected adverse event of estriol's daily administration.³ Currently, estriol is the only FDA-approved estrogen compound for treatment of USMI in dogs and should be the first choice in female dogs suspected of having USMI. Phenylpropanolamine (PPA, 1.0-1.5 mg/kg po q8-12) is an alpha adrenergic agonist which increases the tone of the smooth muscle comprising the urethral sphincter² and ranges in efficacy from 75-90%.³ A combination of estrogen therapy with PPA is commonly used in dogs who do not respond to medical therapy with a single agent. While there is a lack of evidence to support a synergistic effect between PPA and estrogens, there are anecdotal reports of success when the therapies are combined.⁴ Estrogen compounds should not be used in male dogs and should be used with caution in cats.² When USMI remains refractory to medical therapy with PPA (male dogs, cats) or a combination of PPA and an estrogen compound (female dogs), then use of a urethral bulking agent (UBA) or surgical intervention should be considered.

UBAs should be used in patients where additional lower urinary tract disease has been excluded and medical management has failed. These patients should have a negative culture within 2 weeks of injection of the UBA. With the use of a UBA, many dogs have improvement in incontinence for a period of 10-18 months, but they may also require medical management

during this time to maintain continence.⁴ UBAs are delivered cystoscopically by injecting the agent submucosally within the urethra. Currently, collagen is available in the United States for submucosal injection (Regain-Avalon Medical). Risks with injection of a UBA include infection, bleeding, urethral obstruction, failure of continence, and intolerance of the injected material.⁴ Prior to injection of a UBA, clients should be educated that expected continence rates are 50-70% with UBA and that medications and repeat procedures may be necessary as the UBA will have a limited duration of efficacy.⁴

Numerous surgical options to correct USMI have been described but typically have poor long-term efficacy. More recently, placement of a urethral hydraulic occluder (HO) has shown promise. A urethral HO is composed of an incomplete silicone ring that is sutured around the pelvic urethra. The silicone ring is inflatable and is connected to a small injection port that is sutured subcutaneously, to allow future access.⁵ After placement of the hydraulic occluder, many patients will require inflations to maximize continence. The protocol for inflation of the HO device is clinician dependent, but the goal is to incrementally increase the amount of saline in the occluder cuff until an acceptable level of urinary continence has been achieved. In one study of 18 female dogs with refractory urinary incontinence, all dogs had an improved continence score.⁵ In this same study, in dogs with owners who were compliant with follow-up, 92% were functionally continent and 77% were completely continent.⁵ In addition to female dogs, placement of urethral HO devices has been described in male dogs⁶ and female cats.⁷

The vast majority of patients diagnosed with USMI will respond to either estriol, DES, or PPA. In cases of female dogs that are refractory to single agent medical therapy, use of both PPA and an estrogen drug should be attempted. If incontinence persists in these cases, then use of a UBA or surgical implantation of a urethral HO device can improve continence and quality of life.

REFERENCES

- Byron JK, Taylor KH, Phillips GS, and Stahl MS. Urethral sphincter mechanism incompetence in 163 neutered female dogs: diagnosis treatment, and relationship of weight and age at neuter to development of disease. *J Vet Intern Med* 2017; 31:442-448.
- Owen LJ. Ureteral ectopia and urethral sphincter mechanism incompetence: an update on diagnosis and management options. *J Small Anim Pract*. 2018. Epub ahead of print.
- Byron JK. Micturition disorders. *Vet Clin Small Anim*. 2015; 45: 769-782.
- Byron J. Injectable bulking agents for treatment of urinary incontinence. In: *Veterinary image-guided interventions*. 1st edn, Weisse C and Berent A eds, Wiley Blackwell, Ames, IA. 2015:398-409.
- Curao RL, Berent AC, Weisse C, and Fox P. Use of a percutaneously controlled urethral hydraulic occluder for treatment of refractory urinary incontinence in 18 female dogs. *Vet Surg*. 2013 May; 42(4):440-7.
- Reeves L, Adin C, McLoughlin M, et al. Outcome after placement of an artificial urethral sphincter in 27 dogs. *Vet Surg*. 2013; 42(1):12-8.
- Wilson KE, Berent AC, and Weisse CW. Use of a percutaneously controlled hydraulic occluder for treatment of refractory urinary incontinence in three female cats. *J Am Vet Med Assoc*. 2016 Mar; 248(5):544-51.

INTERNAL MEDICINE

Approach to the Coughing Cat

CONTINUED FROM PAGE 1

Once we have determined there is coughing going on, we need to get a good history, as this will help guide us for our determination of the etiology of the cough. Is the cough acute or chronic? Any cough for more than 2 weeks is considered chronic. A young cat with acute coughing and nasal discharge is more likely to have an infectious or foreign body reaction, while an older cat with worsening coughing and weight loss may be more likely to have neoplasia or asthma.

Timing of the cough may give us some hint as well. Coughing after eating/drinking may indicate laryngeal dysfunction. Knowing if this is the first episode (or occurs only seasonally) as well as a response to any previous therapy will also help focus the search for the etiology of the cough.

Cats that are in respiratory distress should be provided with oxygen immediately, while stable cats should be observed prior to the actual physical exam. The exam is an important part of localization of the cough even though it is rare you will actually observe a cough. Observation of the cat's respiratory rate and pattern as well as any respiratory noises may give insight to the source of the cough. Stertorous respiration or inspiratory dyspnea may indicate laryngeal or upper airway disease, while wheezing may indicate lower airway disease.

Be methodical in your physical exam. A “look, listen, and feel” approach is often best. Look from a distance to see the breathing patterns. Listen for breathing noises both with and without a stethoscope, and then feel or conduct your physical exam.

- Check oral mucus membranes for color (cyanosis, pale). Check for any abnormalities in the mouth, such as foreign material, masses, ulcerations, trauma, etc.
- Check the nasal passages for airflow, discharge, or masses. Are there any malformations?
- Palpate over the trachea and larynx to detect masses or sensitivity. Can a cough be induced?
- Palpate the rib cage for masses and gauge the ability to compress the chest (excessive resistance can indicate fluid or mediastinal mass).
- Now conduct auscultation over all parts of the respiratory tract, including the larynx, trachea, and the lung fields.
 - Inspiratory noises are usually from the upper respiratory tract (nose, pharynx, larynx, or trachea).

- Expiratory noises are usually from the lower respiratory tract (lower airways and pulmonary parenchyma). Wheezing may mean the airway is narrowing, while crackles or moist sounds may indicate fluid within the lumen of the airway.
- Remember that with some diseases such as feline asthma, cats may auscult normally.
- Palpation of the larynx and trachea can be done to check for masses, or try to elicit a cough in the exam room.
- Complete your entire physical exam – things such as abdominal masses can impinge on the diaphragm and cause increased respiratory rates and increased effort. Unlike dogs, cats do not cough that often from congestive heart failure, but heart murmurs and arrhythmias should be noted for further evaluation.

Once we have determined the cat is coughing, the next step is to localize it to one area of the respiratory tract. Then a list of differential diagnoses will help determine the next round of diagnostic tests to be done. A minimum data base is indicated for all of these cats, including a CBC and biochemical profile. Other testing may include retrovirus testing for FeLV and FIV, and PCR testing for respiratory viruses (feline herpesvirus FHV-1 and feline calicivirus (FCV)).

Oropharyngeal disease may be characterized by a gurgle or rattling cough often followed by retching. Other respiratory signs such as stertor or inspiratory dyspnea are also often observed. There also can be excessive salivation or nasal and/or ocular discharge present.

Common causes of oropharyngeal diseases would be pharyngitis (infectious or foreign body), nasopharyngeal polyp, neoplasia, or even trauma.

Diagnostics would include a sedated (or anesthetized) oral exam. To evaluate for a nasopharyngeal polyp, use a spay hook to retract the soft palate and a dental mirror to see if there is a mass/polyp. Lateral skull radiographs or CT should be obtained to check the tympanic bullae for an increased soft tissue density which may be associated with the polyp.

Upper Airway (Larynx/Trachea) disease is characterized by a dry harsh cough and stridor. A noisy breathing pattern may present on inspiration.

Common causes would include laryngitis, tracheitis (infectious, foreign body, neoplasia), or laryngeal paralysis.



Diagnostics would include radiographs to evaluate the trachea for narrowing or any mass lesions. A sedated (or anesthetized) airway exam can evaluate laryngeal structures and function (movement of the larynx). Endoscopic evaluation may be needed to fully assess the trachea.

Caution should be taken here to control the airway, especially if dealing with laryngeal or tracheal masses. Even minimal handling of these masses (such as a biopsy) can cause enough inflammation that emergency measures such as a tracheostomy may be needed. These cats should be closely monitored while they are waking up for any airway obstructions.

Lower Airway (Bronchial tree) disease is characterized by a dry, harsh cough with wheezing and possibly crackles on auscultation. There is more of an abdominal effort by the cat when breathing.

Common causes would be asthma and chronic bronchitis (+/- concurrent infections), foreign body, or neoplasia.

Diagnostics would include thoracic radiographs, fecal flotation, and the Baermann technique to rule out *Aelurostrongylus abstrusus* and *Eucoleus aerophilus* (feline lung worm). Bronchoscopy and bronchoalveolar lavage (BAL) should be performed to obtain samples for cytology and bacterial cultures, and PCR testing should be performed for *Mycoplasma spp.* and *Bordetella bronchiseptica*.

(CONTINUED ON PAGE 4)

INTERNAL MEDICINE

Approach to the Coughing Cat

CONTINUED FROM PAGE 3

Pulmonary parenchyma diseases often cause a moist cough and crackles on auscultation.

Common causes would be bronchopneumonia (infectious, or secondary to aspiration), neoplasia, edema (cardiogenic or noncardiogenic), heartworm disease, hemorrhage, or pulmonary fibrosis.

Diagnostics would include radiographs, echocardiogram/EKG +/- BP and T4 if a murmur or arrhythmia is detected, and a coagulation panel if a hemorrhage is suspected. Toxoplasmosis IgM and IgG titers should be considered if appropriate. Otherwise, a BAL should be performed to obtain samples for cytology, cultures, and PCR testing.

Pleural space diseases do not often cause coughing but do cause respiratory compromise

and distress. Dull heart sounds and loss of airway sounds on auscultation may be noted. Also, the chest may be less compressible on palpation. Neoplasia (mediastinal masses such as lymphoma or thymoma) or pleural effusion from cardiac disease or neoplasia are some of the common diseases. Diagnostics would include radiographs or, if those are too stressful, a thoracic ultrasound will help confirm fluid or a mediastinal mass. An echocardiogram and thoracocentesis for pleural effusion sampling would then be indicated.

In summary, a good history is important as most cats do not show symptoms of minor respiratory disease in the exam room. Be methodical in your physical exam, especially when dealing with the respiratory tract. Localize the cough to a specific area of the respiratory tract so a list of differential

diagnoses can be made and appropriate diagnostics can be done. This will help you come up with a definitive diagnosis and begin specific treatment.

For more information, contact Angell's Internal Medicine service at 617 541-5186 or internalmedicine@angell.org.



↘ Angell's Comfort Care Program Provides Extra TLC to Patients

The Angell Comfort Care Program provides extra comfort and reassurance for hospitalized patients in our Critical Care Unit (CCU). Trained volunteers provide extra cage-side affection to patients identified by veterinarians and technicians as animals that would benefit from additional TLC due to their particular circumstance (prolonged hospital stay, their level of anxiety, etc.).

Research indicates that comfort care makes a big difference for human babies – with faster weight gain, shorter hospital stays and improved social, emotional, and physical development resulting from a well-executed program. We believe that the Comfort Care program results in similar benefits for animals, including the reduction of patient anxiety and pain sensation.

Volunteers spend anywhere from 10 to 15 minutes with each animal before moving on to other patients.

Visit us on the web at: angell.org/comfortcare.



Feline Hyperaldosteronism

By Kiko Bracker, DVM, DACVECC

angell.org/emergency | emergency@angell.org | 617 522-7282

Feline hyperaldosteronism is likely the most common adrenocortical disease affecting cats. It is rarely identified in dogs, with only a few sporadic case reports testifying to its existence in that species. The eponym *Conn's syndrome* is sometimes applied to primary hyperaldosteronism after Jerome Conn, who first identified the issue in humans in 1955.¹ Tumors of the adrenal cortex or adrenal cortical hyperplasia can result in excessive aldosterone secretion. Aldosterone is a hormone that balances sodium and potassium levels, with sodium being resorbed in the distal convoluted tubule of the loop of Henle, and potassium being excreted into the urine in the collecting ducts of the distal nephron.

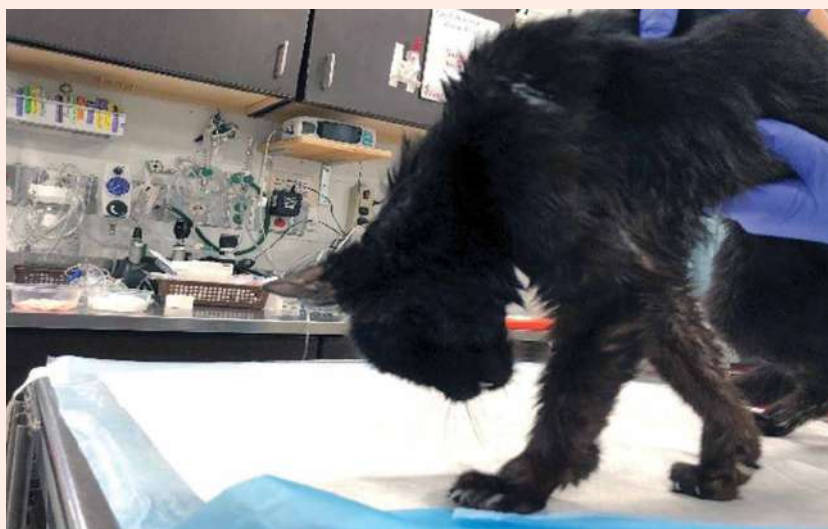Hyperaldosteronism can be a bit tricky to identify because it is not high on our radar of feline illnesses. It does result in a fairly predictable collection of clinical and clinicopathological abnormalities that, when viewed together, can strongly suggest hyperaldosteronism as the cause of illness.

Profound hypokalemia (<3.0mEq/L) is often the first abnormality identified that triggers a suspicion of hyperaldosteronism. Low potassium is seen in 90% of cats with this problem. Interestingly, hypernatremia is *not* commonly seen since it is usually balanced by water being resorbed with the excess sodium. Other clinpath irregularities include mild azotemia (50% of cases), creatine kinase elevation (95% of cases), and an elevated aldosterone level is seen in about 90% of cases.^{2,3,4} (A serum potassium of <3.0mEq/L on initial lab work in a patient that is not taking furosemide is almost always due to either potassium wasting from chronic kidney disease or hyperaldosteronism, in our experience.)

The clinical or historical signs of hyperaldosteronism are fairly non-specific. These patients generally present with lethargy, weight loss, and historical PU/PD. But if a patient also shows ventral neck flexion due to low potassium (image 1), or hypertension which can result in intraocular hemorrhage or retinal detachment – the leap to a suspicion of excessive aldosterone secretion is made more easily.

FIGURE 1

↘ Cervical ventroflexion due to hypokalemia.



The next diagnostic steps will likely be an abdominal ultrasound and an aldosterone level. But a serum potassium level of <3.0mEq/L does warrant some intervention often before those two tests can be accomplished. If the potassium level gets near to 2.0mEq/L, respiratory muscle weakness and hypoventilation can result.^{5,6} Profoundly weak or azotemic hypokalemic cats should be hospitalized for IV fluid therapy and aggressive IV potassium supplementation. More stable patients can be supplemented with oral potassium gluconate at 2-6mEq/cat BID.^{3,4}

An aldosterone level should be submitted prior to supplementation with potassium if at all possible. Aldosterone secretion is directly related to the blood potassium level. Aldosterone's primary action is to reduce/excrete potassium. If the blood potassium level is low, then aldosterone secretion should be maximally shut off in the normal patient. Even an aldosterone level within the normal range in a *hypokalemic* patient would be considered too high, and suggestive of aldosterone hypersecretion. Either a spun and

separated EDTA plasma sample or a clot tube can be used to evaluate an aldosterone level with a minimal sample requirement of 0.5-1.0ml of plasma or serum. The turnaround time can be up to a week, so prompt submission of this sample is helpful. Consult your lab about specific sample and shipping requirements.

Abdominal ultrasound is the most commonly used imaging modality to identify the source of suspected aldosterone secretion. Single adrenal tumors are the most common finding, often with a small to normal contralateral adrenal gland. Adrenal cortical hyperplasia may manifest itself as bilateral adrenal enlargement. Even bilateral adrenal adenomas have been identified.³ Invasion of the vena cava is an uncommon occurrence, evident in only about 10% of cases. Caval involvement is more critically evaluated with an abdominal CT scan.²

Once a diagnosis is made or is confidently suspected, medical treatment should be started.

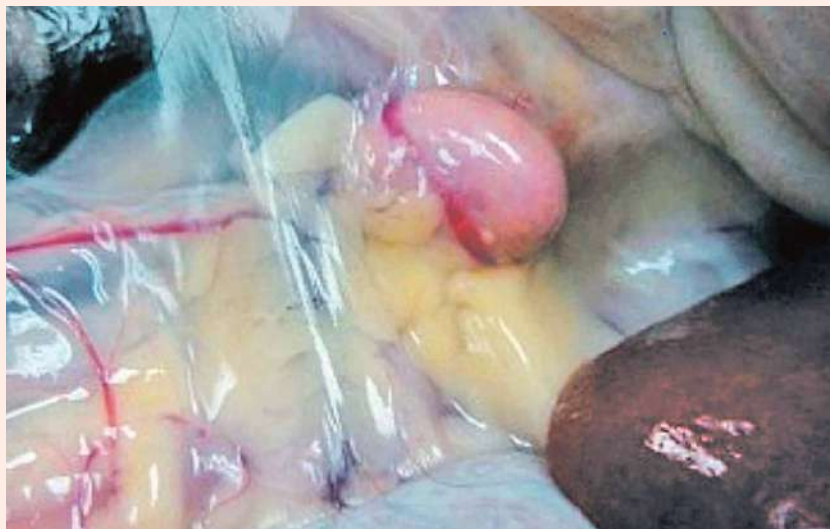(CONTINUED ON PAGE 6)

EMERGENCY

CONTINUED FROM PAGE 5

FIGURE 2

↘ A unilateral adrenal adenoma in a cat.⁸



Bilateral adrenal disease must be managed medically, and cats with unilateral disease for which surgical adrenalectomy is being contemplated should be stabilized medically for several weeks before surgery. It can be very hard to achieve an adequate potassium level with potassium supplementation alone on an outpatient basis.^{2,3} Spironolactone, an aldosterone agonist and mild diuretic, at 1-2mg/kg BID should be used in conjunction with potassium supplementation.^{3,4} Although spironolactone has some mild diuretic effect, it is not potent enough to cause the mildly azotemic cat to worsen at home. However, subcutaneous fluid can easily be added at home to avoid this potential complication. A normal potassium level even when using spironolactone and potassium gluconate together is usually difficult to achieve – but *normal* should not be the goal. Try to keep the serum potassium level at 3.0-4.0mEq/L, which is usually enough to avoid any complications of hypokalemia. Hypertension (>160mmHg) is best treated with amlodipine at

0.625-1.25mg/cat SID-BID.⁷ If retinal detachment is present, then BID dosing should be considered to control hypertension quickly and maximize the possibility of retinal reattachment.

The prognosis with medical management alone is very good, and survival times can be measured in years.³ Cats on medical management will need to remain on medication lifelong and have occasional BP and renal panel assessment. It is common for azotemia to gradually worsen over months to years due to imperfect control of hypertension and the profibrotic effects of aldosterone which further damages the kidneys.

If a unilateral adrenal mass or enlargement is identified, then surgical management is often the treatment of choice. Left adrenal tumors are easier to access than right-sided masses since the right kidney and adrenal gland are tucked up in the renal fossa of the liver, making access challenging. Once the affected adrenal gland is removed, the prior

hypertension and hypokalemia resolve quite quickly, and no further medication is needed. The benefit of surgery for unilateral adrenal disease is that medications can be stopped and the gradually detrimental renal effects of excess aldosterone secretion can be avoided. Survival times following adrenalectomy for an adrenal cortical adenoma or an adrenal carcinoma were not significantly different with a combined median survival time of 1,297 days.² Carcinomas and adenomas are identified with about the same frequency.^{2,3}

REFERENCES

- 1 JW Conn. Primary Aldosteronism. *J Lab Clin Med* 1955;45:661-664.
- 2 AJ Lo, et al. Treatment of aldosterone-secreting adrenocortical tumors in cats by unilateral adrenalectomy: 10 cases (2002-1012). *J Vet Intern Med* 2014;28:137-143.
- 3 RA Ash, A Harvey, S Tasker. Primary hyperaldosteronism in the cat: a series of 13 cases. *J Fel Med Surg* 2005;7:173-182.
- 4 S Djajadiningrat-Laanen, S Galac, H Kooistra. Primary hyperaldosteronism—expanding the diagnostic net. *J Fel Med Surg* 2011;13:641-650.
- 5 TN Hammond, JL Holm. Successful use of short-term mechanical ventilation to manage respiratory failure secondary to profound hypokalemia in a cat with hyperaldosteronism. *J Vet Emerg Crit Care* 2008;18(5):517-525.
- 6 S Haldane, et al. Profound Hypokalemia Causing Respiratory Failure in a Cat with Hyperaldosteronism. *J Vet Emerg Crit Care* 2007;17(2):202-207.
- 7 J Bisignano, DS Bruyette. Feline hyperaldosteronism: treatment and prognosis 2012. *Vet Med*;107(3):118-125.
- 8 J Bisignano, DS Bruyette. Feline hyperaldosteronism: recognition and diagnosis 2012. *Vet Med*;107(3):118-125.



Navigating Corneal Ulcerative Disasters in Dogs

Daniel Biros, DVM, DACVO

angell.org/eyes | ophthalmology@angell.org | 617 541-5095

INTRODUCTION

The corneal ulcer condition represents a wide spectrum of disease from the smallest surface abrasion to the total loss of corneal stroma, leading to a complete descemetocele (Figure 1) or corneal rupture. As such, the prognosis and treatment plans vary as much as all the different types of corneal ulcerative disease we see. Small injuries can heal with time and symptomatic treatment, while complicated disease requires weeks of treatment and possibly single or multiple surgeries just to preserve the eye and vision. Wound repair of the cornea demands that there be minimal scarring and structural integrity in order to avoid functional vision loss. In veterinary medicine, fortunately, we are not faced with the same rigors of vision demands by contrast to human vision needs, so there is some “wiggle room” to allow for scarring and partial vision loss. In general, steroid or NSAIDs in topical form are to be avoided during the wound repair period and even afterward due to their collagenolytic activity; even though in humans, topical steroids and topical NSAIDs can be used to reduce scarring and preserve visual acuity and cosmesis with judicious use during ulcer healing.

The broad points of care in every ulcerated cornea are: addressing the primary cause of the ulcer, infection control, pain and inflammation management, and wound repair. These four priorities must be addressed in every patient. Often, the acute treatment plan for severe ulcerative keratitis is intense, and the monitoring necessary is often day to day. Recovery can take weeks to months in some cases, and medical treatment can be augmented by surgical repair and stabilization by referral in the most severe situations. Under certain conditions relapse is a concern, especially in the most vulnerable, including brachycephalics, those with difficult-to-treat dry eye, and those suffering from canine ocular herpes, to name three examples.

Walking through the experience of managing complicated corneal ulcers, there are six achievement goals on which we will focus:

- I. Create the environment for a safe and productive examination.
- II. Establish parameters of the wound area including size and stability.
- III. Look for common problems that can create a severe ulcer.
- IV. Consider advanced diagnostics to speed the characterization of the condition and direct therapy.
- V. Put a definitive plan in place for monitoring and therapy adjustment, but be ready to adjust treatment on the go.
- VI. Educate the client to the realities of significant corneal disease including discussions on outlook for vision and comfort. Set realistic expectations.

I. Create the environment for a safe and productive examination

The essential part of a successful corneal examination lies in getting a good and long look at the ocular surface and the anterior chamber, evaluating the adnexa, and checking the vision status of the affected eye. Comfortable and secure manual restraint with the aid of a systemic pain medication as needed (methadone, buprenorphine) will neutralize some of the anxiety of the patient, and topical anesthesia is almost always implemented (e.g., proparacaine) when there is marked blepharospasm. If possible, any cultures of the ocular surface should be taken prior to topical anesthetic since the topical drops may affect the culture results. Any crusting or thick mucus should be wiped away carefully so as to not cause significant disturbance to the cornea in case it has or is near rupture. After topical anesthetic has taken effect (up to 5 minutes for full effect lasting 30 minutes) and the cornea is not fully visible due to mucus, you may consider gently irrigating the surface area with saline to reveal the ocular surface. Care must be taken if blood or fibrin is suspected which could indicate

a leaking cornea or recent leak due to a full thickness perforation or puncture.

II. Establish parameters of the wound area including size and stability

Careful documentation of the wound will be important to monitor progress and guide prognosis. Is it deep? What is the diameter or other dimensions of the surface area? Are the wound edges discreet or blurred? Is there any evidence of leaks? Can you visualize the anterior chamber and is there any blood, fibrin, hypopyon, or synechiae abutting the corneal surface? Once the visualization of the cornea is possible, culture swabs should be gently taken and set aside if there are indications for it, such as stromal melting, especially if ulceration is superficial stromal or deeper. We often use cytology brushes (Microbrush brand) to test the stability of the corneal surface, explore briefly the depth or extent of corneal lacerations, dislodge superficial foreign bodies, and differentiate possible mucus from fibrin plugs. Photography is often helpful to document the wound over time, and, with experience, estimating dimensions of wounds is a good practice to have some objective data in the medical record. Illustrations are also very helpful for characterizing the lesion and are done with every eye examination we do. If there is aqueous humor leakage suspected or if you suspect the eye will leak with any manipulation, then touching the tissue should be minimized until in a safe surgical setting or until the wound has stabilized sufficiently on its own with time and supportive care.

III. Look for common problems that can create a severe ulcer

Once the patient is comfortable for evaluation and the wound area has been initially checked, a look around the injury is essential at better characterizing the conditions that may have led to the changes seen. With a good history, you may be inclined to look for other associated ocular disease such as lagophthalmos, distichiae, ectopic

(CONTINUED ON PAGE 8)

OPHTHALMOLOGY

CONTINUED FROM PAGE 7

ilia, dry eye, or foreign bodies that could be directly involved with the pathology. Some of these conditions can be addressed on the spot while others may need long-term care. Remember, a Schirmer tear test will be lower in patients who have received topical proparacaine, so this test may be skipped until the eye is more stable.

IV. Consider advanced diagnostics to speed the characterization of the condition and direct therapy

The core ophthalmic tests for most eye exams include a testing for a menace response, pupillary light reflexes, palpebral reflexes, Schirmer tear test, tonometry, fluorescein stain, and visualization of the eyelids, conjunctiva, cornea, anterior chamber, lens, and fundus (retina). In severe corneal disease, additional testing can also involve aerobic bacterial corneal culture, fungal culture, cytology, Seidel testing for leakage of the aqueous humor through the cornea, and PCR testing for herpes. In an emergency situation, all tests may not be possible or indicated, but in complicated corneal ulcers where there has been chronic antibacterial treatment or rapid progression of the ulcer size and depth despite therapy, culture first (with option for submission later on) and then cytology may be most helpful. Aerobic culture should be sufficient when looking at types of cultures to submit in New England, but in some geographic areas fungal testing would be warranted (e.g. the South). Cytology can be Diff-Quik or gram stain, and done in clinic or sent off to a cytologist. Seidel testing is a variation on the fluorescein test where the test strip is actually applied in contact briefly to an area of cornea suspected of leakage – whether an ulcer, a tear, or a surgical incision – leaving a concentrated area of fluorescein on the corneal surface which is bright orange. If there is a leak, the orange will quickly change to green and often the green streaks that result in a leaking cornea will track the course of the aqueous humor along the ocular surface. The eyelids have to be kept open to have good test results as fluid from tears or even eye wash will also cause the same type of dilution. The patient has to be very still for the test to be interpreted properly and any excess mucus or fluid on the ocular surface rinsed away to get the best view of the test.

V. Put a definitive plan in place for monitoring and therapy adjustment, but be ready for adjusting treatment on the go

Treatment plans for severe corneal ulcers are often quite labor intensive and in the case of melting ulcers, recommendations of up to three meds hourly for several days is one standard approach to reverse the rapid melting process and save the eye. By now, cultures and cytology are turned in and there is likely CBC and

FIGURE 1

↘ Five- to eight-mm diameter descemetocoele with a darkened non-fluorescein stain uptake in the ulcer bed, but fluorescein retention at the wound edges where there is still stroma exposed. Despite robust vascularization superior to the ulcer, this wound has developed due to low tear production (note the dried mucus at the eyelids), corneal exposure from a poor blink response, and a poor location that is a lengthy distance from the corneal blood vessel supply (endogenous wound repair). Conjunctival grafting should be considered in this situation as well as addressing the causes for the poor blinking and dryness in order to preserve vision and accelerate healing.

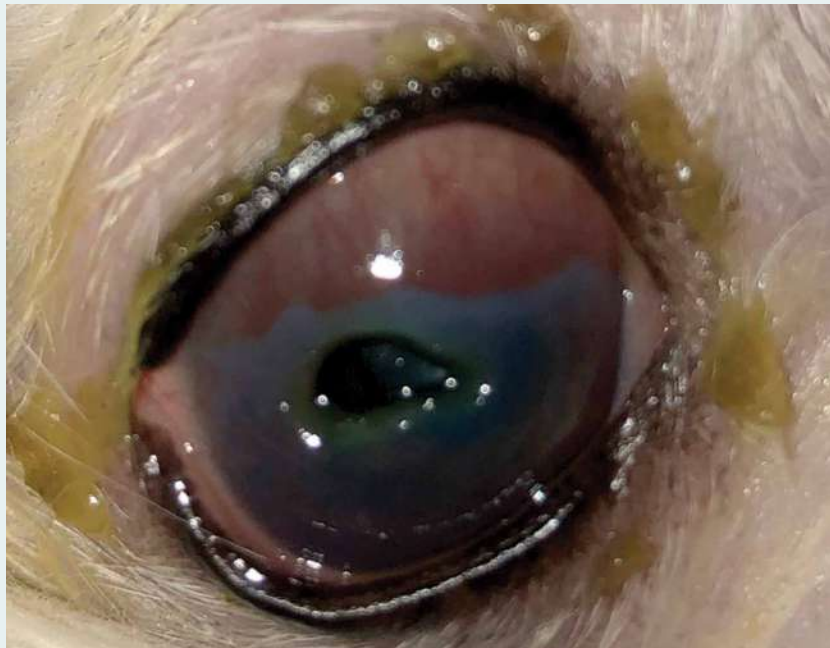
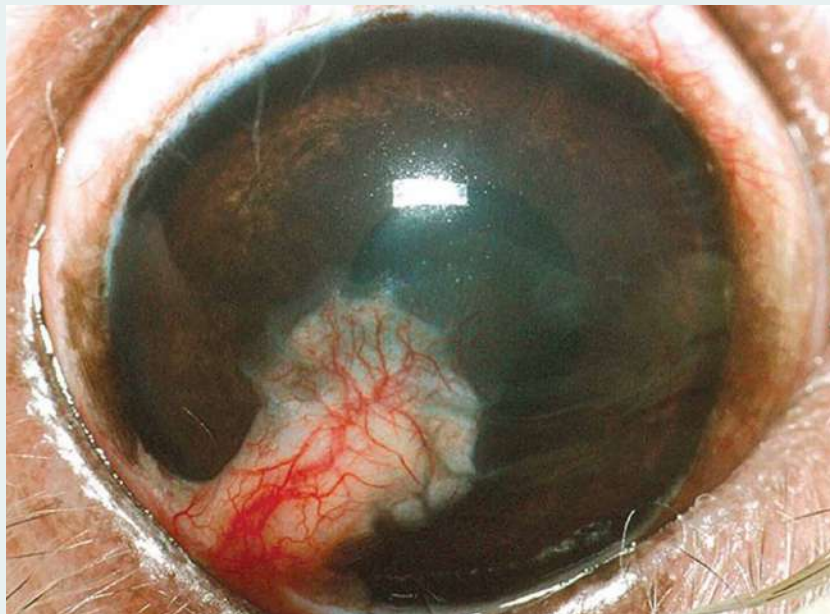


FIGURE 2

↘ The appearance of a conjunctival graft weeks post surgery for wound stabilization and repair of a deep ulcer (Courtesy Willows Vet).



chemistry panel results that will help focus the options for systemic care. In specialty care clinics with 24-hour services, round-the-clock care can be offered to lessen the burden of care and allow the clients to get some sleep. Making sure the patient's anxiety is as low as possible will also help them take the medication without the added problems of nausea, inappetence, high blood pressure, or aggression. Unless there is high risk from anesthesia, surgical stabilization by referral with conjunctival grafting is often offered when the ulceration is large, deep, or actively leaking and the leak is no larger than 5-7 mm (Figure 2). Risks for graft failure go up with larger injury (larger graft), but recent advancements in grafting options including amniotic membrane, synthetic or biological collagen implants over the wound area; collagen cross linking; and even corneal transplants in certain situations are used to save an eye that would otherwise be lost to medical therapy alone or that would greatly accelerate the wound healing process. There is also benefit, if possible, to stabilize the cornea with medication for up to 24-48 hours prior to moving to surgical correction of the corneal ulcer. Grafts fail when the inflammation is profound and the grafts succumb to neutrophilic digestion. However, with a few days of anti-inflammatory and antibiotic care, the surgical field can become more stable and accepting of grafts.

We will often use during hospitalization ofloxacin, cefazolin (compounded to 55 mg/ml in bacteriostatic water – refrigerated – good for at least two weeks), and whole serum diluted up to 25-50% with artificial tears up to every hour for up to 3-4 days to start intensive treatment for a melting ulcer and then taper down to a frequency that the clients can handle at home once the wound is showing signs of repair. Atropine use can be very helpful, especially if the uveitis is profound, and can be used up to 4-6 times daily initially to dilate the pupil at the onset of treatment, but then tapered to the lower effective frequency to sustain dilation, often 1-2 times daily. If profound uveitis with hyphema or hypopyon, systemic antibiotics are suitable to reach therapeutic intraocular concentrations. Systemic pain medication includes carprofen and gabapentin. We also will use methadone, meloxicam, and other options depending on the patient's weight and history with these drugs. Trazadone can also be helpful if there is high anxiety, and cerenia or similar is often used during hospitalization if there is any perceived risk for nausea. When to send a patient with a healing ulcer for home care will depend on what the pet owner can do and how stable the pet is. In general, we like to string together 2-3 successive days of improvement,

feel confident the wound is not going to destabilize, and try to get the treatments down to at most every 4-6 hours.

VI. Educate the client to the realities of significant corneal disease including discussions on outlook for vision and comfort. Set realistic expectations.

Despite the best intentions of intensive medical therapy, some patients are poor responders, and if we don't see improvement in 3-4 days at the latest, we will discuss options in replacement of or in addition to the medical therapy already implemented. Obvious cases that would have us consider surgical referral immediately would be those where the cornea is already perforated or perforation is imminent. Descemetocelles and deep ulcers also are considered for the fast track to surgical referral (Figure 1) if the patient is stable and the goal of care will enable the preservation of some vision – or just keeping the eye, knowing it will be blind if the client is averse to enucleation. If the cornea is beyond repair, having considered both surgery and medication options, then we can offer enucleation as the humane course of therapy for the severest cases to alleviate pain and speed the recovery quickly. For some the financial costs are too strenuous for intensive medical care, and the clients are not equipped to treat at home to meet the needs of the patient. There is nothing lost if the client wants to treat intensively at home to the best of their ability with reasonable rechecks every day or so. Initial testing and evaluation for a melting ulcer on emergency, including evaluation, tests, cultures, and medication, can be upward of \$800. If the patient stays for intensive eye care in hospital, the cost can be up to \$500 per day. Urgent surgery to repair a severely damaged cornea can cost in the range of \$2,500 to \$3,500 for the surgery and post-op care alone.

SUMMARY

Basic training in managing corneal ulceration does not always prepare one for dealing with advanced cases of corneal melting or large, deep ulcerative conditions. By considering additional steps in the path of diagnosing and treating ulcerative keratitis, some advanced cases may continue to have vision with ramped-up medical and or surgical treatment by referral. The vision survival rate for serious corneal ulcers in dogs is going to be lower by contrast to patients with less serious ulcers, but with some adjustments to conventional therapy, many of these cases can stand a better chance to heal with functional vision.

ADDITIONAL READING

- Dan G. O'Neill, Monica M. Lee, Dave C. Brodbelt, David B. Church, and Rick F. Sanchez. Corneal ulcerative disease in dogs under primary veterinary care in England: epidemiology and clinical management. *Canine Genet Epidemiol.* 2017; 4: 5.
- Pot SA1, Gallhöfer NS, Matheis FL, Voelter-Ratson K, Hafezi F, Spiess BM. Corneal collagen cross-linking as treatment for infectious and noninfectious corneal melting in cats and dogs: results of a prospective, nonrandomized, controlled trial. *Vet Ophthalmol.* 2014 Jul;17(4):250-60.
- Ledbetter EC1, Franklin-Guild RJ2, Edelman ML1. Capnocytophaga keratitis in dogs: clinical, histopathologic, and microbiologic features of seven cases. *Vet Ophthalmol.* 2018 Nov;21(6):638-645.
- Ledbetter EC1, Riis RC, Kern TJ, Haley NJ, Schatzberg SJ. Corneal ulceration associated with naturally occurring canine herpesvirus-1 infection in two adult dogs. *J Am Vet Med Assoc.* 2006 Aug 1;229(3):376-84.
- Wilkie, David A. et al. Surgery of the Cornea. In *Veterinary Clinics: Small Animal Practice*, Volume 27, Issue 5, 1067-1107.
- Ledbetter EC, Gilger BC. Diseases and surgery of the canine cornea and sclera. In: Gelatt KN, Gilger BC, Kern TJ, editors. *Veterinary Ophthalmology*, vol. 2. 5th ed. Oxford: Wiley-Blackwell; 2013. p. 976-1049.
- Vanore M, Chahory S, Payen G, Clerc B. Surgical repair of deep melting ulcers with porcine small intestinal submucosa (SIS) graft in dogs and cats. *Vet Ophthalmol.* 2007;10(2):93-9.
- Lacerda RP, Peña Gimenez MT, Laguna F, Costa D, Rios J, Leiva M. Corneal grafting for the treatment of full-thickness corneal defects in dogs: a review of 50 cases. *Vet Ophthalmol.* 2016;1-10.



Leptospirosis

Shawn Kearns, DVM, DACVIM

angell.org/internalmedicine | internalmedicine@angell.org | 617 541-5186

DISEASE DESCRIPTION

Epidemiology

Leptospirosis is a disease caused by infection with an aerobic, filamentous, gram-negative, motile spirochete (bacteria) of the genus *Leptospira*. The main species affecting dogs in the United States are *L. interrogans* and *L. kirshchneri*.¹ *Leptospira* species are made up of over 250 serovars (antigenically distinct organisms in the same species) that are divided into serogroups (antigenically related serovars that may cross-react on antibody detection methods). Of the 20 serogroups identified, approximately 10 are considered pathogenic in dogs. The most common serogroups and their reservoir hosts include Canicola (dog), Icterohaemorrhagiae (rat), Grippityphosa (raccoon, skunk, marsupials), Pomona (cow, pig), Hardjo (cow), Bratislava (rat, pig, horse), and Autumnalis (mouse).^{2,3} These seven are the groups typically evaluated on titer testing. Prevalence of groups varies by geographic region. In contrast to dogs, few cases of clinical leptospirosis have been reported in cat and seroprevalence is variable based on regions examined.^{2,4}

Leptospiral organisms prefer warm, moist, alkaline environments. They are more likely to be found in stagnant or slow-moving water. Incidence of infection increases in late summer to fall (July-November) and after flooding or heavy rainfall.^{2,5,6} Environmental flooding can saturate the soil with organisms, prevent evaporation of contaminating animal urine, and prolong survival of organisms in surface water. *Leptospira* spp. can remain viable for months in moist environments under optimal conditions even though they cannot replicate outside the host body. *Leptospira* spp. remain in the environment through infection of reservoir hosts who maintain a carrier state, often without clinical illness.

Leptospirosis has been documented throughout the United States with pockets of increased prevalence in certain areas including Virginia, West Virginia, the West Coast, and around the Great Lakes region.⁷ Other studies have shown an increased prevalence in the Northeast, Midwest and South Central areas of the United States.⁸ Prevalence studies do not always take into account recent rainfall or flooding which may alter



prevalence season to season. Exposure to livestock and wildlife, crowded kennels, rodent exposure in urban environments, houses on large lots, deciduous forest land, increased precipitation, and temperature have been noted as risk factors for exposure and/or infection.^{5,7,9}

Signalment

Although any breed can be affected, herding dogs, hounds, working dogs, and mixed breed dogs are at greatest risk due to increased environmental exposure.^{6,10} However, other studies have shown 40-50% of dogs to be of small or intermediate breeds.^{11,12,13} Dogs of any age are at risk, but the lowest seroprevalence has been reported in dogs >10 years.¹⁴ Younger dogs (<6 months of age) are more likely to have severe clinical signs and severe hepatic involvement compared to adult dogs.¹⁵

Transmission

The primary mode of transmission in animals is through contact with infected urine or through indirect transmission via exposure to water sources, soil, food, or bedding that is contaminated with infected urine or tissue. Transmission via venereal or placental transfer, bite wounds, or ingestion of tissues is much less common.

Pathophysiology

Leptospire penetrate mucous membranes, wet or macerated skin, and broken skin, after which they

enter the blood stream and quickly multiply. Organisms attach to endothelial cells and cause vasculitis, vascular leakage, hemorrhage, and inflammation. The bacteremic phase can last for up to 10 days.¹⁶ Organisms then spread and replicate in many organs. Within the kidneys, organisms penetrate the renal capillaries and enter the interstitium. Leptospire are found within proximal renal tubular cells and tubular lumen, leading to organisms being shed in the urine. Leptospire can persist in the kidneys and be shed in the urine for weeks to months without treatment. Kidney swelling can impair renal perfusion and decrease glomerular filtration. Endothelial damage also leads to ischemic injury within the kidney. The lipopolysaccharide (LPS) component of the outer envelope of leptospire activates macrophages, stimulates neutrophil adherence, causes platelet activation, and stimulates the release of pro-inflammatory cytokines.² Infection with serogroups Canicola, Bratislava, and Grippityphosa are more commonly associated with renal dysfunction.

The liver is the second main organ affected by leptospire. Hepatic dysfunction can occur from damage by leptospiral toxin with subsequent centrilobular necrosis, bile duct occlusion, fibrosis, and chronic hepatitis.^{2,3} Hepatitis may be granulomatous or lymphoplasmacytic/neutrophilic in type. One study of 10 dogs with

leptospirosis demonstrated chronic hepatitis without clinical evidence of prominent renal involvement.¹⁷ Acute liver failure without renal involvement may also occur.¹⁸ Serogroups Icterohaemorrhagiae and Pomona are more associated with hepatic involvement.^{2,19}

Pulmonary abnormalities can occur secondary to the effects of the leptospiral toxin on lung tissue, and from fluid exudation secondary to vasculitis.² Leptospiral pulmonary hemorrhagic syndrome (LPHS) is increasingly recognized in dogs with acute leptospirosis.²⁰ Intra-alveolar hemorrhage in the absence of marked inflammatory cell infiltrate has been documented. LPHS is associated with high mortality rates (up to 70%).^{21,22}

Bleeding abnormalities from abnormal primary or secondary hemostasis can also occur. Vasculitis, thrombocytopenia, and disseminated intravascular coagulation all may play a role in bleeding diatheses. Thrombocytopenia may result from platelet consumption, adhesion, and aggregation due to stimulated vascular endothelium, increased platelet consumption due to immune causes, hemophagocytic syndrome, or a combination of factors. In one study of 35 affected dogs, 14 (40%) were hypercoagulable, 7 (20%) were hypocoagulable and 40% had a normal profile. In this same study, 23% of dogs were considered to have DIC but this did not influence prognosis. The mortality rate was lower, however, in patients that were hypercoagulable versus those that were hypocoagulable.²³

Anti-leptospiral IgM antibodies are detected in the first week of infection, increasing rapidly early in infection. Anti-leptospiral IgG antibodies increase to detectable levels approximately 2 weeks after infection. These principles can help understand pitfalls of testing (below).

History/Physical Examination Findings

Leptospirosis can manifest as peracute, acute, subacute, or chronic disease. Young patients tend to have more severe clinical signs compared to older patients. Clinical signs are often non-specific or relate to the primary target organs damaged. Gastrointestinal signs (vomiting, decreased appetite, diarrhea), lethargy, polyuria, and polydipsia are most commonly noted in the history. Pulmonary, ocular, and central nervous systems signs are less common. Exam findings are often due to dehydration and/or hypovolemia, but some patients may have just fever, PU/PD, or myalgia as the initial presenting complaint.

Complete Blood Count

As with historical and exam findings, CBC changes are non-specific. Changes may include a leukopenia during the leptospiremic phase and may be followed by leukocytosis, with or

without a left shift. Anemia (up to 63%) and thrombocytopenia (up to 58%) may also be present or develop during the disease course.^{1,11,24} Those infected with serogroup Pomona may be more likely to be thrombocytopenic.

Biochemistry Panel

Most (87-100%) dogs with leptospirosis are azotemic but the azotemia can vary quite a bit in severity. Electrolyte abnormalities (hyponatremia, hypochloremia, hypokalemia, hyperkalemia, hypophosphatemia, and/or hyperphosphatemia), as well as metabolic acidosis are commonly present. Hypokalemia may be due to both renal and gastrointestinal loss, however leptospiral glycolipoprotein also directly inhibits expression and functions of the tubular Na⁺-K⁺-ATPase.¹¹ Hypoalbuminemia was also a common finding in one study.¹⁹ More severe azotemia has been noted with Serogroup Pomona.²⁴

Hepatic disease is usually less severe than renal disease, with increased hepatic enzymes (ALT, ALP, AST, bilirubin) often occurring up to a week after the onset of azotemia.²⁵ Hepatic disease may also be noted in the absence of renal disease.¹⁹ Elevation of ALP is usually greater than the increase in ALT activity. In one study, 80% of dogs with leptospirosis had increased liver enzyme activities, and 69% were hyperbilirubinemic.¹¹ Chronic hepatitis (granulomatous) without prominent renal involvement has also been reported¹⁷, however, proving a prior infection may be difficult in many patients.

Elevated creatine kinase has been reported in ~43% of cases of leptospirosis associated with myositis.²⁶

Urinalysis

Results from urinalysis usually are non-specific and consistent with tubular damage. Changes may include hyposthenuria, glucosuria, proteinuria, and hyperbilirubinuria. Proteinuria is variable but in one report ranged from 0.15 to 7.34 as determined by a urine protein:creatinine ratio.¹⁹ Sediment examination can reveal red blood cells, white blood cells, and granular casts.

DIAGNOSTIC IMAGING

Radiography

Pulmonary involvement has been reported in dogs with leptospirosis with thoracic radiograph abnormalities noted in up to 70% of cases.^{11,19,22} As radiographic changes may be seen without clinical signs of respiratory distress,^{11,19} thoracic radiographs are recommended as part of the initial diagnostic plan for patients suspect to have leptospirosis. Clinical signs of respiratory disease may develop over the course of the disease progression even if not apparently initially. Interstitial to nodular alveolar densities or alveolar consolidation may be seen on thoracic

radiographs.¹¹ Patients with LPHS typically have abnormalities that initially appear bilaterally in the caudal-dorsal lung fields.²¹ LPHS is thought to be have an immune-mediated basis in people and is associated with a high mortality. This syndrome is more commonly seen in Europe.²²

Ultrasonography

Ultrasound changes are noted in 85-100% of dogs but are non-specific in nature. Changes detected in the kidneys include renomegaly, pyelectasia, increased cortical echogenicity, perinephric effusion, reduced corticomedullary definition, and a medullary band of increased echogenicity (medullary rim sign).^{2,21,25,27} In one study of 35 dogs with leptospirosis, 100% had increased cortical echogenicity.²⁸ Changes seen in other abdominal organs include hypoechogenicity of the pancreas, pancreatic enlargement, thickening of the gastric and intestinal walls, splenomegaly with a mottled splenic echotexture, hepatic hypoechogenicity, gallbladder mucocele, biliary wall thickening, biliary sludge, and lymphadenomegaly.^{1,21,28} None of these changes are considered specific for leptospirosis, however.

Clotting Tests

Patients with leptospirosis may be hypo- or hypercoagulable, so coagulation testing results can be variable. Prolongation of PT and aPTT have been reported in 6-50% of dogs.^{1,29} Elevated fibrinogen, d-dimer and fibrinogen degradation products has been reported as well as decreased antithrombin III activity.²³ The exact pathophysiologic mechanisms of bleeding in dogs and humans is not well understood but is suspected to be due to hepatic failure, disseminated intravascular coagulation, and/or direct vascular damage from the spirochetes.

LEPTOSPIROSIS SPECIFIC TESTING

Two main categories of diagnostic testing are available: tests that detect bacteria directly and those that detect antibodies directed against *Leptospira spp.* Direct testing via culture or visualization via dark field microscopy are rarely used in clinical practice due to low sensitivity and for cultures, a long incubation time.

Polymerase Chain Reaction (PCR) Assay

Detection of bacterial DNA using polymerase chain reaction (PCR) is the most commonly used direct testing. Direct testing is most useful prior to antibiotic administration and early in the course of the disease when bacterial numbers are highest in blood and urine. Blood is the sample of choice during the first week of infection since organism numbers are highest in blood at that time. After ~10

(CONTINUED ON PAGE 12)

days of infection, organisms are found in greater numbers in urine. If the time of infection is unknown, which is most common, both blood and urine should be submitted to reduce the chance of false-negative results.¹ Samples should be obtained prior to starting antibiotic therapy due to a high chance of a false negative after starting antibiotics.³⁰ PCR assays may detect organisms in subclinical carriers and should be considered in patients that may present with only mild signs such as non-azotemic polyuria and polydipsia.² Recent vaccination can interfere with real-time PCR detection of leptospires.²¹ Current commercial PCR assays do not determine the infecting serovar. This generally does not impact management, however information on infecting serovars improves our understanding of epidemiology and is important for vaccine development. In asymptomatic dogs, a positive PCR could indicate a chronic carrier state but prevalence varies by regions. Unfortunately, there are limited studies evaluating the performance of these assays. One blood-based PCR assay had a sensitivity of 86% in the first 6 days of infection but this drops to 34% at day 7.

Microscopic Agglutination Test (MAT)

The MAT has been the most commonly used test for leptospirosis in animals. The highest dilution of serum that agglutinates 50% of leptospiral organisms is the titer reported, with agglutination being triggered by both IgM and IgG antibodies. The magnitude of circulating IgM specific to leptospiral lipopolysaccharide plays a major role in the agglutination of leptospires in MAT but these do not usually appear until ~day 8 post infection. This may help explain negative results earlier in the course of disease along with a lag in IgG production.³² In addition, the highest titer does not always correlate with the infecting serovar and there may be considerable variability in results among different laboratories.

A single positive titer of $\geq 1:800$ to a serogroup not covered by vaccination is *suggestive* of infection in a dog with compatible clinical signs. One study showed that a single MAT titer of $\geq 1:800$ had a sensitivity of 22-67% depending on the diagnostic laboratory, and a specificity of 69-100%. Paired titers taken 2-4 weeks apart that show a 4-fold increase are also suggestive of active infection. While antibiotic therapy may blunt the antibody response, the 4-fold titer increase is often still present. The sensitivity of MAT testing increases to 100% when using paired titers with a specificity of 70-100%. Due to serologic cross-reactions among serovars, antibody response does not predict the infecting serovar.^{2,33}

Vaccination can interfere with interpretation of titers, however post-vaccinal titers tend to be low and generally decline over 4 months.³³ Ongoing

exposure to field strains of leptospires may contribute to higher titers, especially to non-vaccinal strains.¹

ELISA

IgM antibodies generally rise during the first week of infection with a maximum value around 2 weeks. IgG is produced in large quantities 1-3 weeks after infection. Due to these differences, the IgM ELISA test is more sensitive at detecting early infection compared to MAT.² The point-of-care tests are based on these antibodies and are used more frequently now.

Point-of-Care Tests

Point-of-care tests have been developed that detect *Leptospira*-specific antibodies in canine sera.²⁹ The SNAP Lepto (IDEXX) detects antibodies against the LipL32, an abundant membrane protein of *Leptospira*. When MAT titers were $\geq 1:800$, there was agreement found between MAT and SNAP Lepto in 83.2% of cases.³³ The highest agreement was found when MAT was $> 1:3200$ but titers of this magnitude are often not seen until a couple of weeks into the course of the disease.³⁵ In clinical practice, the SNAP Lepto was positive in 15/22 dogs that were confirmed to have leptospirosis but also identified 20/131 (15%) as a false positive.³⁴ Vaccinal antibodies are detected with the SNAP Lepto and positives from vaccination have been seen up to 1 year post-vaccine.³⁴

The WITNESS[®] Lepto detects IgM antibodies using whole cell extracts from *L. kirschneri* sv Grippotyphosa and *L. interrogans* sv Bratislava. In one study, the sensitivity was 98% and specificity 93.5% compared with diagnosis obtained via MAT. Another study of acute clinical cases found a sensitivity of 75% compared to only 24% for MAT in dogs that were later diagnosed by a rise in MAT titer or positive PCR. Twenty-four percent of dogs tested post vaccination had cross-reactive antibodies at 12 weeks.³²

There are two reports comparing the three main antibody tests currently available (single MAT, Witness Lepto and SNAP Lepto). In a study of 89 dogs, the sensitivities for the three tests were 70.3% (MAT), 86.5% SNAP Lepto, and 78.9% Witness Lepto while specificity was 10%, 97.6%, and 75% respectively. A 4-fold rise in MAT was used for the final diagnosis. In another study of 32 dogs experimentally infected, the WITNESS[®] Lepto (Zoetis) identified seroconversion in all dogs by day 10 while MAT identified seroconversion in 30/32 dogs by day 14 post infection. The SNAP[®] Lepto (IDEXX) test detected seroconversion in 3 dogs during the first 14 days.³² Sensitivity was 98% and specificity was 93.5% for WITNESS[®] Lepto when compared to MAT. Differences in the sensitivity for these tests

may be related to sample timing after infection and/or the infecting serovar, which is usually not known at the time of testing.

In a European study comparing WITNESS[®] Lepto and Test-it[™] Leptospira Canine IgM lateral flow assay, a diagnosis of leptospirosis would have been overlooked in 21.4% (MAT) and 24% (Point of Care) of true positives if convalescent testing had not been performed.³⁶

Given the zoonotic potential and the potential reversibility of acute kidney injury, obtaining a definitive diagnosis is important. As such, at Angell we would typically recommend a combination of testing for patients. If antibiotic therapy has not been instituted, we generally recommend both a PCR-based test (typically blood and urine) as well as antibody testing (Witness Lepto) +/- MAT titers. If a point-of-care test is positive, with no vaccinal history, this would be highly suggestive of disease. If a point-of-care test is positive with any vaccinal history, paired MAT titers are considered unless a positive PCR test returns.

TREATMENT/MANAGEMENT/ PREVENTION

Specific therapy

Based on the 2010 ACVIM Consensus Statement on Leptospirosis, doxycycline at 5 mg/kg PO or IV q 12 hrs for 2 weeks is the treatment of choice as it will eliminate the renal carrier state, unlike penicillins. The true optimal duration of therapy remains unknown at this time. If doxycycline is not tolerated, ampicillin or penicillin G can be used but dose reduction should be considered in azotemic patients. Although test samples should be collected prior to antibiotic therapy (ideally), treatment should not be withheld while waiting for the results of testing.

Supportive therapy

The mainstay of supportive therapy is correcting fluid and electrolyte imbalances, providing anti-nausea and anti-vomiting treatments, and providing nutrition. Supportive therapies for the liver are also administered as needed, such as antioxidants (e.g., SAME) and cholagogues (e.g., ursodeoxycholic acid). Other therapies will be dependent on the severity of clinical signs (i.e., oxygen support if there are signs of respiratory distress). If a patient is suspected to be oliguric, anuric, experiencing signs of fluid overload, or having a progressive rise in renal values, referral for dialysis should be considered. Though the overall survival for acute kidney injury with or without dialysis treatment is only ~50%, infectious etiologies, including leptospirosis, have a much better survival rate (~80-90%).^{37,38} Recovery of adequate renal function usually occurs within 2-4 weeks of starting dialysis

and some patients may only need 1-3 treatments before polyuria occurs. Early hemodialysis in humans has been associated with increased survival and shorter hospital stays. Per the consensus statement, renal replacement therapy should be considered in patients with inadequate urine output developing volume overload, hyperkalemia, BUN > 80mg/dL, or signs of uremia that are not responsive to medical management.

Patients with LPHS may require oxygen therapy or even mechanical ventilation. Studies in humans with LPHS show improved outcome after cyclophosphamide and plasma exchange. Studies are needed in dogs to determine the benefit of other therapies.

Monitoring

Patients presenting with signs of acute kidney injury with or without liver involvement require intense monitoring. Blood work is most often monitored daily to watch for any progression of azotemia, development of hepatic involvement, and to ensure stable electrolytes. For dogs with acute leptospirosis, biochemistry profiles are evaluated every 24 hours. Monitoring for oliguria, anuria, and fluid overload is accomplished primarily through quantitative urine output (indwelling urinary catheter) versus fluid intake as well as serial body weight measurements. Dogs with non-oliguric renal failure may be severely polyuric, so more precise measurement of ins and outs is warranted to ensure adequate replacement of these fluid losses.

Despite clinical improvement, laboratory abnormalities may persist for several weeks and require follow-up visits to monitor for resolution. While azotemia often will resolve in 10-14 days, hepatic recovery may take longer in some patients. Additionally, chronic kidney disease may develop in up to 50% of patients that survive the acute phase of leptospiremia.^{38,39} Interestingly, a recent report from an area known to be endemic for leptospira, showed that many dogs with chronic kidney disease, and no known prior infection of leptospirosis, were positive on urine PCR.⁴⁰ The relationship between chronic kidney disease and leptospirosis in the absence of a known acute infection requires further study.

Prognosis

Leptospirosis is typically very responsive to appropriate antibiotic therapy. Survival rates are reported to be 80-90%.²⁵ Dogs with pulmonary disease and multi-organ involvement have a poorer prognosis.^{1,21} Infection with serogroup Pomona has also been associated with more severe renal disease and poorer outcomes.²⁴

PREVENTIVE MEASURES

Vaccination

Currently a bacterin containing four serogroups (Canicola, Icterohaemorrhagiae, Grippotyphosa, Pomona) is available in North America for prevention of leptospirosis and has been shown to provide protection for up to 1 year.⁴¹ These vaccines are not completely cross-protective against other serovars that can cause disease, so it is still possible to develop post-vaccinal leptospirosis from infection with other serovars.^{2,19} Naturally occurring leptospirosis has been reported in dogs vaccinated with the original bivalent and the currently available quadrivalent vaccines.^{1,41} However, disease in vaccinated patients is uncommon. Challenge studies for the vaccines show a significant reduction in mortality rates, leptospiremia, and for some, leptospiuria. Initial immunization involves 2-3 injections at 2-3 week intervals, with numerous studies demonstrating immunity to challenge infection. Vaccines have been shown to protect against serogroups in the vaccine for at least 6-8 months, and some report protection for 12 months. Vaccines must be administered annually. Although reactions can occur after vaccination with leptospirosis, these vaccines are considered to be no more reactive than other vaccines administered to dogs.^{1,2}

Other preventative measures

Other methods of prevention include decreased access to potential sources of infection, such as marshy areas and/or standing water and minimizing wild animal contact by use of fencing and rodent control measures.

ZOO NOTIC POTENTIAL

Leptospirosis is a zoonotic disease. People can become infected through occupational or recreational exposure (boating, fresh water swimming). Veterinarians, farmers, animal caretakers, and sewer system workers are at increased risk as are children and immunocompromised people.⁴² Dogs with leptospirosis are a potential source of infection for people, so contact with urine from infected animals should be avoided.^{42,43}

All dogs with acute renal failure, including acute and chronic disease, should be managed as leptospirosis suspected until an alternate diagnosis has been made. Organisms are likely present in blood or urine for 2-3 days after antibiotic therapy is started but the exact duration is not known. Protective clothing, gloves, boots, and eye protection should be used when handling hospitalized dogs. Cages and runs must be disinfected routinely and warning labels should be placed on cages with patients suspected of disease. Leptospire are sensitive to many disinfectants

(e.g., bleach, iodophors, quaternary ammonias) and drying. Pressure washing is not used to clean kennel areas since aerosolization of leptospire can occur. Dogs should not be walked in common areas/hallways nor allowed to urinate in areas used by other dogs.⁴² Any urine spills should be cleaned and disinfected immediately and any hair that is urine soaked should be washed. Laundering will inactivate leptospire but protective clothing should be worn by individuals handling the bedding. If a patient passes away, protective measure should continue when handling the body.

Once a patient is discharged, owners should wear gloves and wash hands when contacting their dog's urine until antimicrobial treatment is completed even though the risk of urinary shedding by the time of discharge is likely low.¹ Patients should still urinate away from standing water, where no other animals or people (especially children), will have access.

Treatment of other dogs in the household that may have been coincidentally exposed to a source of leptospire in the environment is recommended, ideally with monitoring of acute and convalescent titers.

Leptospirosis is considered a reportable disease. The state veterinarian should be contacted with any positive cases.

REFERENCES

- 1 Sykes JE, Hartmann K, Lunn KF, et al. 2010 ACVIM small animal consensus statement on leptospirosis: diagnosis, epidemiology, treatment, and prevention. *J Vet Intern Med* 2011 Vol 25 (1) pp. 1-13.
- 2 Greene CE, Sykes JE, Moore GE, et al. Leptospirosis. *Infectious Diseases of the Dog and Cat*, 4 ed. Elsevier Saunders, St. Louis 2012 pp. 431-47.
- 3 Goldstein RE: Canine Leptospirosis 2010: Update on Diagnosis, Treatment and Prevention. *Western Veterinary Conference* 2010.
- 4 Jamshidi S, Akhavadegan MA, Maazi N, et al. Serologic study of feline leptospirosis in Tehran, Iran. *Iran J Microbiol* 2018 Vol 1 (2) pp. 32-36.
- 5 Grayzel SE, DeBess EE: Characterization of leptospirosis among dogs in Oregon, 2007-2011. *J Am Vet Med Assoc* 2016 Vol 248 (8) pp. 908-15.
- 6 Azócar-Aedo L, Monti G. Meta-Analyses of Factors Associated with Leptospirosis in Domestic Dogs. *Zoonoses Public Health*. 2016 Vol 63 (4) pp. 328-36.

(CONTINUED ON PAGE 14)

- 7 White AW, Zambrana-Torrel C, Allen T, et al. Hotspots of canine leptospirosis in the United States of America. *Vet J* 2017 Vol 222 (0) pp. 29-35.
- 8 Lee HS, Levine M, Guptill-Yoran C. Regional and temporal variations of leptospira seropositivity in dogs in the United States, 2000-2010. *2014*; 28: 779-788.
- 9 Stokes JE, Kaneene JB, Schall WD, et al. Prevalence of serum antibodies against six *Leptospira* serovars in healthy dogs. *J Am Vet Med Assoc* 2007 Vol 230 (11) pp. 1657-1884.
- 10 Lau SF, Wong JY, Khor KH, et al. Seroprevalence of Leptospirosis in Working Dogs. *Top Companion Anim Med* 2017 Vol 32 (4) pp. 121-225.
- 11 Knöpfler S, Mayer-Scholl A, Luge E, et al. Evaluation of clinical, laboratory, imaging findings and outcome in 99 dogs with leptospirosis. *J Small Anim Pract* 2017 Vol 58 (10) pp. 582-88.
- 12 Sykes JE, Bryan J, Armstrong PJ. Comparison of clinical findings associated with canine leptospirosis between two teaching hospitals. *J of Vet Intern Med* 2007; 21: 642.
- 13 Lee HS, Guptill L, Johnson AJ et al. Signalment changes in canine leptospirosis between 1970 and 2009. *J Vet Intern Med* 2014; 28: 294-299.
- 14 Gautam R, Wu CC, Guptill LF, et al. Detection of antibodies against *Leptospira* serovars via microscopic agglutination tests in dogs in the United States, 2000-2007. *J Am Vet Med Assoc* 2010 Vol 237 (3) pp. 293-8.
- 15 Rissi DR, Brown CA: Diagnostic features in 10 naturally occurring cases of acute fatal canine leptospirosis. *J Vet Diagn Invest* 2014 Vol 26 (6) pp. 799-804.
- 16 Greenlee JJ, Alt DP, Bolin CA, et al. Experimental canine leptospirosis caused by *Leptospira interrogans* serovars Pomona and Bratislava. *Am J Vet Res* 2005; 66 (10) 1816-22.
- 17 McCallum KE, Constantino-Casas F, Kortum AJ, et al. Hepatic Leptospirosis Infections Without Prominent Renal Involvement. *J Vet Intern Med* 2019; 33: 141-150.
- 18 Lester C, Cooper J, Peters RM, et al. Retrospective evaluation of acute liver failure in dogs (1995-2012): 49 cases. *J Vet Emerg Crit Care* 2016; 26 (4): 559-567.
- 19 Tangeman LE, Littman MP: Clinicopathologic and atypical features of naturally occurring leptospirosis in dogs: 51 cases (2000-2010). *J Am Vet Med Assoc* 2013 Vol 243 (9) pp. 1316-22.
- 20 Klopffleisch R, Kohn B, Plog S, et al. An emerging pulmonary haemorrhagic syndrome in dogs: similar to the human leptospiral pulmonary haemorrhagic syndrome? *Vet Med Int* 2010 Vol 2010 (0) pp. 928541.
- 21 Kohn B: Leptospirosis – What’s New? Fourth International Society for Companion Animal Infectious Diseases Symposium 2016.
- 22 Kohn B, Steinicke K, Arndt G, et al. Pulmonary abnormalities in dogs with leptospirosis. *J Vet Intern Med* 2010 Vol 24 (6) pp. 1277-82.
- 23 Barthélemy A, Magnin M, Pouzot-Nevoret C, et al. Hemorrhagic, Hemostatic, and Thromboelastometric Disorders in 35 Dogs with a Clinical Diagnosis of Leptospirosis: A Prospective Study. *J Vet Intern Med* 2017 Vol 31 (1) pp. 69-80.
- 24 Goldstein RE, Lin RC, Langston CE, et al. Influence of infecting serogroup on clinical features of leptospirosis in dogs. *J Vet Intern Med* 2006 Vol 20 (3) pp. 489-94.
- 25 Langston C: Leptospirosis. Atlantic Coast Veterinary Conference 2010.
- 26 Mastrorilli, C, Dondi F, Angoli C, et al. Clinicopathologic features and outcome predictors of *Leptospira interrogans* australis serogroup infection in dogs: a retrospective study of 20 cases (2001-2004). *J Vet Intern Med* 2017; 21 (1): 3-10.
- 27 Sonet J, Barthélemy A, Goy-Thollot I, et al. Prospective evaluation of abdominal ultrasonographic findings in 35 dogs with leptospirosis. *Vet Radiol Ultrasound* 2018 Vol 59 (1) pp. 98-106.
- 28 Grayzel SE, DeBess EE: Characterization of leptospirosis among dogs in Oregon, 2007-2011. *J Am Vet Med Assoc* 2016 Vol 248 (8) pp. 908-15.
- 29 Troia R, Balboni A, Zamagni S, et al. Prospective evaluation of rapid point-of-care tests for the diagnosis of acute leptospirosis in dogs. *Vet J* 2018 Vol 237 (0) pp. 37-42.
- 30 Fraune CK, Schweighauser A, Francey T. Evaluation of the diagnostic value of serologic microagglutination testing and a polymerase chain reaction assay for diagnosis of acute leptospirosis in dogs in a referral center. *J Am Vet Med Assoc* 2013; 242: 1373-1380.
- 31 Midence JN, Leutenegger CM, Chandler AM, et al. Effects of recent *Leptospira* vaccination on whole blood real time PCR testing in healthy client owned dogs. *J Vet Intern Med* 2012; 26 (1): 149-152.
- 32 Lizer J, Velineni S, Weber A, et al. Evaluation of 3 Serological Tests for Early Detection Of *Leptospira*-specific Antibodies in Experimentally Infected Dogs. *J Vet Intern Med* 2018 Vol 32 (1) pp. 201-207.
- 33 Martin LER, Wiggans KT, Wennogle SA, et al. Vaccine-associated *Leptospira* antibodies in client owned dogs. *J Vet Intern Med* 2014; 28: 789-792.
- 34 Winzelberg SI, Tasse SM, Goldstein RE, et al. Evaluation of SNAP® Lepto in the diagnosis of Leptospirosis. *Int J Appl Res Vet Med* 2015; 13 (3): 193-98.
- 35 Curtis KM, Foster PC, Smith PS, et al.: Performance of a recombinant LipL32 based rapid in-clinic ELISA (SNAP® Lepto) for the detection of antibodies against leptospira in dogs. *Int J Appl Res Vet Med* 2015; 13 (3): 182-89.
- 36 Gloor CI, Schweighauser A, Francey T, et al. Diagnostic value of two commercial chromatographic “patient-side” tests in the diagnosis of acute canine leptospirosis. *J Small Anim Pract* 2017; 58: 154-161.
- 37 Adain CA, Cowgill LD. Treatment and outcome of dogs with leptospirosis: 36 cases (1990-1998). *J Am Vet Med Assoc* 2000; 216: 371-375.
- 38 Legatti SAM, El Dib R, Legatti E, et al. Acute kidney injury in cats and dogs: A proportional meta-analysis of case series studies. *PLoS One* 2018; 13 (1): e0190772.
- 39 Beckel NF, O’Toole TE, Rozanski EA, et al. Peritoneal Dialysis in the Management of Acute Renal Failure in 5 Dogs with Leptospirosis. *J Vet Emerg Crit Care* 2005 Vol 15 (3) pp. 201-205.
- 40 Sant’Anna R, Vieira AS, Oliveira J, et al. Asymptomatic leptospiral infection is associated with canine chronic kidney disease. *Comparative Immunology, Micro and Infect Disease* 2019; 62: 64-67.
- 41 Klaasen HLBM, Van der Veen M, Sutton D, et al. A new tetravalent canine leptospirosis vaccine provides at least 12 months immunity against infection. *Vet Immunol Immunopathol* 2014 Vol 158 (1-2) pp. 26-9.
- 42 Weese JS, Fulford M: Bacterial Diseases. *Companion Animal Zoonoses Ames*, Blackwell Publishing 2011 pp. 157-164.
- 43 Moore GE, Lappin MR: Leptospirosis: Are Owners at Risk? *Clinician’s Brief* 2017; 15 (9): 91.



Canine and Feline Cutaneous Round Cell Tumors

Pamela Mouser, DVM, MS, DACVP

Anatomic Pathologist | angell.org/lab

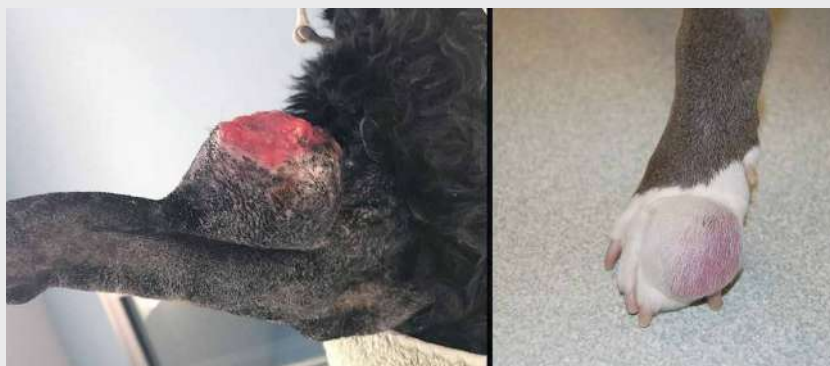Cutaneous and subcutaneous masses are among the most common surgical samples submitted for histopathology. As with any tumor type, the clinical questions to be answered for skin masses include: What is it? How will it behave? Is it completely excised? At the microscope, the pathologist must first determine if the mass is truly neoplastic – which can be surprisingly challenging on occasion! – and then further characterize the process based on histogenesis, or tissue differentiation. Most pathologists stratify neoplasms into three groups using morphology: epithelial, mesenchymal/spindloid, or round cell origin. Poorly pigmented melanocytic tumors may overlap any or all of these morphologies, and therefore may represent their own (fourth) group. This article will focus specifically on round cell tumors of the skin, including percentages of each tumor type relative to the total cutaneous/subcutaneous round cell tumors submitted to Angell in the past 4.5 years.

MAST CELL TUMOR

More than 80% of canine round cell tumors in the skin and subcutis evaluated histologically in this recent Angell population are mast cell tumors. In cats, the proportion of mast cell tumors approaches 80%. Canine mast cell tumors can present with a range of gross manifestations, including a discrete raised dermal nodule, a plaque-like thickening which is minimally raised, or a dermal to subcutaneous mass with or without discrete margins (Figure 1). Alopecia (from displacement of adnexal structures by neoplastic cells) and ulceration are common, as is a history of fluctuant tumor size. Histologically, the majority of canine mast cell tumors do not present a diagnostic challenge as the neoplastic mast cells are often well differentiated or have discernible granules. Eosinophils, which frequently accompany neoplastic canine mast cells, are a helpful reminder to assess for the presence of granules in poorly differentiated tumors. Cutaneous mast cell tumors in dogs are graded using one or both published grading schemes (three-tier system established by Patnaik et al. in 1984 or two-tier system by Kiupel et al. in 2011), in an attempt to predict biological behavior for a given mass.^{5,6}

FIGURE 1

Two cutaneous mast cell tumors. In both examples, the tumors appear nodular and protrusive. The mass on the left has ulceration of the overlying skin surface, while the mass on the right appears alopecic due to separation and possibly disruption of hair follicles by infiltrating mast cells.



Feline cutaneous mast cell tumors often occur as single, discrete, raised skin nodules. In contrast to dogs, feline mast cell granules are not as visually pronounced with routine stains. In addition, feline mast cell tumors may have few or no accompanying eosinophils. A recent study suggests application of a two-tier grading system for feline mast cell tumors.⁸ A low-grade designation using this system essentially corresponds to benign biological behavior, as is commonly predicted for well-differentiated feline cutaneous mast cell tumors. Feline mast cell tumors classified as high-grade in this study had a median survival time of 349 days.

PLASMA CELL TUMOR

Cutaneous plasma cell tumor (plasmacytoma) is the next most frequent diagnosis in dogs during this timeline (about 8% of canine cutaneous round cell tumors). Grossly, most cutaneous plasma cell tumors resemble cutaneous histiocytomas (discussed below), and are characterized by a discrete raised alopecic dermal nodule (Figure 2). Also similar to histiocytomas, plasma cell tumors favor the skin of the head and distal extremities. Microscopically, these tumors commonly have binucleate, multinucleate, and karyomegalic

cells distributed among the background mononuclear population. Plasmacytoid features (eccentric clock-faced nuclei with paranuclear pallor) may be seen in some neoplastic cells, particularly near the margins of the mass. In tumors where plasmacytoid differentiation is not appreciated and nuclear pleomorphism is pronounced, morphology may suggest a more aggressive lesion such as histiocytic sarcoma. Cutaneous plasma cell tumors typically have benign biological behavior in dogs and are rarely associated with multiple myeloma. Dogs presenting with multiple cutaneous plasma cell tumors, termed cutaneous plasmacytosis, may experience shorter survival times according to one retrospective study.¹ Cutaneous plasma cell tumors are rare in cats.

CANINE CUTANEOUS HISTIOCYTOMA

Cutaneous histiocytomas represent about 4% of cutaneous round cell tumors from dogs in recent Angell submissions. This percentage likely underestimates the relative proportion of this tumor type, as histiocytomas may be more commonly addressed by primary care

(CONTINUED ON PAGE 16)

PATHOLOGY

CONTINUED FROM PAGE 15

FIGURE 2

↘ Compares cutaneous plasma cell tumor (plasmacytoma, left) and cutaneous histiocytoma (right). Both lesions are discrete, raised, alopecic masses. Erythema around the plasma cell tumor on the left may be related to self-trauma or clinical manipulation of the lesion. The amputated distal tail on the right has been formalin-fixed with serial slices through the mass for fixation.

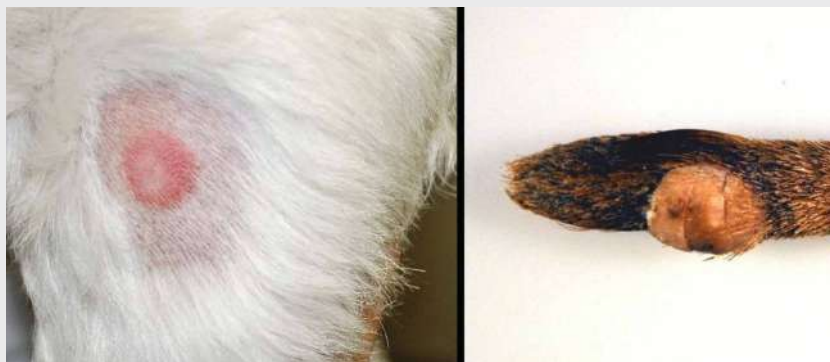
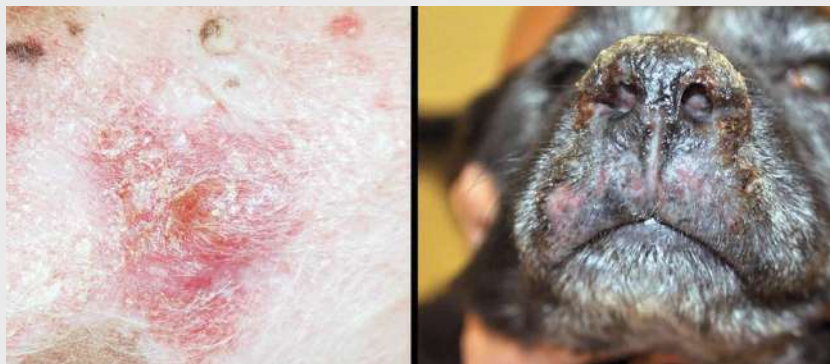

FIGURE 3

↘ Shows two manifestations of cutaneous lymphoma in dogs. The left panel is a close-up view of affected abdominal skin showing erythema, scaling, and raised plaques to nodules. The black V-shaped marks were made by the clinician to guide the biopsy procedure. The dog on the right has thickening, crusting, and cracking of the nasal planum. Skin of the upper lip is also thickened with multifocal to coalescing ulceration. Note how gross lesions of cutaneous lymphoma may overlap with those of non-neoplastic dermatopathies.



veterinarians and therefore not removed as often by Angell's surgery service. This tumor is generally considered a lesion of young dogs, although affected animals in the Angell group range from 1-12 years old with a median of 6 and mean of 6.2 years old. Cutaneous histiocytomas, sometimes referred to as "button" tumors due to their discrete raised nodular gross appearance, have benign biological behavior (Figure 2). Spontaneous regression may occur, although the associated ulceration and inflammation may require surgical intervention. Regressing histiocytomas are sometimes indistinguishable from mononuclear inflammation, and may be diagnosed as such by the pathologist.

LYMPHOMA

About 4% of canine cutaneous round cell tumors in this population are classified as lymphoma, with the majority of these tumors demonstrating epitheliotropism (epithelial affinity by neoplastic lymphoid cells). Cutaneous epitheliotropic lymphoma is typically of T-cell origin, and is also called mycosis fungoides. Grossly, lesions may be solitary, multifocal, or widespread and have a variable clinical appearance which may include scaling, erythema, thickened skin, erosion/ulceration, or nodules (Figure 3). Mucocutaneous junctions and mucous membranes may be affected. Histologically, neoplastic lymphoid cells in

epitheliotropic lymphoma are small to medium size and form nests which may coalesce into broad plaques within the epidermis and adnexal structures. In a recent retrospective study of dogs with epitheliotropic lymphoma, the median survival time for dogs with cutaneous lesions was 130 days.³ Dogs presenting with a solitary skin lesion had a better prognosis (median survival time of 231 days), as did dogs with mucocutaneous/mucosal lesions (median survival time of 491 days). Chemotherapy also significantly increased the median survival time in the retrospective study.

Lymphoma composed about 9% of feline cutaneous round cell tumors in the Angell population. In contrast to dogs, cutaneous lymphoma in cats is more often nonepitheliotropic. Cutaneous/subcutaneous lymphoma has been reported at injection sites in cats,⁷ and a seemingly unique variant of cutaneous lymphoma develops over the tarsus.² Cats with tarsal lymphoma in the published retrospective study frequently had or developed metastatic disease. The median survival time for cats with tarsal lymphoma was 190 days. Interestingly, more than half of the Angell feline cutaneous lymphoma submissions were compatible with tarsal lymphoma (Figure 4).

HISTIOCYTIC SARCOMA

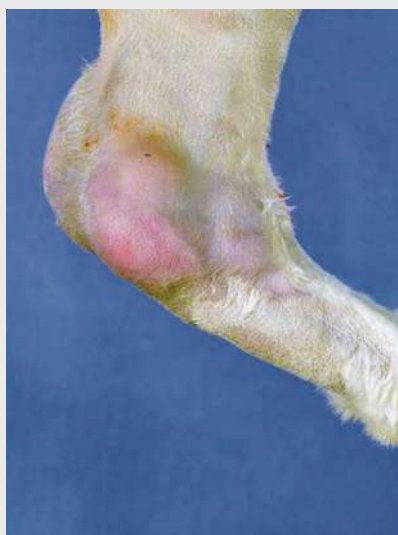Between 2-3% of canine cutaneous/subcutaneous round cell tumors from the past 4.5 years were diagnosed as histiocytic sarcoma. This malignant tumor of histiocytes typically presents a single expansile subcutaneous mass, often on the extremities, with a clinical appearance similar to a subcutaneous mast cell tumor or soft tissue sarcoma. In fact, neoplastic cells may range from round to ovoid to spindle histologically, and may ultimately require immunohistochemistry to confirm their leukocytic origin. Histiocytic sarcoma should also be distinguished from cutaneous/reactive histiocytosis and granulomatous inflammation. In one retrospective study evaluating prognosis of histiocytic sarcoma, the authors noted that many tumors originally suspected to be of histiocytic origin were excluded following immunohistochemistry.⁴ In the same study, localized histiocytic sarcoma (which is the common presentation for cutaneous/subcutaneous histiocytic sarcoma) had a median survival time around 1 year. Histiocytic sarcoma is less common in cats, with few suspect cases (unconfirmed) in the Angell population.

FINAL TAKE-HOME POINTS

Cutaneous round cell tumors range from potentially self-resolving benign lesions (canine cutaneous histiocytoma) to aggressive

FIGURE 4

⌵ This left hind limb from a cat has a multinodular subcutaneous mass surrounding the tarsal joint. Histologically, the mass comprises neoplastic large lymphoid cells, which also distend sinuses in the left popliteal lymph node.



malignancies (cutaneous lymphoma). While distinction between these entities is often relatively clear-cut, cell of origin may not be immediately obvious on histopathology. Fine needle aspirates or impression smears of the biopsy may prove valuable to the pathologist, as cytologic preparations may retain cellular detail in better quality. Do not hesitate to pursue recommended ancillary diagnostic tests (special stains, immunohistochemistry, or PCR for antigen receptor rearrangement [PARR]) to more completely classify a cutaneous round cell tumor, as the behavior and prognosis differs widely within this group.

REFERENCES

- 1 Boostrom BO, Moore AS, DeRegis CJ, et al. Canine cutaneous plasmacytosis: 21 cases (2005-2015). *J Vet Intern Med* 2017;31:1074-1080.
- 2 Burr HD, Keating JH, Clifford CA, Burgess KE. Cutaneous lymphoma of the tarsus in cats: 23 cases (2000-2012). *J Am Vet Med Assoc* 2014;244:1429-1434.
- 3 Chan CM, Frimberger AE, Moore AS. Clinical outcome and prognosis of dogs with histopathological features consistent with epitheliotropic lymphoma: a retrospective study of 148 cases (2003-2015). *Vet Dermatol* 2018;29:154-e59.
- 4 Dervisis NG, Kiupel M, Qin Q, Cesario L. Clinical prognostic factors in canine histiocytic sarcoma. *Vet Comp Oncol* 2017;15:1171-1180.
- 5 Kiupel M, Webster JD, Bailey KL, et al. Proposal of a 2-tier histologic grading system for canine cutaneous mast cell tumors to more accurately predict biological behavior. *Vet Pathol* 2011;48:147-155.
- 6 Patnaik AK, Ehler WJ, MacEwen EG. Canine cutaneous mast cell tumor: morphologic grading and survival time in 83 dogs. *Vet Pathol* 1984;21:469-474.
- 7 Robbabanca P, Avallone G, Rodriguez A, et al. Cutaneous lymphoma at injection sites: pathological, immunophenotypical, and molecular characterization in 17 cats. *Vet Pathol* 2016;53:823-832.
- 8 Sabattini S, Bettini G. Grading cutaneous mast cell tumors. *Vet Pathol* 2019;56:43-49.

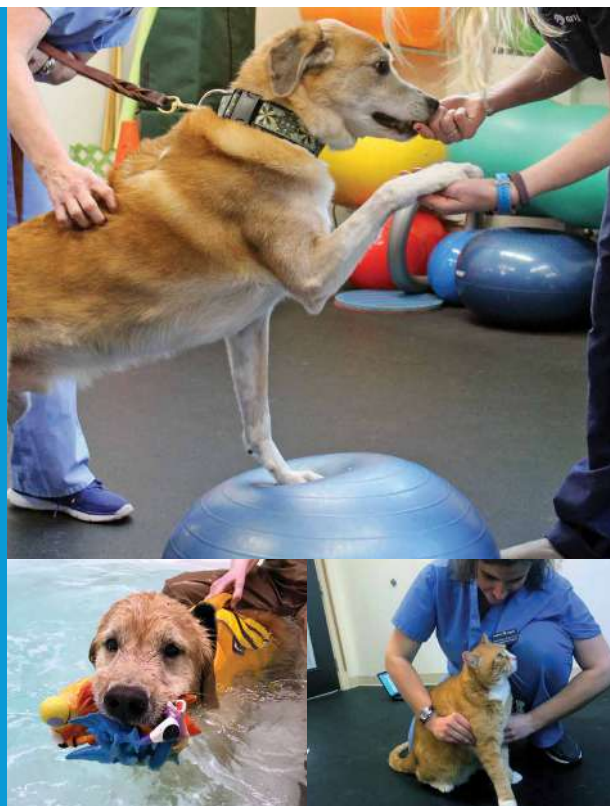⌵ Physical Rehabilitation at MSPCA-Angell West

Canine physical rehabilitation is used to treat a wide variety of orthopedic and neurological conditions. Whether recovering from an injury, or cross training, or facing mobility issues, dogs can substantially benefit from physical rehabilitation.

MSPCA-Angell West Physical Rehabilitation offers services seven days per week. Jennifer Palmer, DVM, Certified Canine Rehabilitation Therapist (CCRT), and Amy Straut, DVM, CCRT, lead our Physical Rehabilitation team. Visit angell.org/rehab for details and video footage of the impact of their work on our canine patients.

Current physical rehabilitation services include:

- Hydrotherapy
- Manual therapy
- Massage
- Chiropractic
- Land-based exercise
- Therapeutic laser treatment
- Consultation and fitting of assistive devices



STAFF DOCTORS AND RESIDENTS

■ We encourage you to contact Angell's specialists with questions.

Main Phone: 617 522-7282 (Boston) | 781 902-8400 (Waltham) | Veterinary Referrals: 617 522-5011 | Angell at Nashoba: 978 577-5992

CHIEF OF STAFF

Ann Marie Greenleaf, DVM, DACVECC
agreenleaf@angell.org

24-HOUR EMERGENCY & CRITICAL
CARE MEDICINE, BOSTON

Alison Allukian, DVM
aallukian@angell.org

Justina Bartling, DVM
jbartling@angell.org

Jami Becker, DVM
jbecker@angell.org

Kiko Bracker, DVM, DACVECC
Service Co-Director
kbracker@angell.org

Maria Brandifino, DVM
mbrandifino@angell.org

Kate Dorsey, DVM
kdorsey@angell.org

Morgan Kelley, DVM
mkelley@angell.org

Audrey Koid, DVM
akoid@angell.org

Caitlin Koontz, DVM
ckoontz@angell.org

Susan Magestro, DVM
smagestro@angell.org

Virginia Sinnott-Stutzman, DVM, DACVECC
vsinnottstutzman@angell.org

Kelsey Turley, DVM
kturley@angell.org

Megan Whelan, DVM, DACVECC, CVA
Chief Medical Officer
mwhelan@angell.org

24-HOUR EMERGENCY & CRITICAL
CARE MEDICINE, WALTHAM

Jordana Fetto, DVM
jfetto@angell.org

Amanda Lohin, DVM
alohin@angell.org

David McChesney, DVM
dmcchesney@angell.org

Courtney Peck, DVM, DACVECC
cpeck@angell.org

Lauren Rose, DVM
lrose@angell.org

Jessica Seid, DVM
jseid@angell.org

Catherine Sumner, DVM, DACVECC
Chief Medical Officer, Waltham
csumner@angell.org

ANESTHESIOLOGY

Kate Cummings, DVM, DACVAA
kcummings@angell.org

Stephanie Krein, DVM, DACVAA
skrein@angell.org

AVIAN & EXOTIC MEDICINE (W/B)

Brendan Noonan, DVM, DABVP (Avian Practice)
(Boston & Waltham)
bnoonan@angell.org

Elisabeth Simone-Freilicher, DVM, DABVP (Avian Practice)
esimonefreilicher@angell.org

Patrick Sullivan, DVM, DABVP (Avian Practice)
(Waltham)
psullivan@angell.org

BEHAVIOR (W/B)

Terri Bright, PhD, BCBA-D, CAAB
tbright@angell.org

CARDIOLOGY (W/B)

Katie Hogan, DVM, DACVIM (Cardiology)
(Boston)
khogan@angell.org

Julia Lindholm, DVM
(Boston & Waltham)
jlindholm@angell.org

Rebecca Malakoff, DVM, DACVIM (Cardiology)
(Waltham)
rmalakoff@angell.org

Natalie Morgan, DVM
(Boston & Waltham)
nmorgan@angell.org

Rebecca Quinn, DVM, DACVIM (Cardiology & Internal Medicine)
rquinn@angell.org

Elizabeth Wiley, DVM
ewiley@angell.org

Joseph Zarin, DVM
jzarin@angell.org

DENTISTRY

Alice Ekerdt, DVM
akerdt@angell.org

Colleen McCarthy, DVM
cmccarthy@angell.org

Jessica Riehl, DVM, DAVDC
jriehl@angell.org

DERMATOLOGY (W/B)

Klaus Loft, DVM
kloft@angell.org

Brooke Simon, DVM
(Residency Trained)
(Boston & Waltham)
bsimon@angell.org

DIAGNOSTIC IMAGING (W/B)

Naomi Ford, DVM, DACVR
nford@angell.org

Steven Tsai, DVM, DACVR
stsai@angell.org

Ruth Van Hatten, DVM, DACVR
rvanhatten@angell.org

INTERNAL MEDICINE (W/B)

Michelle Beehler, DVM
mbeehler@angell.org

Douglas Brum, DVM
dbrum@angell.org

Alyssa Bryce, DVM
abryce@angell.org

Maureen Carroll, DVM, DACVIM
mccarroll@angell.org

Zach Crouse, DVM, DACVIM
zcrouse@angell.org

Erika de Papp, DVM, DACVIM
edepapp@angell.org

Jean Duddy, DVM
jduddy@angell.org

Lisa Gorman, DVM, DACVIM
(Waltham)
lgorman@angell.org

Kirstin Johnson, DVM, DACVIM
kcjohnson@angell.org

Shawn Kearns, DVM, DACVIM
skearns@angell.org

Evan Mariotti, DVM, DACVIM
emariotti@angell.org

Susan O'Bell, DVM, DACVIM
Service Director
sobell@angell.org

Daisy Spear, DVM
dspear@angell.org

Daniela Vrabelova Ackley, DVM, DACVIM
(Waltham)
dvrabelova@angell.org

STAFF DOCTORS AND RESIDENTS

CONTINUED FROM PAGE 18

NEUROLOGY (W/B)

Rob Daniel, DVM, DACVIM (Neurology)
(Boston & Waltham)
rdaniel@angell.org

Michele James, DVM, DACVIM (Neurology)
(Boston & Waltham)
mjames@angell.org

Jennifer Michaels, DVM, DACVIM (Neurology)
(Boston & Waltham)
jmichaels@angell.org

ONCOLOGY

Lyndsay Kubicek, DVM, DACVR (Radiation Oncology)
lkubicek@angell.org

Ji-In (Jean) Lee, DVM
(Board Eligible for Medical Oncology)
jlee@angell.org

J. Lee Talbott, DVM, DACVIM (Medical Oncology)
jtalbott@angell.org

Jillian Waltz, DVM, DACVIM (Medical Oncology)
(Board Eligible for Radiation Oncology)
jwaltz@angell.org

OPHTHALMOLOGY

Daniel Biros, DVM, DACVO
dbiros@angell.org

Martin Coster, DVM, MS, DACVO
mcoaster@angell.org

PAIN MEDICINE

Lisa Moses, VMD, DACVIM, CVMA
lmoses@angell.org

PATHOLOGY

(CLINICAL & ANATOMIC)*

Patty Ewing, DVM, MS, DACVP
pewing@angell.org

Pamela Mouser, DVM, MS, DACVP
pmouser@angell.org

PHYSICAL REHABILITATION

Jennifer Palmer, DVM, CCRT
jpalmer@angell.org

Amy Straut, DVM, CCRT
astraut@angell.org

SURGERY (W/B)

Sue Casale, DVM, DACVS
scasale@angell.org

Megan Cray, VMD
mcray@angell.org

Andrew Goodman, DVM, DACVS
agoodman@angell.org

Michael Pavletic, DVM, DACVS
mpavletic@angell.org

Nicholas Trout, MA, VET MB, MRCVS, DACVS, DECVS
ntrout@angell.org

Emily Ulfelder, BVetMed
(Boston and Waltham)
eulfelder@angell.org

Mallory Watson, DVM
mwatson@angell.org

Spencer Yeh, DVM
syeh@angell.org

ANGELL AT NASHOBA

Laurence Sawyer, DVM
lsawyer@angell.org

(W/B) Services also available at our Waltham location

Our Service Locations

BOSTON & WALTHAM

Avian & Exotic Medicine
617 989-1561

Behavior
617 989-1520

Cardiology
617 541-5038

Dermatology
617 524-5733

Diagnostic Imaging
617 541-5139

Internal Medicine
617 541-5186

Neurology
617 541-5140

Physical Rehabilitation**
781 902-8400

Surgery
617 541-5048

BOSTON ONLY

Anesthesiology
617 541-5048

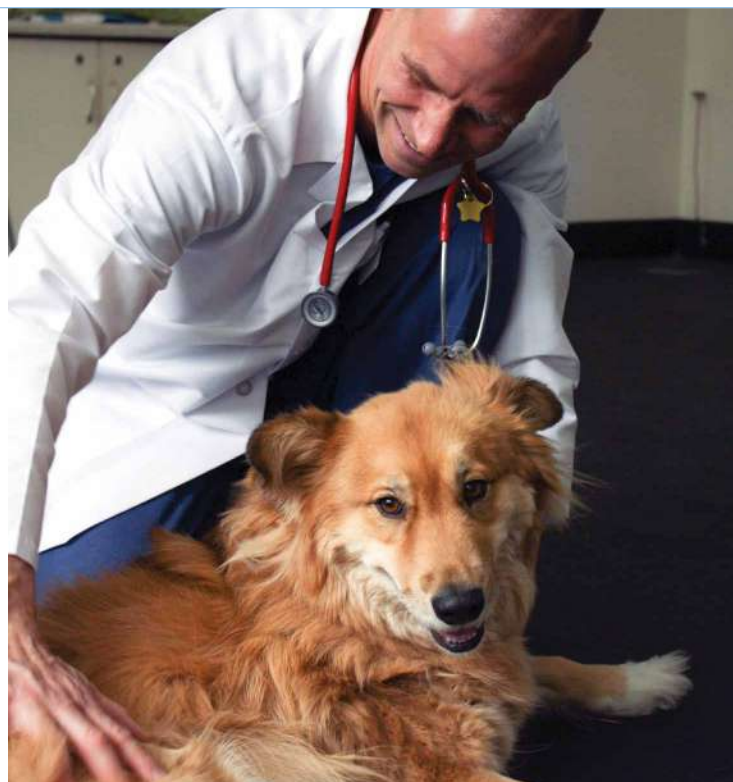Dentistry
617 522-7282

Oncology
617 541-5136

Ophthalmology
617 541-5095

Pain & Palliative Care
617 541-5140

Pathology*
614 541-5014



24/7 Emergency & Critical Care ■ Boston: 617 522-5011 ■ Waltham: 781 902-8400

*Boston-based pathologists serve both Boston and Waltham locations **Available only in Waltham

We mail one complimentary copy of our newsletter to each of our referring partners. Please circulate this copy within your practice.

Winter 2020 | Volume 14:1 | angell.org | facebook.com/AngellReferringVeterinarians

MSPCA-ANGELL
350 South Huntington Avenue
Boston, MA 02130
617 522-5011
angell.org

MSPCA-ANGELL WEST
293 Second Avenue
Waltham, MA 02451
781 902-8400
angell.org/waltham

ANGELL AT NASHOBA
100 Littleton Road
Westford, MA 01886
978 577-5992
angell.org/nashoba

ANGELL AT ESSEX
565 Maple Street
Danvers, MA 01923
978 304-4648
angell.org/essex

ANGELL.ORG/DIRECTIONS (FREE PARKING) | ANGELL.ORG/HOURS | ANGELL.ORG/CE

Please consider adding Angell's main numbers to your after-hours phone message.



↳ Angell's Referring Vet Portal

angell.org/vetportal

24/7 access to your referred patients' records

We are pleased to offer the Angell Referring Veterinarian Portal to our referring partners. The portal provides 24/7, secure, mobile-friendly access to your referred patients' records through angell.org/vetportal. The system automatically updates throughout the day and provides 24/7 access to:

- Online Medical Records
- SOAPs
- Lab Results
- Discharge Instructions
- Check-in Status
- Diagnostic Images
- Referral Reports
- Prescriptions

Settings can be customized within the portal to receive notices by email or fax, and you may list multiple emails to receive check-in, discharge, deceased, and update notices.

Visit angell.org/vetportal or call our referral coordinator at 617 522-5011 to gain access to your account.