



<b>ONCOLOGY</b>
PAGE 1 Surgical Options for Oral Tumors
<b>SURGERY</b>
PAGE 1 Joint Resurfacing for Canine OC Lesions
<b>NEUROLOGY &amp; ONCOLOGY</b>
PAGE 6 It's Not (Always) a Tumor: When to Suspect a Brain Tumor in Dogs and What We Can Do About It
<b>OPHTHALMOLOGY</b>
PAGE 10 Trichiasis, Ectopic Cilia, and Distichia: T.E.D. Talk on Eyelash Problems in Dogs and Cats
<b>EMERGENCY &amp; CRITICAL CARE</b>
PAGE 14 The Vomiting Dog and Cat: An ER Perspective
<b>INTERNAL MEDICINE</b>
PAGE 16 Hypoadrenocorticism in Dogs
<b>EMERGENCY &amp; CRITICAL CARE</b>
PAGE 19 Top Five Tips for Emergency Triage



ONCOLOGY

## Surgical Options for Oral Tumors

Megan Cray, VMD, DACVS-SA  
[angell.org/oncology](http://angell.org/oncology) | [oncology@angell.org](mailto:oncology@angell.org) | 617-541-5136

**O**ral cancer accounts for six to seven percent of canine and three percent of feline cancers. This percentage may increase as veterinary medicine advances and more prophylactic dental procedures are performed. Early detection, diagnosis, and treatment can vastly improve the prognosis for canine and feline oral tumors.

### Diagnosis and Staging

Many animals present with an oral mass noticed by their owner. Other possible clinical signs of an oral tumor include

increased salivation, epistaxis, weight loss, halitosis, oral discharge, and dysphagia. The tumor diagnosis workup is imperative in determining treatment options and prognosis. The first step is documenting the location and tumor size. Often, an incisional biopsy is needed to obtain a diagnosis. Due to frequent inflammation and necrosis, fine needle aspiration and cytology are often not rewarding. While regional radiographs can detect bone invasion due to impaction, surgeons often elect CT imaging for surgical planning.

(CONTINUED ON PAGE 2)



SURGERY

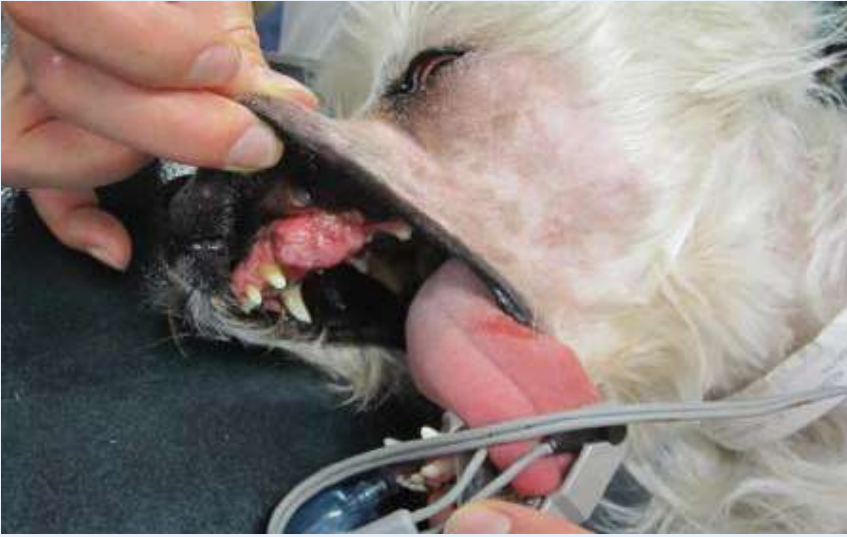## Joint Resurfacing for Canine OC Lesions

Nicholas J. Trout, MA, VET, MB, DACVS, ECVS  
[angell.org/surgery](http://angell.org/surgery) | [surgery@angell.org](mailto:surgery@angell.org) | 617-541-5048

**O**steochondrosis (OC) is caused by a failure of normal endochondral ossification leading to abnormal cartilage development. In some cases, this diseased cartilage will separate from the underlying bone to create a flap (Osteochondritis dissecans or OCD). Regardless, these types of articular defects, found in the canine shoulder, elbow, hip, stifle, and hock, frequently

occur in growing large breed dogs, leading to lameness, joint pain, joint swelling, and decreased range of motion in the affected joint. Most dogs present between 6 and 12 months of age, but OC lesions can become a clinical problem later in life. Diagnosis is often straightforward through radiography or computed tomography; however, treatment can be challenging. Historically, the cartilage defect would be curetted down to

(CONTINUED ON PAGE 4)



The regional lymph nodes of the oral cavity include the mandibular, parotid, and medial retropharyngeal lymph nodes. Any mandibular lymph node enlargement should be documented, and fine needle aspiration should be performed. However, in one study of 100 dogs with oral melanoma, 40% of dogs with normal-sized lymph nodes had metastasis, and 49% of dogs with enlarged lymph nodes did not. Therefore, normal size does not always preclude the presence of metastasis. Chest radiographs or thoracic CT should always be performed in patients with malignant oral tumors to assess for possible metastasis.

### Surgical Options

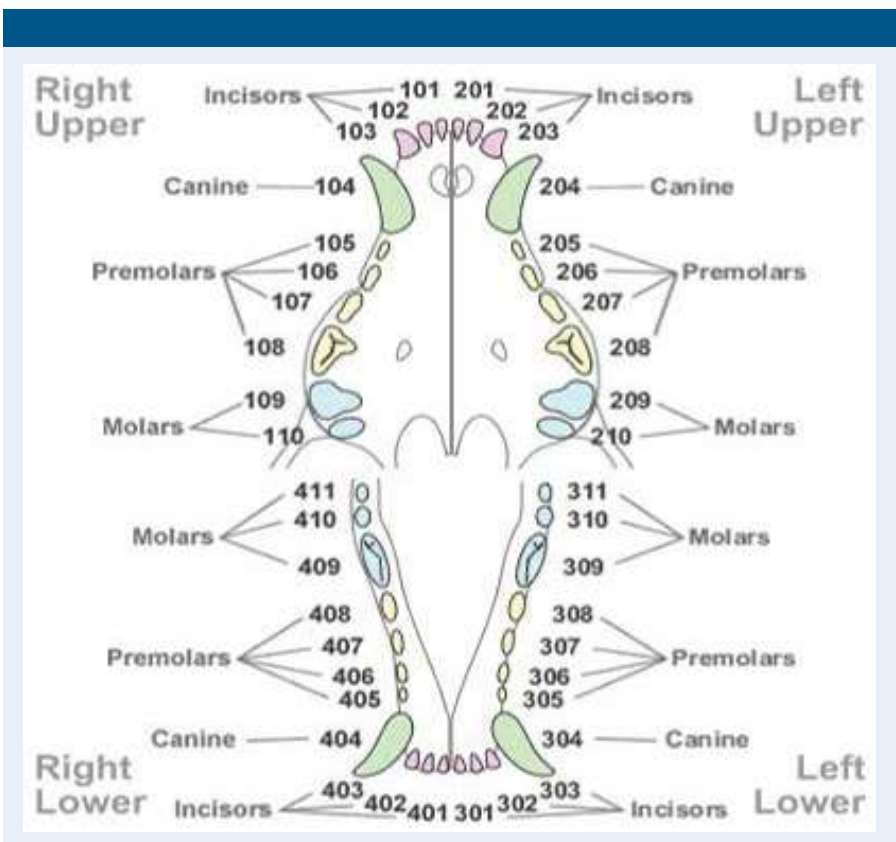
Surgery is the most frequently used modality in the treatment of oral tumors. Mandibulectomies and maxillectomies are generally well tolerated and can provide an excellent outcome. Typically, 2 to 3cm margins are ideal for malignant tumors, while 0.5cm margins are acceptable for benign tumors. While both procedures carry a moderate risk for complications, the majority of these complications are considered minor. Surgical complications that have been associated with these procedures include hemorrhage, aspiration pneumonia, incisional dehiscence, mandibular drift and malocclusion, ranula formation, anorexia, nasal discharge or epistaxis, difficulty prehending, implant migration, oronasal fistula formation, and very rarely death. Most of these procedures do not significantly alter the dog's or cat's outward appearance. Owners frequently report high satisfaction following their pet's surgical procedure.

### Types of Oral Tumors

The most common oral tumors in dogs are malignant melanoma, squamous cell carcinoma, and fibrosarcoma. Malignant melanoma tends to occur in smaller body weight dogs than other oral

tumor types. These tumor types carry a high metastatic rate to the lymph nodes and lungs, holding only a fair to good prognosis following surgery. Non-tonsillar squamous cell carcinoma has a lower metastatic rate (~20%) but depends upon the site. Squamous cell carcinoma contained to the rostral oral cavity generally has a low metastatic rate, and the caudal tongue and tonsil have a high metastatic potential. Following surgery, the prognosis can be good to excellent. Fibrosarcomas most commonly occurs in large-breed dogs. These can be difficult to differentiate from fibromas and, therefore, can be classified as histologically low-grade but biologically high fibrosarcomas. The surgical treatment should be aggressive regardless. If surgically resectable, the prognosis can be good as these are most often locally aggressive, with a metastatic rate to the lymph nodes and chest in <30% of cases.

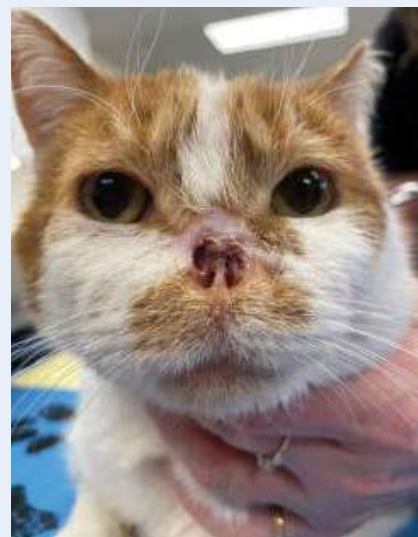In felines, the most common oral tumor is squamous cell carcinoma. While metastasis is reportedly rare, the true incidence is unknown because so few cats have their local disease controlled. Unfortunately, these commonly present without a surgical option and do not respond well to radiation. The prognosis for this tumor type is often poor to fair.





Epulides are benign gingival proliferation arising from the periodontal ligament and can commonly look similar to gingival hyperplasia. These are now subclassified as acanthomatous ameloblastomas and peripheral odontogenic fibromas. While both do not metastasize, these behave slightly differently and are treated differently with surgery. Acanthomatous ameloblastomas are locally aggressive, so a bony margin is needed to remove these tumors. Alternatively, peripheral odontogenic tumors can be cauterized at their base and frequently do not recur.

Tongue masses are rare, with the majority being malignant. The most common type of tongue neoplasia is squamous cell carcinoma. It is important to obtain a biopsy under general anesthesia or heavy sedation. A partial glossectomy can be considered for tumors that are



unilateral or rostral. However, many tumors (54%) are midline or bilaterally symmetrical. Radiation is an alternative treatment option for these cases.

### Conclusion

Oral tumors are becoming more common in veterinary medicine. The quicker we can work up these cases and obtain a diagnosis, the faster we can start treatment—the earlier the treatment, the better the ultimate prognosis.

### REFERENCES

- Berg J: Mandibulectomy and Maxillectomy, in Johnson SA, Tobias KM (eds): *Veterinary Surgery Small Animal* (ed 2). St Louis, MO, Elsevier; 2018, pp 1663-1677
- Schwartz P. Partial maxillary resection as a treatment for oral-cancer in 61 dogs. *J Am Anim Hosp Assoc*. 1991;27(6):617-624
- Schwarz P. Mandibular resection as a treatment for oral-cancer in 81 dogs. *J Am Anim Hosp Assoc* 1991;27(6):601-610
- Zacher Am and Manfra Marretta S: Oral and maxillofacial surgery in dogs and cats. *Vet Clin Small Anim* 2013;43:609-649
- MacLellan RH, Rawlinson JE, Rao S, et al: Intraoperative and postoperative complications of partial maxillectomy for the treatment of oral tumors in dogs. *J Am Vet Med Assoc* 2018;252(12):1538-1547
- Bradley RL, MacEwen EG, Loar AS: Mandibular resection for removal of oral tumors in 30 dogs and 6 cats. *J Am Vet Med Assoc* 1984;184(4):460-463
- Sarowitz BN, Davis GJ, Kim S: Outcome and prognostic factors following curative-intent surgery for oral tumours in dogs: 234 cases (2004 to 2014). *J Small Anim Pract* 2017;58(3):146-153
- Wallace J, Matthiesen DT, Patnaik AK: Hemimaxillectomy for the treatment of oral tumors in 69 dogs. *Vet Surg* 1992;21(5):337-341
- Salisbury S: Long-term results of partial mandibulectomy for treatment of oral tumors in 30 dogs. *J Am Anim Hosp Assoc* 1988;24(3):285-294
- Kosovsky JK, Matthiesen DT, Marretta SM, et al: Results of partial mandibulectomy for the treatment of oral tumors in 142 dogs. *Vet Surg* 1991;20(6):397-401
- Hutson CA, Willauer CC, Walder EJ, et al: Treatment of mandibular squamous cell carcinoma in cats by use of mandibulectomy and radiotherapy: seven cases (1987-1989). *J Am Vet Med Assoc* 1992;201(5):777-781
- Withrow S: Mandibulectomy in the treatment of oral-cancer. *J Am Anim Hosp Assoc* 1983;19(3):273-286
- Lascelles BD, Thomson MJ, Dernel WS, et al: Combined dorsolateral and intraoral approach for the resection of tumors of the maxilla in the dog. *J Am Anim Hosp Assoc* 2003;39(3):294-305
- Farese JP, Withrow SJ: Surgical Oncology, in Withrow SJ, Vail DM, Page RL (eds): *Small Animal Clinical Oncology* (ed 5). St Louis, MO, Elsevier, 2013, pp 149-156
- Cray M, Selmic LE, Kindra C, et al: Analysis of risk factors associated with complications following mandibulectomy and maxillectomy in dogs. *JAVMA* 2021; 259(3): <https://doi.org/10.2460/javma.259.3.265>
- Liptak JM and Withrow SJ: Cancer of the Gastrointestinal Tract, in Withrow SJ, Vail DM, Page RL (eds.): *Small Animal Clinical Oncology* (ed 5). St Louis, MO, Elsevier; 2013, pp 381-395
- Beck ER, Withrow SJ, McChesney AE, et al. Canine tongue tumors: a retrospective review of 57 cases. *J Am Anim Hosp Assoc* 22:525, 1986.
- Sharma S, Boston SE, Skinner OT, et al. Survival time of juvenile dogs with oral squamous cell carcinoma treated with surgery alone: A Veterinary Society of Surgical Oncology retrospective study. *Vet Surg* 2021;50(4): 740-747
- Liptak JM, Thatcher GP, Mestrinho LA, et al. Outcomes of cats treated with maxillectomy: 60 cases. A Veterinary Society of Surgical Oncology retrospective study. *VCO* 2020; <https://doi.org/10.1111/vco.12634>
- William LE, Packer RA: Association between lymph node size and metastasis in dogs with oral malignant melanoma: 100 cases (1987-2001). *J Am Vet Med Assoc* 222:1234, 2003

## SURGERY

## Joint Resurfacing for Canine OC Lesions

CONTINUED FROM PAGE 1

curetted down to healthy bleeding subchondral bone, allowing the formation of fibrocartilage. Unfortunately, in the stifle, where the problem lies on the weight-bearing surface of the femoral condyle, positive outcomes are difficult to achieve. The use of a synthetic cartilage plug—SynACART® (Arthrex)—offers an appealing alternative. The plug is made from a biodurable polycarbonate urethane on the articular surface and molded onto a titanium mesh at the base (Figure 1, right), allowing for bone ingrowth and fusion. Plugs come in various sizes: 8mm, 10mm, and 15mm (size of defect can be measured from radiographs or CT scan), which avoids the need for sampling at a donor site, thereby reducing morbidity and speeding up the surgical process.

Routine stifle arthrotomy, judicious retraction, and hyperflexion of the stifle allow exposure of the lesion (Figure 2, below).

FIGURE 1

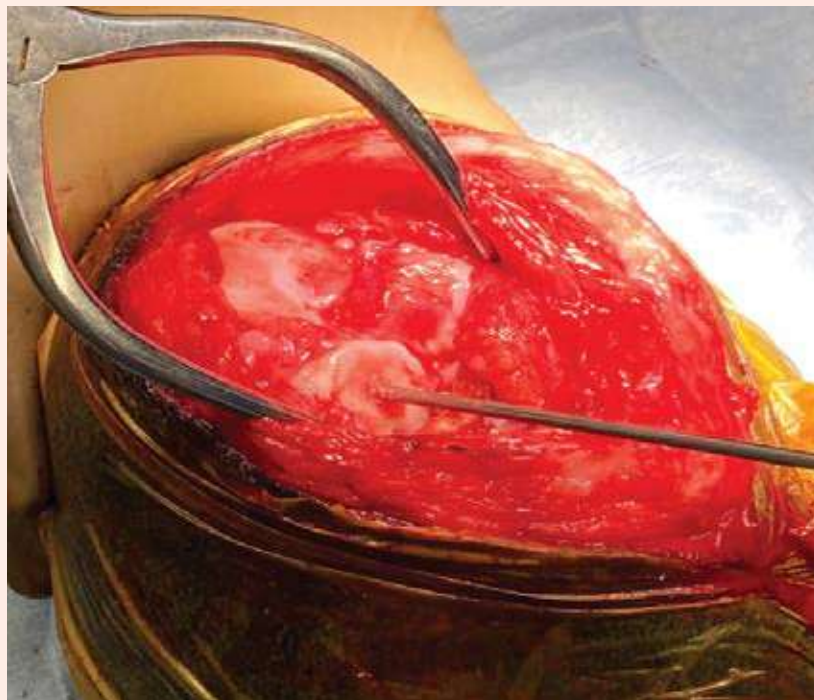
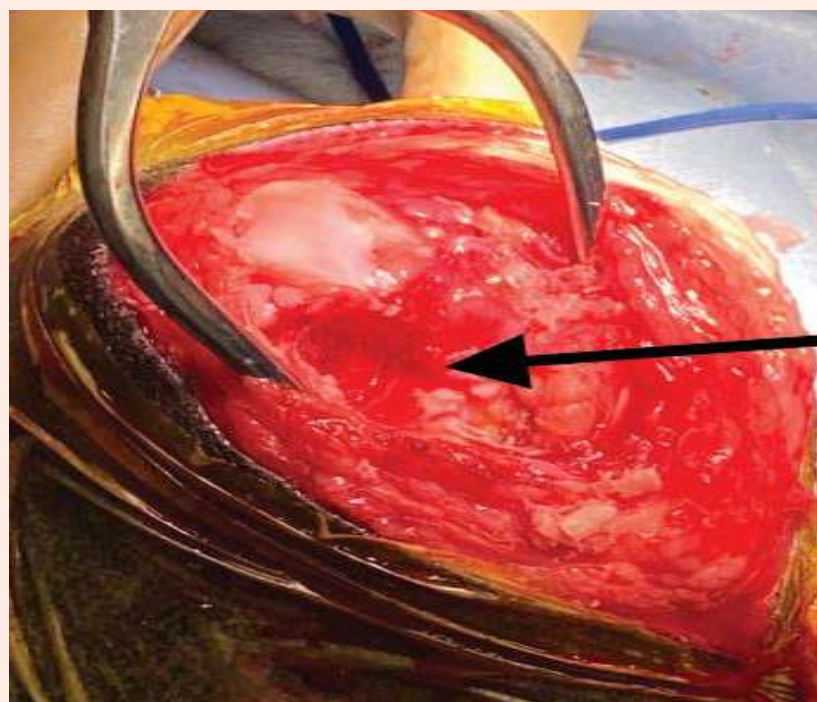


FIGURE 2




Using a specific guide, a 2.4mm guide pin is placed in the center of, and perpendicular to, the defect (retaining a rim of normal hyaline cartilage). A cannulated drill is placed over the pin and advanced to a stop limited depth of 8mm (Page 5, top).

This is carefully flushed and debrided before implantation of the SynACART® plug (Page 5, bottom).

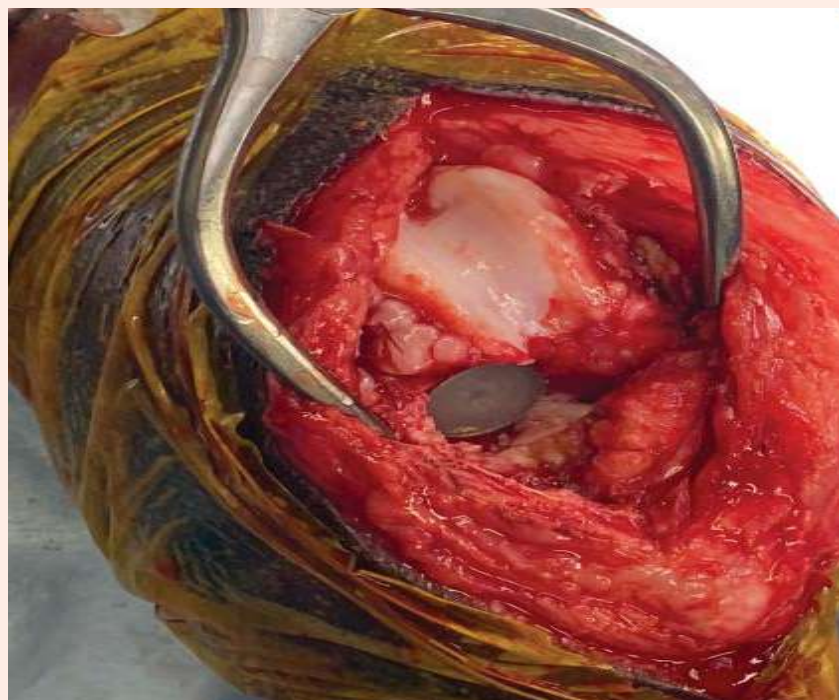Postoperative analgesia is the same as for any other stifle arthrotomy with the use of nonsteroidal anti-inflammatories for two weeks. Confinement to a single room is recommended for the first two to four weeks, with five-minute leash walks starting at four weeks. A six-week recheck with radiographs or CT scan is recommended, followed by an incremental return to normal activity at around 12 weeks post-surgery.

Based on several peer-reviewed scientific articles, it appears as though synthetic osteochondral resurfacing techniques offer a viable alternative to curettage with good to excellent clinical outcomes.

**FIGURE 3**



**FIGURE 4**



REFERENCES

- 1 Canine Elbow Dysplasia: Ununited Anconeal Process, Osteochondritis Dissecans, and Medial Coronoid Process Disease. Vezzoni A, Benjamino K. *Vet Clin North Am Small Anim Pract.* 2021 Mar;51(2) 439-474.
- 2 Treatment of Osteochondrosis Dissecans of the Canine Stifle Using Synthetic Osteochondral Resurfacing. Egan P, et al. *Vet Comp Orthop Traumatol.* 2018 Feb;31(2): 144-152.
- 3 Synthetic osteochondral resurfacing for treatment of large caudocentral osteochondritis dissecans lesions of the humeral head in 24 dogs. Murphy S, et al. *Vet Surg* 2019 Jul; 48 (5): 858-868.
- 4 Evaluation of synthetic osteochondral implants. Cook JL, et al. *J Knee Surg.* 2014 Aug;27 (4): 295-302
- 5 Synthetic osteochondral resurfacing to treat osteochondritis dissecans of the medial aspect of the humeral condyle in dogs: outcome using a second generation implant (SynACART™). Fitzpatrick N, et al. *Proceedings of the 5th World Congress ESVOT-VOS.* Barcelona, September 12-15th, 2018.



## It's Not (Always) a Tumor: When to Suspect a Brain Tumor in Dogs and What We Can Do About It

Jennifer Michaels, DVM, DACVIM (Neurology)  
angell.org/neurology | neurology@angell.org | 617-541-5140



Jillian Walz, DVM, DACVIM (Medical Oncology), DACVR (Radiation Oncology)  
angell.org/oncology | oncology@angell.org | 617-541-5136

**A**lthough brain tumors are the most common cause of new-onset neurological symptoms in older dogs, it is important to keep an open mind about differential diagnoses in these patients. Some people, pet owners, and veterinarians alike will assume that simply because a dog is senior, any new onset neurological symptoms must be due to a brain tumor. Subsequently, owners may believe that their pet has few or no treatment options. This article aims to shed light on when an intracranial neoplasia should be suspected versus other causes for new onset neurological symptoms and showcase the myriad treatment options available for presumptive or definitive diagnosis of intracranial neoplasia.

### Clinical Signs and Incidence of Brain Tumors

The most common clinical signs of brain tumors depend on location. For supratentorial tumors (cerebral hemispheres, thalamus), seizures and behavioral changes are the most common clinical signs (Foster et al., 1988; Rossmeisl et al., 2013). In one report, in 75% of dogs diagnosed with a supratentorial brain tumor, a seizure was the first reported clinical signs (Schwartz et al., 2011). Central vestibular dysfunction is the most common clinical sign of infratentorial tumors (brainstem and cerebellum) (Rossmeisl et al., 2013). Most dogs with brain tumors have abnormal neurological examinations on presentation. However, up to 64% of dogs with new-onset seizures that were ultimately diagnosed with a structural brain lesion (such as a tumor) had an otherwise normal neurological examination (Pákozdy et al., 2008).

The clinical course of dogs with brain tumors is invariably progressive. Typically, the progression

is subacute (weeks) to chronic (weeks to months). For example, the average time between developing new seizures and/or behavioral changes and detecting a persistently abnormal neurological exam is reported to be 78 days (range two to 400 days) (Foster et al., 1988; Rossmeisl et al., 2013).

### Differential Diagnoses

There are many differential diagnoses other than brain tumors for new onset and/or progressive, centrally localizing neurological signs in an older dog. Some of the most important are described here with some clinical features that may help prioritize them on your differential list.

**Epilepsy of Unknown Cause:** Similar to idiopathic epilepsy, these patients have recurrent seizures without any other neurological symptoms or deficits; however, they fall outside of the IE diagnostic criteria due to the age of seizure onset.

Neurological examination is normal. This accounts for about 1/3 of dogs greater than 6 years of age presenting with seizures as the chief complaint (Hall et al., 2020)

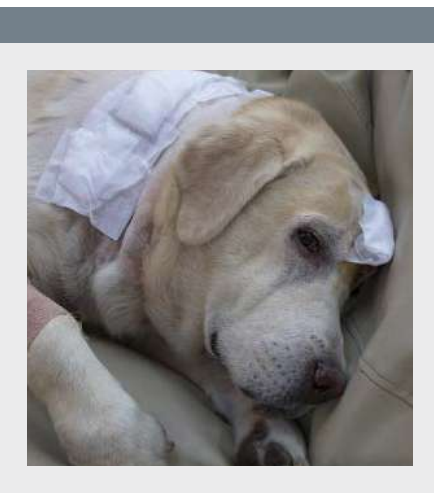
**Canine Cognitive Dysfunction Syndrome:** CCDS is a geriatric onset, chronic, slowly progressive neurodegenerative disease akin to dementia in people. Signs typically start with fairly mild behavioral changes such as increased anxiety, pacing, or restlessness at night and progress over months to years. Seizures and asymmetric symptoms such as circling are possible sequelae of CCDS.

**Ischemic stroke:** Strokes can occur anywhere in the brain and thus cause a variety of neurological signs, although the most common is vestibular syndrome. Clinical signs are per-acute onset, non-progressive, and usually spontaneously improve with time (typically hours to days for initial improvement). Strokes can recur, especially in dogs with underlying risk factors such as hypertension, hypothyroidism, renal disease, or Cushing's disease.

### Diagnosis

Definitive diagnosis of intracranial neoplasia does require advanced imaging, typically brain MRI. While tissue biopsy is required for a definitive diagnosis, 90% or more of cases were correctly diagnosed with an intracranial neoplasm based on MRI (Ródenas et al., 2011).

In many instances, pet owners cannot or do not want to pursue advanced imaging or a definitive diagnosis for the cause of their pet's neurological symptoms.



## NEUROLOGY &amp; ONCOLOGY

## It's Not (Always) a Tumor

CONTINUED FROM PAGE 6

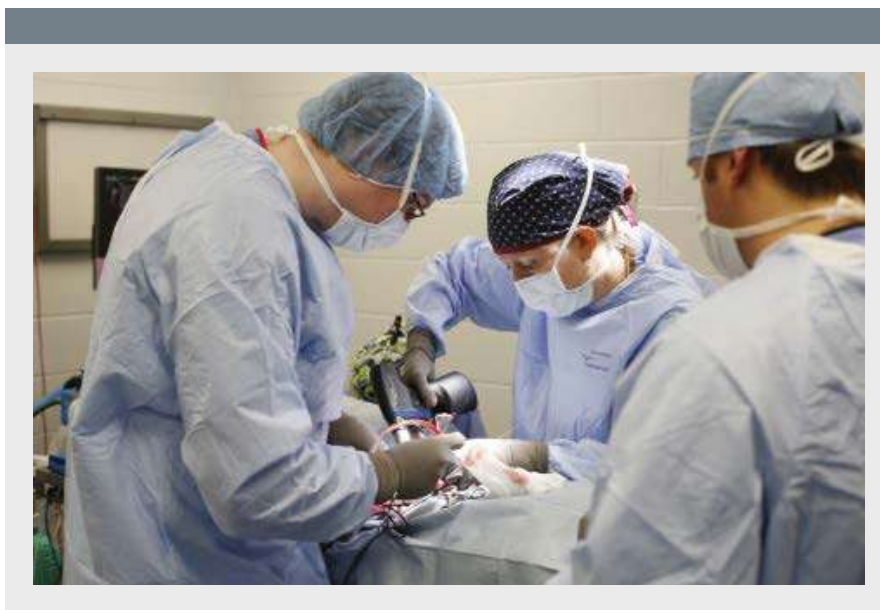

In these cases, clinical factors that can strengthen the presumptive diagnosis of a brain tumor, including:

- Geriatric patient
- New onset, acute to chronic symptoms (typically more subacute to chronic)
- Progression of symptoms over days to months
- Lack of improvement over time
- Definitive central nervous system signs
- Lateralizing, focal neurological symptoms
- Clinical improvement with empirical steroid therapy

### Palliative Care

Palliative care for a brain tumor plays a significant role in the management of both definitively diagnosed and presumptive brain tumors.

Anti-inflammatory steroids are the mainstay of palliative therapy. While steroids will generally not treat the tumor directly (excepting round cell neoplasia such as CNS lymphoma), they will reduce peri-lesional edema in the brain, significantly reducing clinical signs and improving quality of life. The recommended starting dosage is 1mg/kg/day of prednisone with a gradual taper over a few weeks. Most brain tumor patients will not tolerate being tapered completely off steroids without a recurrence of their clinical signs. The goal is to find the lowest effective dosage that maintains a good clinical state and minimizes clinical deficits. Given that this therapy is not treating the tumor, clinical signs will inevitably return as the tumor grows. When deficits progress, the prednisone dose can be incrementally increased until it ceases to control the deficits or the patient experiences dose-limiting side effects.



Even for owners that are unable or do not wish to pursue a definitive diagnosis for the cause of their pet's neurological signs, if the index of suspicion is high, it is very reasonable to consider at least a trial of anti-inflammatory steroids. Although there is no guarantee that the patient will improve, most dogs with a brain tumor will show some improvement with steroids, which should raise the index of suspicion for a presumptive brain tumor diagnosis and support continued steroid treatment.

Palliative care also importantly includes symptomatic therapy and supportive care, as needed. This includes maintenance anti-seizure therapy for patients experiencing seizures. While any maintenance anti-seizure medication can be utilized, this author prefers levetiracetam (20-30 mg/kg PO q8h), levetiracetam ER (30 to 45 mg/kg PO q12h), or zonisamide (5 to 10 mg/kg PO q12h) over the older generation anti-seizure medications such as phenobarbital or potassium bromide due to preferable side effect profile. Other important supportive care therapies could include anti-nausea medications such as maropitant (6 to 8 mg/kg PO q24h) or ondansetron (0.5 to 1 mg/kg PO q8-12h) for patients with vestibular signs or appetite stimulants, as needed.

As with any of the treatments discussed in this article, prognosis with palliative care depends somewhat on tumor type and location. However, in general, the median survival time for palliatively treated brain tumors is two to three months, with forebrain tumors being associated with a longer survival time (median: five to six months) compared to brainstem tumors (median: one month) (Hu 2015, Rossmiesl 2013).

### Surgery

The benefit of surgical treatment includes rapid decompression for those patients with large masses or masses causing marked mass effects with concern for herniation and acute decompensation as well as histologic confirmation of tumor type, thus potentially allowing for more targeted therapy options. However, given the inherent degree of invasiveness, surgery could easily be considered the riskiest of treatment options. Surgery has a mortality rate of up to 13%, and a major complication rate (e.g., worsening of neurological status, new or worsening seizures, aspiration pneumonia) of up to 18% has been reported (Kohler et al. 2018).

Surgery may not be a viable treatment option for all dogs with a brain tumor. The primary limiting factor to the utility of surgery is tumor location. In general, infratentorial and intra-axial tumors are less likely to be surgical candidates than rostral fossa or extra-axial tumors. Surgical approaches for more difficult-to-access tumors, including those of the brainstem, pituitary, and periventricular regions, have been described, although they are less commonly performed and often require specialized equipment and training not available at all institutions.

MST for surgical treatment of primary brain tumors is 10.5 months (one to 70 months) (Hu et al. 2015). Meningioma, the most common primary brain tumor in dogs, has a median survival time of approximately nine months when treated with surgery alone.

While there is clearly some benefit to considering surgery, it is less often pursued as an isolated treatment option given the availability, reduced invasiveness, and improved outcomes associated with radiation therapy. However, there are certain patients or circumstances in which surgery can be beneficial, especially if followed up with adjuvant oncologic therapy.

---

## REFERENCES

- 1 Hu H, Barker A, Harcourt-Brown T, Jeffery N. Systematic Review of Brain Tumor Treatment in Dogs. *J Vet Intern Med.* 2015;29(6):1456-1463. doi:10.1111/jvim.13617
- 2 Rossmeisl JH Jr, Jones JC, Zimmerman KL, Robertson JL. Survival time following hospital discharge in dogs with palliatively treated primary brain tumors. *J Am Vet Med Assoc.* 2013;242(2):193-198. doi:10.2460/javma.242.2.193
- 3 Hall R, Labruyere J, Volk H, Cardy TJ. Estimation of the prevalence of idiopathic epilepsy and structural epilepsy in a general population of 900 dogs undergoing MRI for epileptic seizures. *Vet Rec.* 2020;187(10):e89. doi:10.1136/vr.105647
- 4 Foster ES, Carrillo JM, Patnaik AK. Clinical signs of tumors affecting the rostral cerebrum in 43 dogs. *J Vet Intern Med.* 1988;2(2):71-74. doi:10.1111/j.1939-1676.1988.tb02796.x
- 5 Kohler RJ, Arnold SA, Eck DJ, Thomson CB, Hunt MA, Pluhar GE. Incidence of and risk factors for major complications or death in dogs undergoing cytoreductive surgery for treatment of suspected primary intracranial masses. *J Am Vet Med Assoc.* 2018;253(12):1594-1603. doi:10.2460/javma.253.12.1594
- 6 Pákozdy A, Leschnik M, Tichy AG, Thalhammer JG. Retrospective clinical comparison of idiopathic versus symptomatic epilepsy in 240 dogs with seizures. *Acta Vet Hung.* 2008;56(4):471-483. doi:10.1556/AVet.56.2008.4.5
- 7 Ródenas S, Pumarola M, Gaitero L, Zamora A, Añor S. Magnetic resonance imaging findings in 40 dogs with histologically confirmed intracranial tumours. *Vet J.* 2011;187(1):85-91. doi:10.1016/j.tvjl.2009.10.011
- 8 Rossmeisl JH Jr, Jones JC, Zimmerman KL, Robertson JL. Survival time following hospital discharge in dogs with palliatively treated primary brain tumors. *J Am Vet Med Assoc.* 2013;242(2):193-198. doi:10.2460/javma.242.2.193
- 9 Schwartz M, Lamb CR, Brodbelt DC, Volk HA. Canine intracranial neoplasia: clinical risk factors for development of epileptic seizures. *J Small Anim Pract.* 2011;52(12):632-637. doi:10.1111/j.1748-5827.2011.01131.x

## › Emergency & Critical Care Service at Angell West; Same-day Urgent Care Appointments

The Emergency & Critical Care service at the MSPCA-Angell West (Waltham, MA) is available 24/7 for clients whose pets need immediate medical care for life-threatening trauma or disease.

Referring veterinarians may alert staff to an incoming case by calling 781-902-8400.

*For more information, please visit [angell.org/emergency](https://angell.org/emergency).*

For non-emergent cases, the Urgent Care service at Angell West. Same-day appointments for dogs and cats are available Sunday through Friday, 8am-6pm by calling **781-902-8400**. Urgent Care appointments are also available through the Angell West Avian and Exotic service by calling **617-989-1561**. *For more information, please visit [angell.org/urgent](https://angell.org/urgent).*



## › Angell's Referring Vet Portal

24/7 access to your referred patients' records [angell.org/vetportal](https://angell.org/vetportal)

The Angell Referring Veterinarian Portal is a mobile-friendly service that provides secure 24/7 access to your referred patients' records. It automatically updates throughout the day and gives you access to the following:

- Online medical records
- Discharge instructions
- Referral reports
- SOAPs
- Check-in status
- Prescriptions
- Lab results
- Diagnostic images

Settings can be customized within the portal to receive notices by email or fax and you may list multiple emails to receive check-in, discharged, deceased, and update notices.

Visit [angell.org/vetportal](https://angell.org/vetportal) or call our referral coordinator at **617-522-5011** to gain access to your account.



## Trichiasis, Ectopic Cilia, and Distichia: T.E.D. Talk on Eyelash Problems in Dogs and Cats

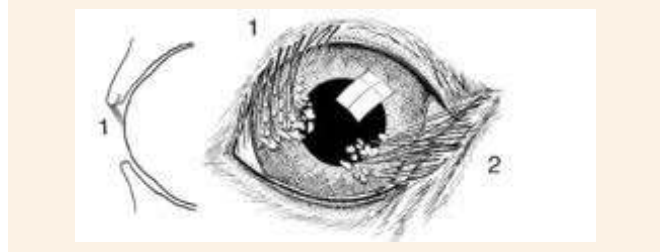Daniel Biros, DVM, DACVO  
angell.org/eyes | eyes@angell.org | 617-541-5095

### What are the three most common eyelash anomalies?

**T**richiasis is the most common eyelash irregularity, with ectopic cilia and distichiae occurring less frequently. However, distichiae and ectopic cilia are still recognized as more clinically severe disorders in contrast to trichiasis due to their overall increased morbidity. All three abnormalities can potentially cause ocular surface changes ranging from mild increased tearing or mucus to corneal ulceration and infection. Without correction, some of the resulting ocular changes caused by eyelash deviations can damage vision with permanent scarring and pigmentation or, at worst, corneal perforation and loss of vision.

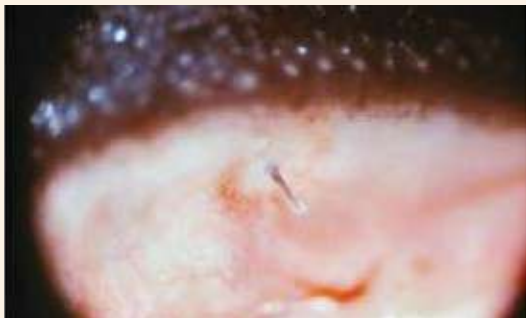### Definitions

**Trichiasis** are hairs that originate in a normal location on the skin around the eye but are oriented in an abnormal direction (see below).

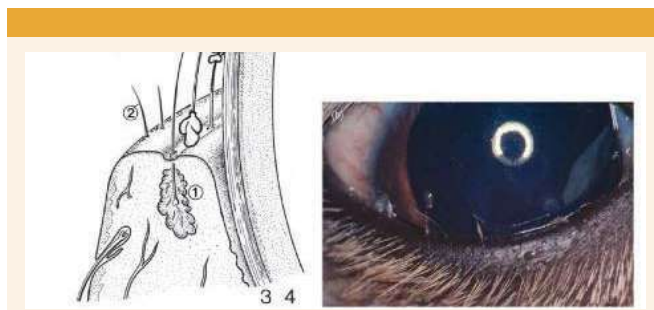


**Ectopic cilia** are hairs that grow specifically through the conjunctival surface of the inner eyelids and contact the corneal surface, eliciting varying degrees of pain and damage (see below).

› Photograph courtesy Dr. Kirk N. Gelatt.)



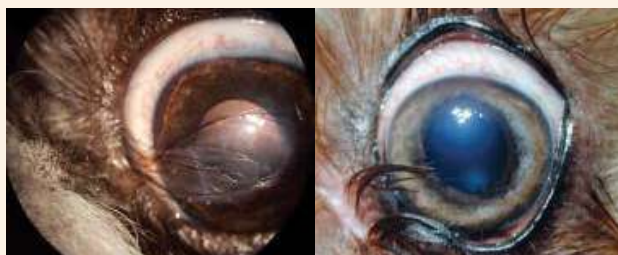**Distichiae** are hairs that grow in an abnormal location on the eyelid margin (specifically emanating from gland ducts) and are commonly oriented in an inward direction toward the ocular surface (see top right).



### Trichiasis is everywhere you look, so when is it a problem?

Causes for trichiasis include congenital eyelid agenesis, entropion, ptosis, trichomegaly, and cicatricial eyelid conformation (scarring). Among the three types of eyelash changes discussed in this article, trichiasis tends to be the least prevalent clinically as a clinical problem, but it is associated with more persistent mild to moderate irritation. Dogs with long hair around the eyes, such as Shih Tzus, poodles, terriers, Maltese, Havanese, and Bichons, often exhibit varying degrees of trichiasis, which can be more pronounced when other ocular surface issues such as dry eye, nasolacrimal duct congestion, or entropion are also present. For many longer-haired brachycephalic dogs, trichiasis often manifests in conjunction with nasal entropion, which for most is minor and not a true clinical problem in and of itself. In some situations, however, chronic trichiasis will lead to lasting corneal changes, including pigmentation, scarring, and neovascularization. This is often a characteristic of pugs, Pekingese, and Shih Tzus, where varying shades of pigmentation appear in the nasal regions of the cornea, ranging from minor enhanced limbal pigmentation to triangular, whirling scarring to complete clouding over most of the cornea, thereby affecting vision.

Trichiasis can often be found in the nasal or lateral canthus and stem from the medial caruncle (below on the left) or the skin between the nose and the eye (below on the right). Trimming the hairs short may temporarily alleviate the clinical signs in cases with ocular surface irritation or worse (corneal abrasion or ulceration).



## OPHTHALMOLOGY

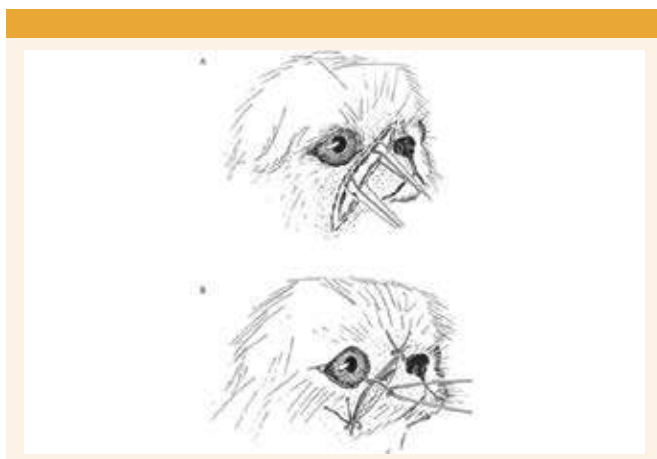
## Trichiasis, Ectopic Cilia, and Distichia: T.E.D. Talk on Eyelash Problems in Dogs and Cats

CONTINUED FROM PAGE 10

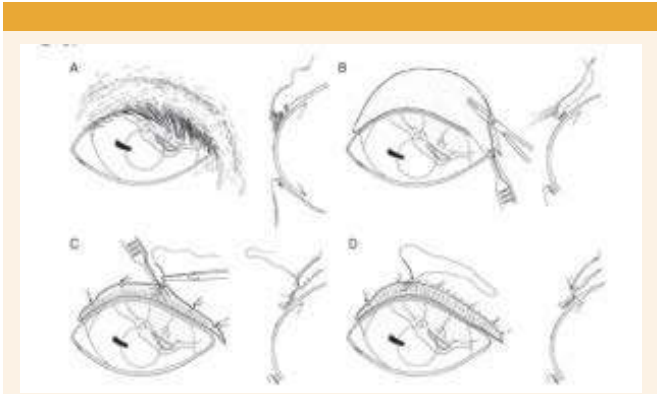


Others with the same condition, most notably young pugs with advancing corneal pigmentation from the nasal region of the ocular surface, can be treated with medial canthoplasty (above).

Some breeds, such as Pekingese with chronic facial (nasal) fold trichiasis, will benefit from elective surgery to reduce the size of the folds and increase the distance from the apex of these external skin folds and the ocular surface (below).

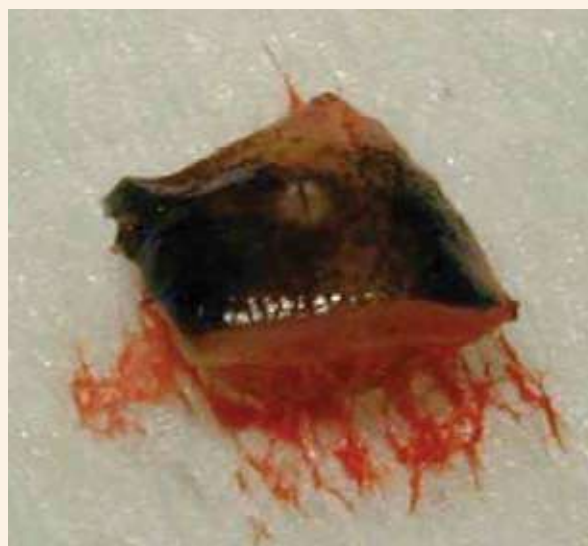

Finally, in older dogs, geriatric ptosis, or upper eyelid drooping, can develop, resulting in previously normal eyelashes constant contact with the ocular surface. With each blink, they trigger surface sensitivity, corneal irritation, and inflammation. For those with notable surface sensitivity, squinting, tearing, ulceration, eyelid modification such as a Stades correction (below) may be beneficial to remove the [geriatric] trichiasis and correct any ptosis or entropion.



## Ectopic Cilia are a real threat. What can be done?

While not all cases of trichiasis need correction, every patient who has ectopic cilia should be evaluated with corrective measures in mind. Ectopic cilia can happen in any breed, either solitary or in clusters, which tend to be the most acute and irritating eyelash anomalies. Due to their small size and location, they can also be the most difficult to diagnose. Once identified, complete epilation provides immediate relief and at least temporary reprieve from further irritation, and reduced risk for recurrence in the short term. It is impossible to predict if these hairs will grow back, but it is important that all patients have appropriate follow up in days to weeks to ensure healing is taking place and the patient is improved. In hard-to-reach or recurrent cilia that continue to irritate, brief general anesthesia may be helpful for dedicated plucking or surgical sharp resection of the offending hairs, including the follicles (see below).



Focal cryosurgery (with proper ocular and skin protection in place) under general anesthesia can also help reduce the risk of regrowth and is typically reserved for more difficult cases. Clinical handheld cautery can also be effectively used to eliminate ectopic cilia but is used with caution because not only could it burn bystander tissue, including the cornea, but cautery may also leave a crusting residue on the conjunctival surface that could contribute to further irritation.

Congenital anomalies, including conjunctival tunnels or pseudo-openings in the palpebral conjunctival surface, can allow ectopic cilia to appear, and many are found within these small circular conjunctival areas that resemble modified conjunctival structures conducive to the presentation or hairs on the conjunctiva (see above). In some breeds, like Shih Tzus, nests of ectopic cilia can be seen beneath the near-transparent conjunctival surface. While they are not breaking through to cause ocular surface irritation, once documented, they should be monitored carefully for eruption through the conjunctival surface and subsequent development of clinical irritation.

## Are all Distichiae created equal?

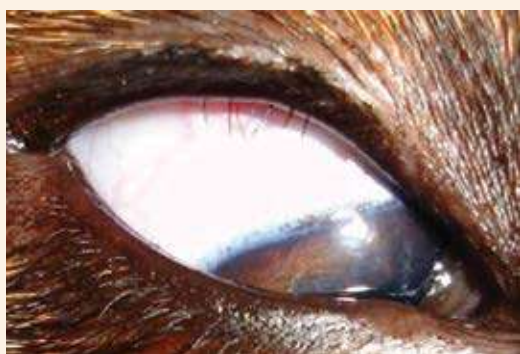Distichiasis is the most common of all eyelash conditions in practice that produces severe acute or chronic clinical disease. It is important to remember that many dogs go through life with soft distichiae, and it seldom causes any problems. Almost all cocker spaniels, for example, have soft numerous

## OPHTHALMOLOGY

## Trichiasis, Ectopic Cilia, and Distichia: T.E.D. Talk on Eyelash Problems in Dogs and Cats

CONTINUED FROM PAGE 11

distichia but never have a problem with ocular surface irritation solely due to the hairs alone. Contrast that to a pug, Boston terrier, or bulldog with chronic irritation and corneal scarring from just a few hairs (below). Distichiae arise from normal skin hair follicles that produce hair shafts that utilize the Meibomian or accessory eyelid margin gland openings and follow the path of least resistance onto the eyelid margin. When distichiae are causing corneal damage or are suspected to be the cause of ocular surface pain, they should be removed. Options are manual plucking or surgical removal (more on this later). Distichiae may be rooted or loose, clustered, or single. The distichiae on a poodle will generally be thin, spiraled, and soft, while those found in a French bulldog or boxer will often be straight, stout, and sharp (see bottom), consistent with the type of hair coat found in the breed.



Distichia can be more problematic in dogs with coexisting eyelid conformation problems, such as English bulldogs, Newfoundlands, Mastiffs, and St. Bernards, where entropion or ectropion can exacerbate the situation. In some of these more complicated patients, multiple surgeries in series may be needed to fully correct the clinical problems (e.g., distichia cryoepilation or plucking followed by entropion repair weeks later). In practice, if a distichia is loose, it may not regrow in the same area. But if it is rooted, then regrowth is expected. Within a given cluster, most hairs will be loose, and the final or last hair to come out is rooted, suggesting a single active follicle is responsible for all the hairs in that cluster. In some breeds and patients, pinning ocular surface irritation on distichiae alone is not always easy. Golden retrievers are one of the breeds where we can see fine, rooted distichia but cannot always tell if it contributes to ocular surface irritation. It is not a bad idea to look for ectopic cilia if distichiae is seen in any clinical patient. It is just to be thorough, as both can be present in any individual with signs of irritation. For plucking any eyelid hairs, veterinarians will use some magnification, often a head loupe or a slit lamp biomicroscope, the best manual restraint possible, topical anesthetic such as proparacaine, calm, steady hands, and an able forceps such as a Jeweler's forceps (see below).



Do not hesitate to consider sedation and even brief general anesthesia for plucking distichiae in more anxious or fractious pets.

### I have plucked, now what?

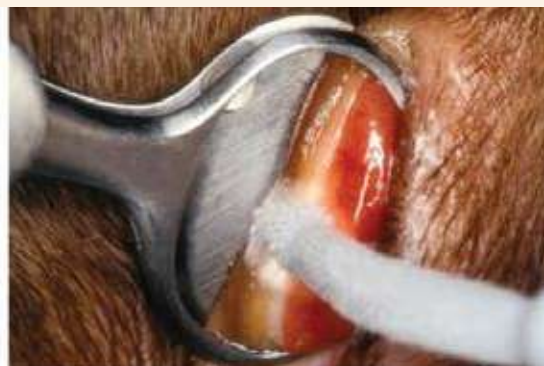Supportive care will be important for all types of eyelash conditions. After plucking the offending hairs, careful monitoring will be key to prevent future

problems. For ectopic cilia and distichiae, a recheck visit in about four to eight weeks is suggested to monitor for regrowth, sooner if it is suspected there may have been some hairs left behind. The exact timing the hairs can come back is tricky to predict, but if regrowth is seen at the follow-up examinations, then re-plucking or considering a more definitive treatment (surgical removal of the hairs) should be considered if there are ongoing signs of clinical irritation (tearing, discharge, redness, corneal abrasions, etc.). Supportive medical care can include topical, non-medicated lubricants (artificial tears) for the non-ulcerated, minimally affected eye. For superficial ulcerated corneas or more significant conjunctivitis and keratitis, consider a short course of topical antibacterials, systemic pain medication, and E-collar as needed. Placement of soft contact bandage lenses on the cornea can also be helpful for some to protect the eye as it recovers, especially if some distichiae are left behind. Dry eye should always be ruled out as a factor for surface irritation, and unfortunately for many brachycephalics, dry eye, and distichia are commonly found together. If keratoconjunctivitis sicca is present, then specific dry eye treatment should be implemented (cyclosporine, etc.).

### When is surgery the solution?

When a particular patient keeps returning for the same manual plucking over and over, it may be time to think about surgical removal of the abnormal eyelashes. This is true for all three conditions discussed today. Having said that, some patients and clients are perfectly fine with coming in every couple of months for manual plucking, especially if it is only one or two hairs (often distichia), and the patient is tolerant to the periodic visits and manual restraint needed for this. All eyelash conditions are dynamic, so even after definitive surgery, recurrence is possible. This must be emphasized to all clients. While it only takes one hair to cause significant pain and trauma, in the context of surgery, resolution of eyelash irritation is a numbers game, and all visible, offending hairs should be removed from the area to give the best chance for a good recovery. This holds true especially for distichiae. However, medical management and manual plucking may be the only option if a patient is not a suitable anesthesia candidate.

By far, the most common way we surgically remove distichia is by cryoepilation (see below).



It is a straightforward and highly effective surgery but technically can take a long time, especially if there are multiple distichiae on all eyelids. If the distichiae follicles are frozen and destroyed, no more distichiae can be made. Cryosurgery can be fraught with pitfalls if not done correctly, including skin or eye damage from the liquid nitrogen (corneal shields and towels must be in place), abnormal eyelid scarring, and even eyelid necrosis if done too aggressively, leaving the patient with no eyelid. In rare cases, severe corneal ulceration can complicate recovery and require conjunctival grafting surgery to save the eye. For these reasons, we recommend having this procedure done

## OPHTHALMOLOGY

## Trichiasis, Ectopic Cilia, and Distichia: T.E.D. Talk on Eyelash Problems in Dogs and Cats

CONTINUED FROM PAGE 12

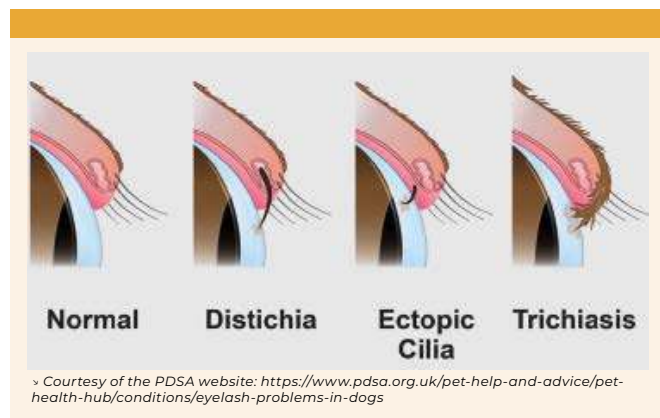
by a boarded ophthalmologist. Skin depigmentation and minor eyelid margin scarring are common but should not affect eyelid functionality, and the effects of the freezing are more severe in smaller breeds with thinner eyelids. Alternatively, sharp excision may be appropriate for one or two hairs, ensuring that complete follicle resection is achieved and eyelid margin confluence is preserved.

### Playing the long game with T.E.D.

Hopefully, this information provided a better understanding of the distinction and clinical approaches to the more common eyelash issues in dogs. Just remember T.E.D.: trichiasis, ectopic cilia, and distichia. While distichiasis is the more common clinically relevant problem seen in clinical practice, all types can lead to serious discomfort—even vision loss—without proper recognition and treatment. Ectopic cilia and distichiae have more potential to cause acute pain and more significant corneal damage. Trichiasis (especially nasal trichiasis) may be the most common observed condition of the three, but it is not always a clinical problem.

The options for treatment for all eyelash problems are variable and may range from a simple one-time pluck to more extensive surgery. In all scenarios, the follow-up is never truly complete, as the specter of recurrence is always there. Fortunately, for most cases with the right approach, there is a point when a) the patient is finally better, b) monitoring and visits become infrequent, and c) the condition does not return.

In conclusion, the distinct types of eyelash problems are illustrated below:



### REFERENCE

Gelatt, Kirk N. and Gilger, Brian C. *Veterinary Ophthalmology: Two Volume Set.*



## The Vomiting Dog and Cat: An ER Perspective

Elton Chan, DVM  
angell.org/emergency | emergency@angell.org | 617-522-7282

**T**he vomiting patient is among the top three clinical reasons families bring their pets to see the veterinarian! As such, explaining a basic workup from an ER veterinarian's perspective is helpful so that a client can understand why certain diagnostic tests and treatments are offered to manage the vomiting patient.

Vomiting is a fairly non-specific symptom, and causes can be broken down into two major subcategories: causes of vomiting that come from **INSIDE** the gastrointestinal system versus causes of vomiting that originate from **OUTSIDE** the gastrointestinal system.

From **INSIDE** the gastrointestinal system, common causes of vomiting include (but are limited to) gastroenteritis (like food poisoning or having a stomach flu), mechanical obstruction (i.e., from an object lodged in the GI tract), and parasites like a giardia infection. Examples of other causes include flare-ups of chronic enteropathies such as inflammatory bowel disease, gastrointestinal cancer, etc.

From **OUTSIDE** the gastrointestinal system, examples of problems that can cause vomiting include (but are not limited to) acute kidney injury, acute liver injury, hypoadrenocorticism (Addison's Disease, which is a chronic hormonal deficiency), pancreatitis, etc.

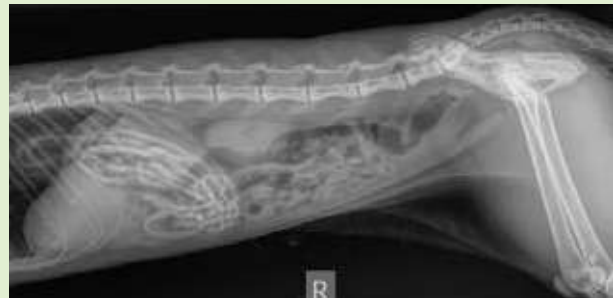Ruling out potential causes and narrowing down the list of possibilities involves collecting a detailed history from the client, performing a thorough physical examination, and utilizing additional diagnostic tests.

### Signalment and History

From an ER perspective, the patient's signalment and medical history help prioritize the list of differential diagnoses.



› Cat with hair ties in stomach – later successfully removed via endoscopy.



For example, the patient's history can help answer questions on chronicity versus acuteness. Some dogs/cats have chronic problems of vomiting (such as the dog who has been vomiting twice weekly for six months and may have underlying inflammatory bowel disease) versus an acute problem, such as the 8-week-old puppy who is infected with canine parvovirus and is critically ill. Some families will report that they recently changed a pet's food without a transition protocol, which helps explain some cases of vomiting. Other families may report a recent history of kenneling the dog at a boarding facility with an outbreak of giardia. Other cases may involve reports of known ingestion of toxins such as chocolate, rat poison, or other noxious compounds. We use the history to help narrow the list of differentials and guide diagnostic tests and treatments.

### Physical Exam

The physical exam tends to be fairly non-specific for most vomiting patients. Individual findings on physical exams can help establish levels of concern to create a holistic clinical picture of the patient before making a diagnosis and recommendation.

For example, an elevated body temperature may suggest the presence of pneumonia secondary to accidentally inhaling vomit; however, a pet may have an elevated body temperature from being overly excited/anxious and trembling in the exam room. Yellowing of the skin and eyes may indicate excess bilirubin in the bloodstream from liver dysfunction, rapid destruction of red blood cells, or obstruction of the biliary system. Dry/tacky gums and reduced skin elasticity may indicate significant dehydration due to vomiting and nausea. Acute abdominal pain can be a marker of something mild (like a mild case of gastroenteritis or pancreatitis) or something life-threatening (like a ruptured spleen or a mechanical obstruction of the intestines). In rare cases, diagnosing the problem outright on physical exam is possible. These cases include finding a linear foreign body, such as a string, lodged around the patient's tongue with the trailing end descending into the stomach and intestines, leading to a mechanical obstruction. You can sometimes even feel a large foreign object, such as a toy or corn cob, within the intestines of some

## EMERGENCY &amp; CRITICAL CARE

## The Vomiting Dog and Cat: An ER Perspective

CONTINUED FROM PAGE 14

patients; however, caution must be taken from OVER-interpreting a physical exam. The “foreign object” you think you are feeling in the intestines may just be feces.

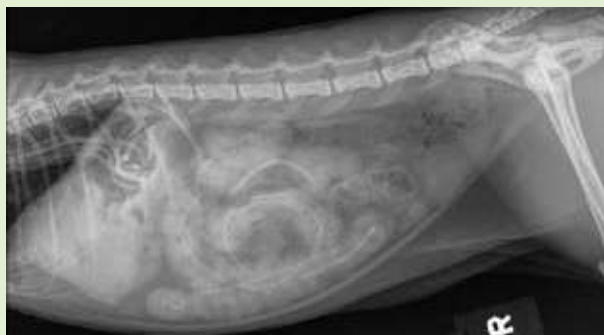As such, the physical exam should not be relied upon solely to make the final diagnosis for the patient, and the focus should be directed toward gathering more clinical data to guide the prioritization of diagnostic testing.

### Diagnostic Tests

Thousands of diagnostic tests are available to test for thousands of different diseases. It is helpful to break down tests into two major categories: lab work and imaging. Lab work (testing blood and/or urine) typically helps investigate for causes of vomiting that start from outside the gastrointestinal tract. For example, a common test would be a serum chemistry panel, which may return results reflecting the health/function of the kidneys, liver, blood sugar, electrolytes, and other important markers. This blood test can help screen for injury/dysfunction with those organs that may be contributing to the pet’s nausea and vomiting; however, it is important to note that one cannot assume that irregularities found on lab work are the primary CAUSE of the patient’s illness.

In some cases, liver/kidney dysfunction on lab work may be a manifestation/result of some other underlying disease process, and this reflects a chicken-vs-the-egg problem of knowing which issue came first. Other common laboratory tests to perform would include pancreatic lipase screening, complete blood count, baseline cortisol testing, etc. There are thousands of available lab tests, and the clinician uses the patient’s history and physical examination to help prioritize which test would be the highest-yielding vs. which tests would be low-yield (rather than submitting every possible lab test). The serum chemistry panel tends to be the highest-yielding for its price point when investigating problems with the vomiting patient. It helps rule out significant liver/kidney dysfunction or severe electrolyte changes that could be contributing to the patient’s nausea. Essentially, it helps rule out some “emergency” or “critical” causes of illness.

> Linear foreign body causing plication and obstruction of the intestines (surgical emergency).

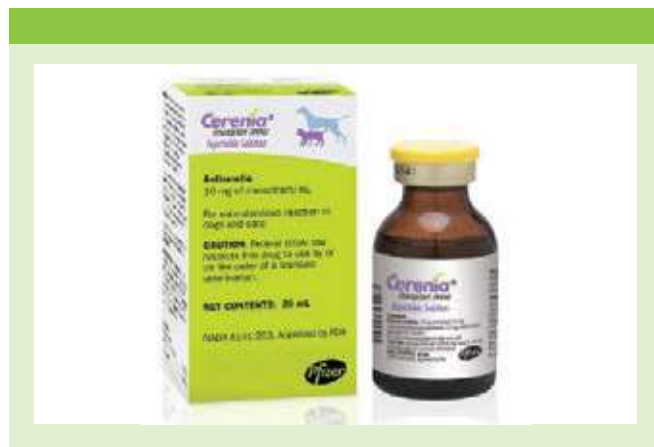

The other category of diagnostic tests involves diagnostic imaging. Numerous imaging modalities span from radiographs (using x-ray radiation to create 2D images), abdominal ultrasound, CT, fluoroscopy, MRI, etc. For most basic cases of vomiting, a routine screening tool with good yield and a relatively low price point would be the radiograph. For the vomiting patient, imaging aims to answer two important questions: (1) Is there something foreign that doesn’t belong in the GI tract? (2) Is there evidence of a mechanical obstruction requiring surgery? Occasionally, we may find other things on radiographs, such as an abdominal tumor, bladder stones, etc. That

being said, radiographs do not provide the answer 100% of the time, and it is not uncommon to escalate to more advanced testing if we cannot achieve an answer on radiographs alone. In one study of vomiting dogs with concerns of a mechanical obstruction from a foreign body, radiography produced a definitive result in 70% of dogs (58/82). In contrast, ultrasonography produced a definitive result in 97% of dogs (80/82).<sup>2</sup> Each diagnostic test has its own pros/cons based on both logistical availability and the physics underpinning each modality. For example, a set of abdominal radiographs may cost \$400 and is readily available, whereas an ultrasound may cost \$800 and require an appointment due to limited availability.

### Treatment

Treatment and prognosis of the vomiting patient will ultimately depend on the underlying diagnosis based on the diagnostic tests mentioned above. Hospitalization with more advanced diagnostic tests would be warranted if lab work returned with significant dysfunction of the liver, kidneys, pancreas, or electrolytes. Surgery would likely be warranted if a mechanical obstruction was diagnosed on abdominal imaging. In the best case scenario, all diagnostic tests return NORMAL with NO EVIDENCE of liver dysfunction, kidney dysfunction, severe electrolyte changes, severe pancreatic enzyme elevation, or surgical obstruction of the gastrointestinal tract. In these cases, the most common cause is gastroenteritis, which is generally manageable on an outpatient basis. Outpatient treatment typically involves an injection of fluids as well as an anti-nausea drug such as Cerenia (maropitant) to pharmacologically block the vomiting for approximately 24 hours. This simple protocol is usually sufficient for the majority of patients suffering from something mild, such as gastroenteritis. No diagnostic tests are 100% predictive of a given problem, and further escalation to more advanced testing and possible hospitalization would be recommended if the patient FAILS outpatient therapy (vomiting, lethargy, and anorexia despite injections of fluids and anti-nausea medication).



### REFERENCES

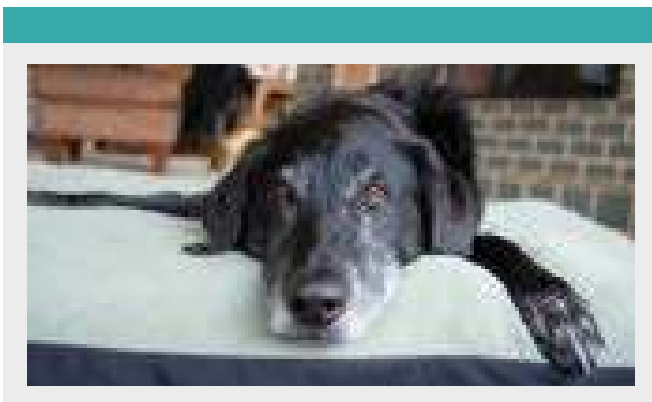
- 1 Robinson NJ, Dean RS, Cobb M, Brennan ML. Investigating Common Clinical Presentations in First Opinion Small Animal Consultations Using Direct Observation. *Vet Rec.* 2015 May 2;176(18):463. Doi: 10.1136/vr.102751. Epub 2015 Jan 6. PMID: 25564472; PMCID: PMC4431344.
- 2 Sharma, A., Thompson, M.S., Scrivani, P.V., Dykes, N.L., Yeager, A.E., Freer, S.R. and Erb, H.N. (2011), Comparison of Radiography and Ultrasonography for Diagnosing Small-Intestinal Mechanical Obstruction in Vomiting Dogs. *Veterinary Radiology & Ultrasound*, 52: 248-255. <https://doi.org/10.1111/j.1740-8261.2010.01791.x>



## Hypoadrenocorticism in Dogs

Lisa Gorman, DVM, DACVIM  
angell.org/internalmedicine | internalmedicine@angell.org | 781-902-8400

**H**ypoadrenocorticism, also known as Addison's disease, is an uncommon but important endocrine disease of dogs. This disorder results from adrenal cortical failure, which is presumed in most cases to result from immune-mediated destruction of the adrenal cortex. However, this has rarely been shown to occur due to other causes in dogs, including bilateral adrenal neoplasia, infarction, or granulomatous disease due to systemic fungal infections.<sup>1</sup> In most dogs with hypoadrenocorticism, this destruction occurs in all layers of the adrenal cortex, resulting in signs of both glucocorticoid and mineralocorticoid deficiency. These patients are commonly referred to as having typical or classic hypoadrenocorticism. However, in up to 30% of patients with hypoadrenocorticism, there are no electrolyte abnormalities that would suggest a mineralocorticoid deficiency, and the signs are exclusively due to glucocorticoid deficiency; these patients are referred to as having atypical or glucocorticoid-deficient hypoadrenocorticism.<sup>1</sup> Although it was long assumed that patients with atypical hypoadrenocorticism had selective destruction of the adrenal cortex that resulted in sparing of the zona glomerulosa, the layer that produces mineralocorticoids, studies have shown variable aldosterone levels in patients with atypical hypoadrenocorticism. These have ranged from very low levels consistent with classic mineralocorticoid deficiency,<sup>2</sup> to normal aldosterone levels that would suggest sparing of the zona glomerulosa.<sup>3</sup> Patients with atypical hypoadrenocorticism may progress to typical hypoadrenocorticism over time. However, this is only reported in 9% to 14% of patients, indicating that most atypical dogs will remain atypical.<sup>3,4</sup>



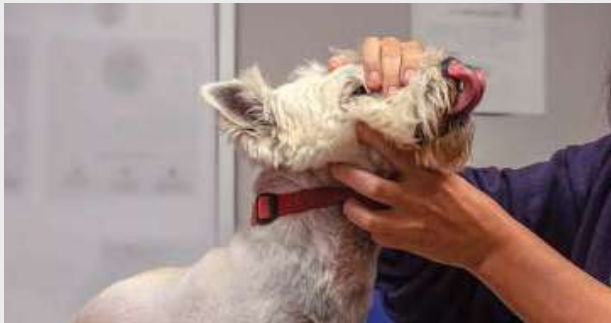Hypoadrenocorticism in dogs is most common in young to middle-aged dogs, although it has been reported in patients ranging from 4 months to 14 years of age.<sup>1</sup> A female sex predilection has generally been described, although it is not replicated in all studies.<sup>1,5,6</sup> One recent study showed that spayed or neutered dogs had a significantly higher risk of developing hypoadrenocorticism than intact dogs.<sup>7</sup> Certain breeds have a much higher risk of developing hypoadrenocorticism. Hypoadrenocorticism is inherited as an autosomal recessive trait in the Standard Poodle, Nova Scotia Duck Tolling Retriever, and Portuguese Water Dog. Other breeds at increased risk

include the Bearded Collie, Great Dane, West Highland White Terrier, and Wheaten Terrier, among others.<sup>1</sup>

Clinical signs of hypoadrenocorticism are generally non-specific, including lethargy, reduced appetite, vomiting, diarrhea, weakness, and shaking. Patients with typical hypoadrenocorticism frequently present in an acute crisis, with signs of hypovolemic shock, collapse, or severe dehydration. Patients with atypical hypoadrenocorticism are more likely to present with chronic or waxing and waning clinical signs and have been shown to have a longer duration of signs preceding diagnosis compared to patients with typical hypoadrenocorticism.<sup>3</sup> Less commonly, hypoadrenocorticism may result in melena or hematochezia.<sup>1,8</sup> Rarely, megaesophagus may occur in patients with hypoadrenocorticism,<sup>9</sup> and there have been recent case reports of patients with hypoadrenocorticism that have an acquired dilated cardiomyopathy similar to what has been described in some human Addisonian patients.<sup>10,11</sup>

Typical hypoadrenocorticism will result in classic electrolyte disturbances secondary to aldosterone deficiency, including hyperkalemia, hyponatremia, hypochloremia, and metabolic acidosis. The lack of aldosterone leads to renal sodium wasting and, thus, an inability to conserve water, which is what results in the marked hypovolemia and dehydration often noted in these patients. Although patients with typical hypoadrenocorticism often present in hypovolemic shock, their hyperkalemia may cause bradycardia, leading to heart rates much lower than expected for a patient in shock. Therefore, bradycardia in the face of hypotension or hypovolemia should increase the index of suspicion for hypoadrenocorticism. Prerenal azotemia secondary to hypovolemia is common in patients with typical hypoadrenocorticism. However, this may be easily mistaken for a renal azotemia due to reduced urine concentrating ability secondary to the washout of sodium from the kidneys. Hypercalcemia is seen in approximately 34% of patients with hypoadrenocorticism and is more common in patients with typical vs. atypical disease.<sup>12</sup> Other common biochemical abnormalities include hypocholesterolemia, hypoalbuminemia, and hypoglycemia. Hypocholesterolemia and hypoalbuminemia are more common in dogs with atypical hypoadrenocorticism,<sup>3</sup> which may further complicate the diagnosis of hypoadrenocorticism in these cases as these abnormalities can also be seen with protein-losing enteropathy and hepatic dysfunction. Thirty percent of dogs with hypoadrenocorticism will have mild elevations in hepatic enzymes, and changes in complete blood count may include lymphocytosis, eosinophilia, non-regenerative anemia, and a lack of stress leukogram in an ill patient.<sup>1</sup>

A definitive diagnosis of hypoadrenocorticism is confirmed with an ACTH stimulation test. This test should be performed by measuring cortisol levels before and one hour after administration of a 5 µg/kg intravenous dose of synthetic ACTH (cosyntropin). Dogs with hypoadrenocorticism will fail to have any stimulation of cortisol production and thus will have pre- and post-ACTH cortisol levels <2 µg/dl, although most Addisonian patients will have a cortisol level <1 µg/dl for both pre- and post-ACTH cortisol levels.<sup>1</sup> It is



important to keep in mind that recent or current corticosteroid administration may alter ACTH stimulation test results. This can occur if the patient has had a steroid medication that may read falsely as cortisol. Still, it can also occur if the recent administration of a steroid medication has resulted in suppression of endogenous cortisol production. In patients with severe illness or a very high suspicion of hypoadrenocorticism, the ACTH stimulation test should be the first-line test. However, in patients who are suspected of potentially having atypical hypoadrenocorticism or who have more mild or chronic clinical signs, starting with a single basal cortisol measurement can be a useful screening test. Multiple studies have shown that a single basal cortisol level  $>2 \mu\text{g/dl}$  effectively rules out hypoadrenocorticism.<sup>13,14,15</sup> In patients with a cortisol level  $\leq 2 \mu\text{g/dl}$ , an ACTH stimulation test is required to determine whether hypoadrenocorticism is present.

Treatment of hypovolemic patients should focus on fluid resuscitation with crystalloids and emergency treatment of hyperkalemia if required. Historically, 0.9% saline was recommended for Addisonian patients. Still, many clinicians prefer a buffered replacement crystalloid solution such as lactated Ringer's solution or Normosol-R to avoid the acidifying effects of 0.9% saline.<sup>1</sup> Ideally, an ACTH stimulation test should be done before any glucocorticoid supplementation is given. However, if this is not possible or the patient is unstable, dexamethasone can be administered prior to an ACTH stimulation test, as it is not read as cortisol by most assays. Glucocorticoid supplementation in the acute phase of illness should be suprathysiologic to account for the patient's current state of illness and long-term lack of endogenous glucocorticoids leading up to presentation. Recommendations vary, but a 1 to 2 mg/kg/day prednisone equivalent dose is a reasonable starting dose for acute treatment, and this should be reduced over time as the patient improves. Typically, dexamethasone is used intravenously in the acute phase of treatment during hospitalization before the patient is transitioned to oral prednisone for long-term therapy. In the long term, patients should



be administered a physiologic dose of prednisone daily. For most dogs, a physiologic dose of prednisone will be between 0.1 to 0.2 mg/kg/day, but some dogs are very sensitive to the effects of prednisone and may require even lower doses for physiologic glucocorticoid replacement.<sup>1</sup> The dose can be reduced until the patient shows no signs of steroid excess and clinical signs remain controlled. Because the normal daily prednisone dose is meant to mimic the physiologic production of cortisol, this dose may not be adequate for Addisonian dogs in stressful situations. Therefore, the daily steroid dose should be doubled in times of stress. What counts as a stressful situation will vary from dog to dog and may include things like boarding, travel, having visitors to the family, and veterinary visits.

Mineralocorticoid supplementation in dogs with typical hypoadrenocorticism is best achieved with DOCP (desoxycorticosterone pivalate), a long-acting synthetic mineralocorticoid with no glucocorticoid activity. The published starting dose for this medication is 2.2 mg/kg IM or SC every 25 days.<sup>1</sup> However, multiple studies have shown that most dogs can be controlled on significantly lower doses of DOCP or with longer dosing intervals,<sup>16,17</sup> so a lower starting dose of 1.5 mg/kg every 25-28 days could be considered.<sup>16</sup> A lower dose may be a good option in patients  $>3$  years of age, as one study showed that these dogs had a significantly lower DOCP requirement than younger patients.<sup>16</sup> Electrolytes should be rechecked two weeks after the first DOCP dose is administered to ensure normalization of sodium and potassium has occurred. Electrolytes should also be rechecked immediately prior to the next DOCP injection to ensure they remain normal; if they are normal at this time, the dosing interval can be increased by several days, with the goal for most patients being to achieve a monthly dosing interval as this is generally the best option for owner compliance. Once an ideal dosing regimen is established for DOCP, owners may opt to administer these injections subcutaneously at home, helping to reduce the overall cost of treatment. Fludrocortisone, an oral mineralocorticoid with some glucocorticoid activity, can be used instead of DOCP, but it tends to be more challenging. This is both because it results in less consistent control of electrolytes than DOCP in many patients and because the glucocorticoid activity may result in signs of iatrogenic hyperadrenocorticism even when prednisone is not administered concurrently.<sup>1</sup> Therefore, DOCP is recommended over fludrocortisone for mineralocorticoid supplementation in Addisonian dogs.

The prognosis for patients with hypoadrenocorticism is excellent, and prolonged survival is expected with appropriate treatment. Although hypoadrenocorticism is a relatively rare disease, it is an important differential diagnosis to consider in patients with consistent clinical signs and laboratory abnormalities, as it is a life-threatening but highly treatable disease with an excellent prognosis.

## REFERENCES

- 1 Feldman E, Nelson R, Reusch C, Scott-Moncrieff J, Behrend E. 2015. *Canine and Feline Endocrinology* (4th ed.). Saunders.
- 2 Baumstark E, Sieber-Ruckstuhl N, Müller C, Wenger M, Boretti F, Reusch C. Evaluation of aldosterone concentrations in dogs with hypoadrenocorticism. *J Vet Intern Med* 2014; 28: 154-159.
- 3 Thompson A, Scott-Moncrieff J, Anderson J. Comparison of classic hypoadrenocorticism with glucocorticoid-deficient hypoadrenocorticism in dogs: 46 cases (1985-2005). *J Am Vet Med Assoc* 2007; 230: 1190-1194.
- 4 Wakayama J, Furrow E, Merkel L, Armstrong P. A retrospective study of dogs with atypical hypoadrenocorticism: a diagnostic cut-off or continuum? *Journal of Small Animal Practice* 2017; 58: 365-371.
- 5 Hanson J, Tengvall K, Bonnett B, Hedhammar Å. Naturally

## INTERNAL MEDICINE

## Hypoadrenocorticism in Dogs

CONTINUED FROM PAGE 17

- occurring adrenocortical insufficiency—an epidemiological study based on a Swedish-insured dog population of 525,028 dogs. *J Vet Intern Med* 2016; 30: 76-84.
- 6 Schofield I, Woolhead V, Johnson A, Brodbelt D, Church D, O'Neill D. Hypoadrenocorticism in dogs under UK primary veterinary care: frequency, clinical approaches and risk factors. *Journal of Small Animal Practice* 2021; 62: 343-350.
- 7 Treeful A, Searle K, Carroll D, Yost K, Hedger A, Friedenbergs S. A case-control survey study of environmental risk factors for primary hypoadrenocorticism in dogs. *J Vet Intern Med* 2023; 37: 2073-2083.
- 8 Hauck C, Schmitz S, Burgener I, Wehner A, Neiger R, Kohn B, Rieker T, Reese S, Unterer S. Prevalence and characterization of hypoadrenocorticism in dogs with signs of chronic gastrointestinal disease: a multicenter study. *J Vet Intern Med* 2020; 34: 1399-1405.
- 9 Lifton S, King L, Zerbe C. Glucocorticoid deficient hypoadrenocorticism in dogs: 18 cases (1986-1995). *J Am Vet Med Assoc* 1996; 209: 2076-2081.
- 10 Jett L, Mooshian S, Anderson E. Acquired systolic dysfunction and subsequent congestive heart failure following treatment of hypoadrenocorticism in two dogs. *J Am Anim Hosp Assoc* 2022; 58: 297-302.
- 11 Riggs A, Rhinehart J, Cooper E. Possible development and resolution of dilated cardiomyopathy phenotype secondary to atypical hypoadrenocorticism in a dog. *J Vet Emerg Crit Care* 2023; 33: 606-612.
- 12 Hall H, Williams T, Florey J, Pascual Moreno M, Black V, Thompson D, Skelly B. Prevalence of hypercalcemia in primary hypoadrenocorticism in dogs: multicenter, retrospective study. *J Vet Intern Med* 2023; 37: 1685-1693.
- 13 Bovens C, Tennant K, Reeve J, Murphy K. Basal serum cortisol concentration as a screening test for hypoadrenocorticism in dogs. *J Vet Intern Med* 2014; 28: 1541-1545.
- 14 Lennon E, Boyle T, Hutchins R, Friedenthal A, Correa M, Bissett S, Moses L, Papich M, Birkenheuer A. Use of basal serum or plasma cortisol concentrations to rule out a diagnosis of hypoadrenocorticism in dogs: 123 cases (2000-2005). *J Am Vet Med Assoc* 2007; 231: 413-416.
- 15 Gold A, Langlois D, Refsal K. Evaluation of basal serum or plasma cortisol concentrations for the diagnosis of hypoadrenocorticism in dogs. *J Vet Intern Med* 2016; 30: 1798-1805.
- 16 Sieber-Ruckstuhl N, Reusch C, Hofer-Inteeworn N, Kuemmerle-Fraune C, Müller C, Hofmann-Lehmann R, Boretti F. Evaluation of a low-dose desoxycorticosterone pivalate treatment protocol for long-term management of dogs with primary hypoadrenocorticism. *J Vet Intern Med* 2019; 33: 1266-1271.
- 17 Jaffey J, Nurre P, Cannon A, DeClue A. Desoxycorticosterone pivalate duration of action and individualized dosing intervals in dogs with primary hypoadrenocorticism. *J Vet Intern Med* 2017; 31: 1649-1657.



## Top Five Tips for Emergency Triage

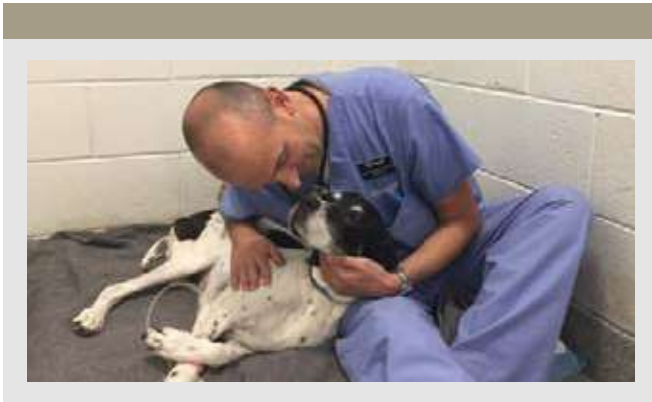
Aiden Masri, DVM  
[angell.org/emergency](http://angell.org/emergency) | [emergency@angell.org](mailto:emergency@angell.org) | 781-902-8400

### Introduction

In an emergency setting, it's not uncommon to have a list of patients waiting to be seen. A dog comes in with a bleeding torn nail, a cat is here for vomiting, and a snake is here for not eating for the past three weeks. How do you know which of these patients needs to be seen first? The triage process helps decide the order in which patients are seen. Some need to be rushed to diagnostics and initiate treatments immediately, while others are stable enough to wait and be evaluated once the more critical patients are stabilized.

The triage process involves collecting a visual assessment of each patient waiting along with their basic vital parameters (heart rate, respiratory rate and effort, and body temperature). If these values are abnormal, or a pet is not appropriately responsive during their triage, they move up to a higher priority on the list.

If you are part of the triage process, it is essential to know where to direct your focus; keeping the following five tips in mind can help the triage process run as smoothly as possible.

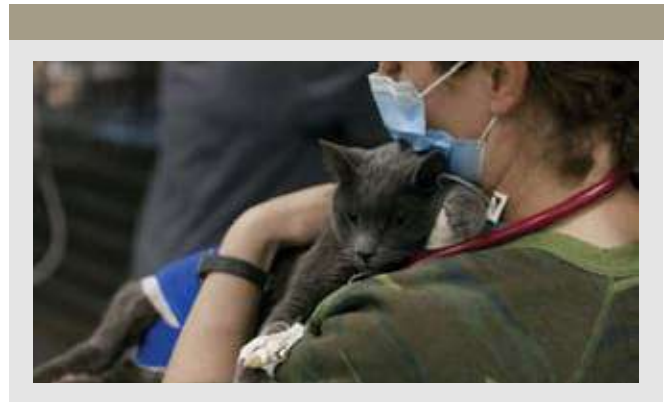

### Tip #1 – Keep Safety in Mind

In any veterinary setting, numerous work hazards exist, including the potential for infectious diseases, the handling of sharp instruments, and the presence of patients who may bite or scratch. It is important to keep your hospital's safety protocols in mind to keep yourself, other staff, owners, and all the patients under your care safe. This includes recognizing patients who may be showing signs of pain or fear-based aggression that are more likely to bite or scratch when handled and keeping in mind quarantine protocols for pets exhibiting signs of infectious diseases.

### Tip #2 – Remain Calm

While it can be easy to become overwhelmed, developing a process to remain calm and having a systematic approach during patient assessment will allow



each pet to be evaluated thoroughly and prevent mistakes associated with attempting to rush. Using a checklist during this process can also help ensure that the triage process goes as smoothly as possible and reducing stress for staff, owners, and pets.

### Tip #3 – Recognize “Red Flags”

When you are the first person evaluating a pet coming in through the ER, you play an essential role in helping to assess whether or not they are stable enough to wait or need to be seen more urgently. Knowing normal vital parameters and behavior for every species that your hospital sees through their ER is vital in the triage process. If you have concerns about a pet during their triage evaluation, don't hesitate to bring these concerns to the attention of other team members so that these patients are evaluated sooner. Regardless of species, if a pet is ever minimally responsive, having trouble breathing, actively bleeding, or uncontrollably painful, these patients should be evaluated immediately.

### Tip #4 – Build Strong Relationships

Building a sense of trust with your team is essential to having a smooth-running emergency room. This allows all team members to be more comfortable, no matter their skill or experience.

### Tip #5 – Remember Self-Care

Keep yourself in mind, too! It can be easy to forget about yourself during a busy shift, and some days can fly by so quickly that you realize you've barely had a chance for a break. It is also essential to pay attention to your own needs and ensure you have time during each shift for food, water, and a chance to take a deep breath.

# Nephrology and Urology at Angell

For patients with acute kidney injury, exposure to toxins, or immune-mediated disease

## ➤ Expanded Extracorporeal Therapies at Angell

Intermittent Hemodialysis (IHD)

Chronic Renal Replacement Therapy (CRRT) via Carpediem™

Total Plasma Exchange (TPE)

Hemoperfusion (HP)

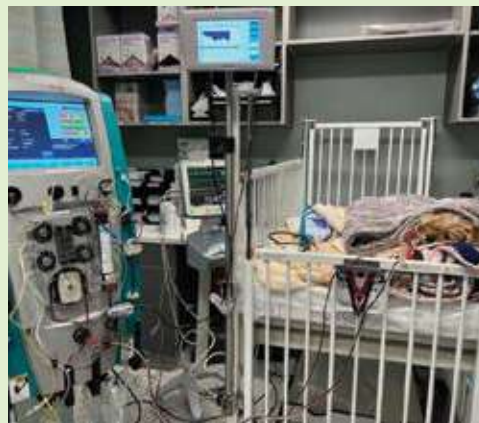Angell now offers a full range of extracorporeal therapies for patients with renal failure, immune-mediated diseases, and toxin ingestion. The **Carpediem**, a renal replacement machine, arrived at Angell in late spring 2024, improving our ability to dialyze patients under 10 kg. We continue to offer **intermittent hemodialysis** capabilities for patients greater than 10 kg and for those patients requiring **therapeutic plasma exchange**. Dialysis is most often used for renal replacement therapy to give the kidneys time to recover from infection, toxin ingestion, or ischemic insults.

According to the 2023 updated ACVIM Consensus Statement on Leptospirosis, **early dialytic intervention is recommended to prevent the morbidity of acute kidney injury rather than as a delayed salvage for failed conventional management**. Early referral to centers providing dialytic therapy should be considered for dogs in IRIS AKI Grade 4, when serum creatinine concentration exceeds 5mg/dL.

In summer 2024, Angell added **hemoperfusion (HP)** to our extracorporeal treatment offerings. HP is most commonly used to rapidly and effectively remove toxins — within hours — after accidental ingestion or overdose, including consumption of NSAIDs, chemotherapeutic agents, phenobarbital and more.

For more information, visit [angell.org/ECT](https://angell.org/ECT).

Contact Shawn Kearns, DVM, DACVIM and Courtney Peck, DVM, DACVECC at [internalmedicine@angell.org](mailto:internalmedicine@angell.org) or 617-541-5186.



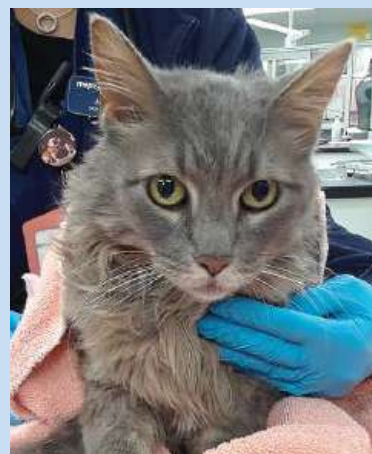## ➤ Subcutaneous Ureteral Bypass (SUB)

Ureteral obstruction is becoming increasingly more common in veterinary patients and can occur for a variety of reasons.

Arguably, the most effective technique to treat ureteral obstruction is the subcutaneous ureteral bypass (SUB) system. Developed over 10 years ago based on a subcutaneous nephrovesical bypass used in human urology, the SUB device has shown improved outcome and decreased complications in cats when compared to ureteral stents. The SUB device consists of placement of a locking loop nephrostomy catheter within the renal pelvis and a cystostomy catheter within the bladder. The two catheters are connected by a port that is placed subcutaneously.

Owner satisfaction following the SUB procedure is high (>90%). We have been implanting SUB devices at Angell Animal Medical Center since 2022 with good success. It has quickly become our preferred treatment for cats with ureteral obstruction. The SUB device can also be used in dogs for treatment of ureteral obstruction that cannot be treated with stents or traditional surgery.

[angell.org/surgery](https://angell.org/surgery) | For more information, please visit [angell.org/SUB](https://angell.org/SUB)



### Cutting-Edge Urolithiasis Solution for Pets

#### Minimally Invasive Lithotripsy

The Internal Medicine team at Angell offers lithotripsy for pets suffering from urolithiasis. Utilizing advanced technology, such as shock waves or lasers, lithotripsy targets and fragments stones within the urinary tract, allowing them to pass more easily or be extracted through minimally invasive procedures. By employing lithotripsy, Angell's Internal Medicine specialists can offer patients a quicker recovery and reduced risks associated with traditional surgical methods.

[angell.org/internal-medicine](https://angell.org/internal-medicine)

› Angell Fall 2024 Continuing Education

**Save the Dates**

**Sunday, March 23, 2025**

8:15am – 2:45pm

Live Webinar

5 CE Credits (*pending RACE approval*)

**Wednesday, April 2, 2025**

6:15pm – 8:45pm

Live Webinar

2 CE Credits (*pending RACE approval*)

PLEASE VISIT [ANGELL.ORG/CE](https://www.angell.org/ce) FOR UPDATES AND REGISTRATION.



## STAFF DOCTORS AND RESIDENTS

■ We encourage you to contact Angell's specialists with questions.

Main Phone: 617-522-7282 (Boston) | Main Phone: 781-902-8400 (Waltham) | Veterinary Referrals: 617-522-5011  
Angell at Essex: 978-304-4648

## CHIEF OF STAFF

**Ann Marie Greenleaf, DVM, DACVECC**  
agreenleaf@angell.org

24-HOUR EMERGENCY & CRITICAL  
CARE MEDICINE, BOSTON

**Alison Allukian, DVM**  
aallukian@angell.org

**Matthew Araujo, DVM**  
maraujo@angell.org

**Kiko Bracker, DVM, DACVECC**  
*Service Director*  
kbracker@angell.org

**David Carabetta, DVM, DACVECC**  
dcarabetta@angell.org

**Zachary Carlson-Sypek, DVM**  
zcarlonsypek@angell.org

**Callie Cazlan, DVM**  
ccazlan@angell.org

**Elton Chan, DVM**  
echan@angell.org

**Nicole D'Addezio, VMD**  
ndaddezio@angell.org

**Scout Ford, VMD**  
sford@angell.org

**Michael Gay, DVM**  
mgay@angell.org

**Audrey Koid, DVM, DACVECC**  
akoid@angell.org

**Brandi Lauer, DVM**  
blauer@angell.org

**Katherine McKean, DMV**  
kmckean@angell.org

**Patrick Odom, DVM**  
podom@angell.org

**William Orrico, DVM**  
worrico@angell.org

**Abbey Petronzio, DVM**  
apetronzio@angell.org

**Nathalie Suci, VMD**  
nsuci@angell.org

**Megan Steinhilber, DVM**  
msteinhilber@angell.org

**Sam Vitali, DVM**  
svitali@angell.org

**Megan Whelan, DVM, DACVECC, CVA**  
*Chief Medical Officer*  
mwhelan@angell.org

24-HOUR EMERGENCY & CRITICAL  
CARE MEDICINE, WALTHAM

**Jordana Fetto, DVM**  
jfetto@angell.org

**Ashley Lockwood, DVM, DACVECC**  
alockwood@angell.org

**Aiden Masri, DVM**  
amasri@angell.org

**Courtney Peck, DVM, DACVECC**  
*Chief Medical Officer, Waltham*  
cpeck@angell.org

**Jessica Seid, DVM**  
jseid@angell.org

**Catherine Sumner, DVM, DACVECC**  
*Chief of Staff, Waltham*  
csumner@angell.org

## ANESTHESIOLOGY

**Stephanie Krein, DVM, DACVAA**  
skrein@angell.org

**Becca Reader, BA, DVM, DACVAA**  
rreader@angell.org

**Declan Ryan, DVM**  
dryan@angell.org

**Kelly Sullivan, PhD, DVM, DACVAA**  
ksullivan@angell.org

## AVIAN &amp; EXOTIC MEDICINE (W/B)

**Elena Buenrostro, DVM**  
ebuenrostro@angell.org

**Lauren Gawel, DVM**  
(Waltham)  
lgawel@angell.org

**Brendan Noonan, DVM, DABVP**  
(Avian Practice)  
bnoonan@angell.org

**Anne Staudenmaier, VMD, DABVP**  
(Avian Practice)  
(Waltham)  
astaudenmaier@angell.org

**Patrick Sullivan, DVM, DABVP**  
(Avian Practice)  
psullivan@angell.org

## BEHAVIOR (W/B)

**Terri Bright, PhD, BCBA-D, CAAB**  
tbright@angell.org

**Allyson Salzer, PhD, BCBA-D, CAAB**  
asalzer@angell.org

## CARDIOLOGY

**Alice Chirn, MA, BVetMed**  
achirn@angell.org

**Katie Hogan, DVM, DACVIM (Cardiology)**  
(Boston and Waltham)  
khogan@angell.org

**Terry Huh, DVM, DACVIM (Cardiology)**  
thuh@angell.org

**Clint Lynn, DVM**  
clynn@angell.org

**Sarah Rogg, DVM**  
srogg@angell.org

## DENTISTRY

**Shawna Han, DVM**  
shan@angell.org

**Jessica Riehl, DVM, DAVDC**  
jriehl@angell.org

**Joyce Tai, DVM, DAVDC**  
jtai@angell.org

## DERMATOLOGY (W/B)

**Klaus Loft, DVM**  
kloft@angell.org

**Meagan Painter, DVM, DACVD**  
(Waltham)  
mpainter@angell.org

**Brooke Simon, DVM**  
bsimon@angell.org

## DIAGNOSTIC IMAGING (W/B)

**Naomi Ford, DVM, DACVR**  
nford@angell.org

**Alex Quilty, DVM, DACVR**  
aquilty@angell.org

**Steven Tsai, DVM, DACVR**  
stsai@angell.org

**Ruth Van Hatten, DVM, DACVR**  
rvanhatten@angell.org

## INTERNAL MEDICINE (W/B)

**Nyla Bent, DVM**  
nbent@angell.org

**Douglas Brum, DVM**  
dbrum@angell.org

**Maureen Carroll, DVM, DACVIM**  
mccarroll@angell.org

**Anita Fothergill, VMD**  
afothergill@angell.org

**Lisa Gorman, DVM, DACVIM**  
(Waltham)  
lgorman@angell.org

**Jessica Hayes, DVM**  
jhayes@angell.org

**Antonia Ioannou, BVMS, DACVIM**  
aioannou@angell.org

**Shawn Kearns, DVM, DACVIM**  
skearns@angell.org

**Evan Mariotti, DVM, DACVIM**  
emariotti@angell.org

**Susan O'Bell, DVM, MPH, DACVIM**  
(Internal Medicine)  
*Service Director*  
sobell@angell.org

**Juliana Picard, DVM**  
jpicaard@angell.org

**Ursula Ramalho, DVM**  
uramalho@angell.org

## STAFF DOCTORS AND RESIDENTS

CONTINUED FROM PAGE 18

**Annie Sheu-Lee, DVM, DACVIM**  
 asheulee@angell.org

**Lorena Sistig, DVM**  
 lsistig@angell.org

**Lindsey Summers, DVM**  
 lsummers@angell.org

**Daniela Vrabelova Ackley  
 DVM, MS, DACVIM**  
 (Waltham)  
 dvrabelova@angell.org

## NEUROLOGY

**Rob Daniel, DVM, DACVIM**  
 (Neurology)  
 rdaniel@angell.org

**Michele James, DVM, DACVIM**  
 (Neurology)  
*Service Director*  
 mjames@angell.org

**Jennifer Michaels, DVM, DACVIM**  
 (Neurology)  
 jmichaels@angell.org

## ONCOLOGY

**Kristine Burgess, DVM, MLA, DACVIM**  
 (Medical Oncology)  
 kburgess@angell.org

**Megan Cray, VMD, DACVS**  
 (Surgical Oncology)  
 mcray@angell.org

**Kendra Lyons, DVM (Medical Oncology)**  
 klyons@angell.org

**Gretchen McLinden, DVM, DACVIM**  
 (Medical Oncology)  
 gmclinden@angell.org

**Jillian Walz, DVM, DACVIM**  
 (Medical Oncology), DACVR  
 (Radiation Oncology)  
 jwalz@angell.org

## OPHTHALMOLOGY

**Daniel Biros, DVM, DACVO**  
 dbiros@angell.org

**Martin Coster, DVM, MS, DACVO**  
 mcoster@angell.org

PATHOLOGY  
(CLINICAL & ANATOMIC)\*

**Patty Ewing, DVM, MS, DACVP**  
 pewing@angell.org

**Pamela Mouser, DVM, MS, DACVP**  
 pmouser@angell.org

## SURGERY (W/B)

**Kristen Behrens, DVM**  
 kbehrens@angell.org

**Sue Casale, DVM, DACVS**  
 scasale@angell.org

**Dilraj Goraya, DVM**  
 dgoraya@angell.org

**Kathryn Heidgerd, VMD**  
 kheidgerd@angell.org

**Michael Pavletic, DVM, DACVS**  
*Service Director*  
 mpavletic@angell.org

**Jennifer Peterson-Levitt  
 DVM, DACVS-SA**  
 (Boston & Waltham)  
 jpetersonlevitt@angell.org

**Sophia Topulos, DVM**  
 (Waltham)  
 stopulos@angell.org

**Nicholas Trout  
 MA, VET MB, DACVS, ECVS**  
 ntrout@angell.org

## URGENT CARE

BY APPOINTMENT ONLY, WALTHAM

**Tamara Kremer Mecabell, DVM**  
 tmecabell@angell.org

**Natasha Pakravan, DVM**  
 npakravan@angell.org

**Julie Shields, DVM**  
 jshields@angell.org

## ANGELL AT ESSEX

**Heidi Broadley, DVM**  
 hbroadley@angell.org

**Sara Gardiner, DVM**  
 sgardiner@angell.org

(W/B) Services available at both our Waltham and Boston locations

\*Boston-based pathologists and radiologists serve both Boston and Waltham locations

\*\*Available only in Waltham



## › Courtesy Shuttle for Patients Needing Further Specialized Care

Angell Animal Medical Center offers the convenience of our MSPCA-Angell West facility in Waltham, MA. The Waltham facility offers Urgent Care and specialized service appointments. If needed, an oxygen-equipped courtesy shuttle can transport animals to Boston for further specialized care and then return them to Waltham. Whether in Boston or in Waltham, our specialists regularly collaborate and plan treatments tailored to our patients' emergency, surgical, and specialty needs.

WE OFFER A BROAD RANGE OF EXPERTISE AND DELIVER THIS CARE WITH  
 THE ONE-ON-ONE COMPASSION THAT OUR CLIENTS AND PATIENTS DESERVE.

MSPCA-ANGELL  
350 South Huntington Avenue  
Boston, MA 02130  
617-522-5011  
[angell.org](http://angell.org)

MSPCA-ANGELL WEST  
293 Second Avenue  
Waltham, MA 02451  
781-902-8400  
[angell.org/waltham](http://angell.org/waltham)

ANGELL AT ESSEX  
565 Maple Street  
Danvers, MA 01923  
978-304-4648  
[angell.org/essex](http://angell.org/essex)

MSPCA-ANGELL CLINICS  
Boston | Cape Cod | Methuen  
[angell.org/clinics](http://angell.org/clinics)

Please consider adding Angell's Emergency service/617-522-7282 to your after-hours phone message.

## ▸ Our Service Locations

### BOSTON & WALTHAM

**Avian & Exotic Medicine**  
617-989-1561

**Behavior**  
617-989-1520

**Cardiology**  
617-541-5038

**Dermatology**  
617-524-5733

**Diagnostic Imaging**  
617-541-5139

**Internal Medicine**  
B: 617-541-5186  
W: 781-902-8400

**Surgery**  
617-541-5048

**Urgent Care\***  
781-902-8400

### BOSTON ONLY

**Anesthesiology**  
617-541-5048

**Dentistry**  
617-522-7282

**Neurology**  
617-541-5140

**Oncology**  
617-541-5136

**Ophthalmology**  
617-541-5095

**Pathology**  
617-541-5014

\*Available only in Waltham

