

## Behavior Service Now Available at Angell



Terri Bright  
Ph.D., BCBA-D

angell.org/behavior  
behavior@angell.org  
617-989-1520

We are pleased to announce that Terri Bright, Ph.D., BCBA-D, is now seeing Behavior appointments on Wednesday and Thursday afternoons at Angell (4pm–6:30pm). Dr. Bright earned her Master of Science degree and Ph.D. from Simmons College in Applied Behavior Analysis (ABA) with an animal specialty, and she is a Board-Certified Behavior Analyst (BCBA-D). She is a mentor for future BCBAs, and is an adjunct professor in the Behavior Analysis Department at Simmons College. Her dissertation research entailed developing a dog behavior assessment and analysis tool that will help standardize how dog trainers evaluate why problem behaviors happen.

Dr. Bright has been training dogs as a hobby and professionally for many years, and her research on stimulus equivalence (matching-to-sample training) earned her a Marian Breland Bailey (MBB) Award from the Association of Applied Behavior Analysis International (ABAI). Dr. Bright won another MBB Award from ABAI for her research on the use of errorless teaching to train a shelter dog to sit at the sound of a bell (“Pavlov’s Shelter”) when she was not in the dog’s sight. She uses evidence-based methods of training.

Dr. Bright launched the training department at the MSPCA-Boston location in 2007, and has grown the program to over 30 classes a week. She helps evaluate homeless dogs surrendered at the MSPCA for proper placement, and designs training and enrichment programs for dogs at the MSPCA.

She also designs and implements curriculum and teaching for staff and volunteers in the SAFEWALK program, which she created in 2009, and lectures locally and nationally on behavior analysis.

Dr. Bright offers behavior consultations for cats and dogs with positive-based behavior modification treatment plans for such issues as:

- Aggression towards people and other animals
- Separation anxiety
- Noise phobias
- House soiling and marking
- Generalized anxiety
- Situational anxiety (car rides, slippery floors, vet visits)
- New baby acclimations
- Furniture scratching
- Excessive vocalization
- Cognitive dysfunction
- Compulsive behavior

To refer a case to Dr. Bright, please call **617-989-1520** or visit [angell.org/behavior](http://angell.org/behavior) for more information.

## MSPCA-Angell West Opens February 3!

Angell Animal Medical Center is proud to open our convenient new location at 293 Second Avenue, Waltham, MA 02451.

### Hospital services include:

- 🐾 24/7 Emergency & Critical Care
- 🐾 Avian & Exotic Medicine
- 🐾 Cardiology
- 🐾 Internal Medicine
- 🐾 Surgery

With both familiar and new faces, our new location features board-certified specialists and criticalists working in close collaboration with our Angell-Boston team to provide a spectrum of services for your clients and patients. Come visit our new facility!

Please call **781-902-8400** to book appointments or referrals, or visit [angell.org](http://angell.org) for a full list of expanding Waltham services.

### Inside

Biceps Tenosynovitis: Diagnosis and Treatment	2
Sildenafil	4
Canine Demodex	5
Notes from Angell’s Clinical/Anatomical Pathology Service	7
Nuclear Medicine at Angell Making a Comeback!	8

### Courtesy Consultations

Angell specialists are available for consultation Monday–Friday, 9:00am–5:00pm.

Additionally, Angell emergency doctors are available for consultation on weekends and after hours (7:00am–11:00pm).

### Referral Contact Information

Please see page 12 and the back cover of this newsletter for full contact information.

### Online Referral Forms

Please visit [angell.org/referrals](http://angell.org/referrals)

### Upcoming CE Schedule

Please see page 6.

Available at [angell.org/CE](http://angell.org/CE)

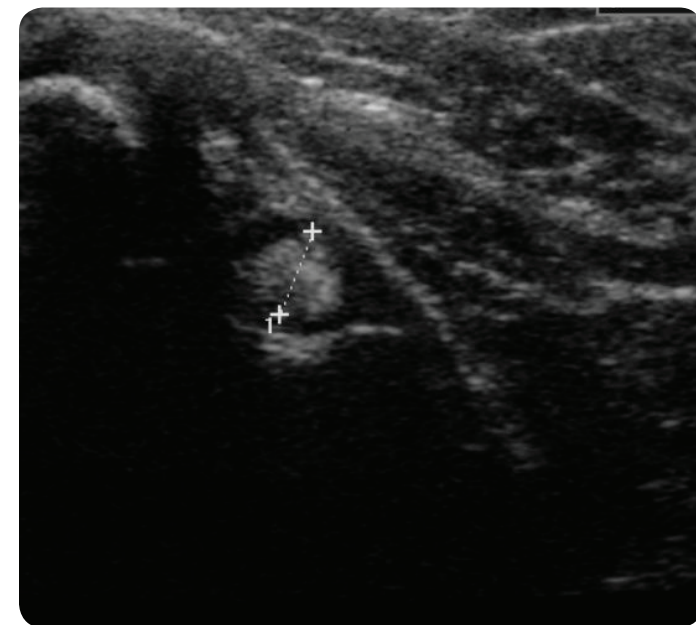
# Biceps Tenosynovitis: Diagnosis and Treatment



By Sue Casale  
DVM, DACVS

[angell.org/surgery](http://angell.org/surgery)  
[surgery@angell.org](mailto:surgery@angell.org)  
617-541-5048

Forelimb lameness is one of the most frustrating conditions to diagnose and treat. Often dogs will have mild and intermittent lameness with little to no reaction on orthopedic examination. Numerous conditions exist that result in forelimb lameness, so oftentimes many diagnostics are needed to determine the cause, and despite multiple diagnostics, a cause may not be immediately found. This results in frustration for both the owner and the veterinarian. In addition, pathology in multiple joints is common, and determining the culprit of the lameness may be difficult. Studies have shown that shoulder pathology is more likely to cause lameness than elbow pathology.<sup>1</sup> History may lend some clues to the origin of the lameness. Lameness from shoulder pathology tends to be weight-bearing and consistent with an insidious onset, while elbow lameness is more acute and episodic.



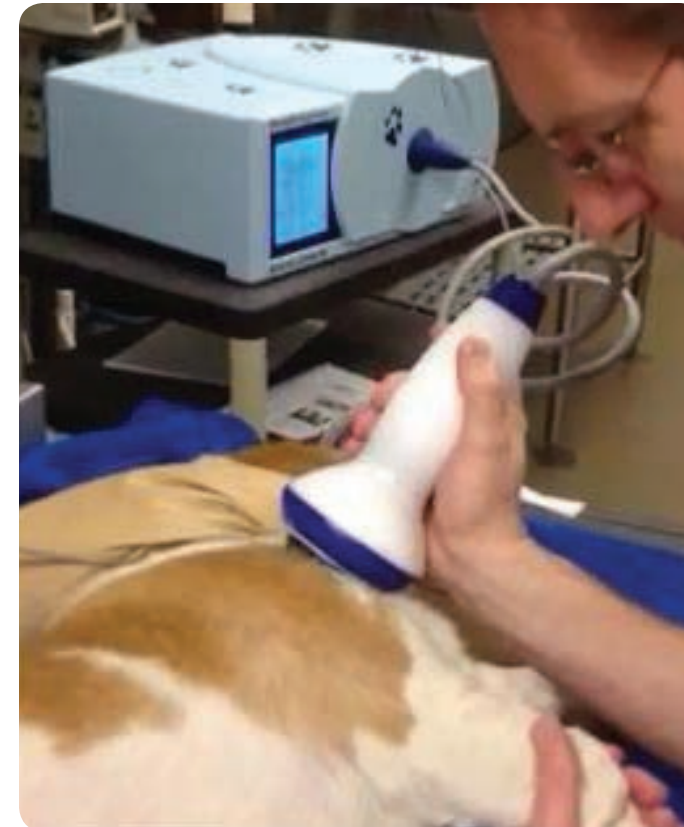
↳ Ultrasound image of biceps tendon.

One common cause of shoulder lameness is biceps tenosynovitis. This condition is often seen in middle-age to older, medium- to large-breed dogs, with the Labrador Retriever and Rottweiler the most frequent breeds affected. The biceps brachii muscle originates on the supraglenoid tubercle of the scapula and inserts on the radius and ulna. The biceps tendon crosses the joint and is both a dynamic and static stabilizer of the shoulder joint.<sup>2</sup> Strain injury to the tendon from overuse or trauma, both direct and indirect, can result in inflammation of the tendon and surrounding sheath. Pain is often elicited on direct biceps tendon palpation while the shoulder is flexed and the elbow extended, although general shoulder pain may also elicit a response.<sup>3</sup> Shoulder radiographs are necessary to rule out other pathology and may show mineralization within the biceps groove; however, normal radiographs do not rule out biceps tenosynovitis.<sup>1,4</sup> Contrast arthrography is generally low-yield but may show a filling defect in the biceps groove if fibrous adhesions are present. Ultrasound is the modality of choice to diagnose biceps disease.<sup>5</sup> Other soft tissue structures can be examined, and the contralateral biceps tendon can be used for comparison. Ultrasound of the biceps tendon when tenosynovitis is present may reveal an enlarged, hypoechoic tendon with fiber pattern disruption. A lucent line around the tendon indicating fluid within the sheath may be seen, and an irregularity to the bicipital groove from osteophytes is seen in chronic cases.

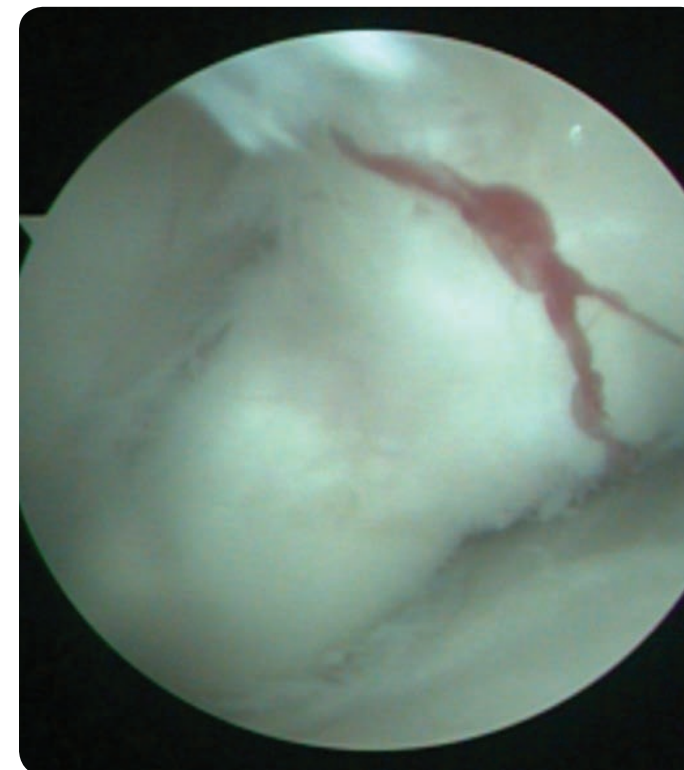
Treatment of biceps tenosynovitis starts with 6 weeks of strict rest and nonsteroidal anti-inflammatory medication. The joint/tendon sheath can be injected with a steroid such as Depo-Medrol. Direct injection into the tendon is not recommended, as it may predispose patients to tendon rupture.<sup>6</sup> Medical management can be successful in more than 50% of cases, but return to normal activity too early can disrupt the healing, slow the recovery, and cause chronic lameness.<sup>3,7</sup> If there is no improvement after medical management, or if the lameness returns, surgical treatment may be required. Extracorporeal shockwave therapy (ESWT) is a new modality to treat tendon injuries. With ESWT, high-energy acoustic pressure waves are delivered to the tendon. Although the mechanism of action is not completely understood, several hypotheses exist to explain its healing mechanism.<sup>8</sup> Neoangiogenesis, modulation of nitric oxide, suppression of NF-kappaB, and increased expression of TGF-beta1 and IGF-1 are all thought to play a role. ESWT decreases inflammation and speeds the healing process through increased release of angiogenic growth factors, disintegration of calcifications within the tendon, and increased tensile strength within the tendon by improving fiber alignment.<sup>9</sup> ESWT is also thought to recruit stem cells to aid in repair and increases the cellular release of bone morphogenetic protein. Sedation is required for treatment with ESWT because of mild discomfort during the procedure; the general recommendation is 3 treatments, 3 weeks apart. Up to 85% of dogs will show improvement with ESWT. If improvement is incomplete or

> Continued on next page

## > Biceps Tenosynovitis: Diagnosis and Treatment (Continued from page 2)



↳ Extracorporeal Shockwave Therapy (ESWT).



↳ Arthroscopic view of biceps tendon.

temporary, surgery can be considered. Surgical transection of the tendon eliminates the repetitive trauma from the tendon stretching across the shoulder joint. The transected end of the tendon can be surgically attached to the proximal humerus with a bone screw (biceps tenodesis) or can be left to form adhesions to the humerus over time (natural tenodesis). Arthroscopy allows direct visualization of the tendon and its origin, and allows transection of the tendon with minimal tissue trauma. Arthroscopic tenotomy has proven to be successful for most dogs, with many experiencing immediate pain relief.<sup>10,11</sup> Mean time to full recovery is 3 weeks.

Although biceps tenosynovitis can be frustrating to diagnose, ultrasound is an effective modality for diagnosing shoulder lameness from biceps disease. Tenosynovitis has a high response rate to medical management and ESWT; however, for patients that do not respond with good to excellent results, surgery is an option for most dogs.



[angell.org/surgery](http://angell.org/surgery)

To contact Angell's surgeons by phone or to refer a patient to the Angell Surgery service, please call 617-541-5048 or email [surgery@angell.org](mailto:surgery@angell.org). You can also reach Dr. Casale at [scasale@angell.org](mailto:scasale@angell.org).

### References:

1. Cogar DM, Cook CR, Curry SL, et al. Prospective evaluation of techniques for differentiating shoulder pathology as a source of forelimb lameness in medium and large breed dogs. *Vet Surg* 2008;37:132-141.
2. Sidaway BK, McLaughlin RM, Elder SH, et al. Role of the tendons of the biceps brachii and infraspinatus muscles and the medial genohumeral ligament in the maintenance of passive shoulder joint stability in dogs. *Am J Vet Res* 2004;65:1216-1222.
3. Stobie D, Wallace LJ, et al. Chronic bicipital tenosynovitis in dogs: 29 cases (1985-1992). *J Am Vet Med Assoc* 1995;207:201-207.
4. Akerblom S, and Sjoström L. Evaluation of clinical, radiographical and cytologic findings compared to arthroscopic findings in shoulder lameness in the dog. *Vet Comp Orthop Traumatol* 2007;20:136-141.
5. Kramer M, Gerwing M, Sheppard C, and Schimke E. Ultrasonography for the diagnosis of diseases of the tendon and tendon sheath of the biceps brachii muscle. *Vet Surg* 2001;30:64-71.
6. Halpern AA, Horowitz BG, and Nagel DA. Tendon ruptures associated with corticosteroid therapy. *West J Med* 1977;127:378-382.
7. Bruce WJ, Burbidge HM, and Broome CJ. Bicipital tendinitis and tenosynovitis in the dog: A study of 15 cases. *N Z Vet J* 2000;48:44-52.
8. Shrivastava SK, and Kailash. Shock wave treatment in medicine. *J Biosci* 2005;30:269-275.
9. Farr S, Sevelida F, et al. Extracorporeal shockwave therapy in calcifying tendinitis of the shoulder. *Knee Surg Sports Traumatol Arthrosc* 2011;19:2085-2089.
10. Wall CR, and Taylor R. Arthroscopic biceps brachii tenotomy as a treatment for canine bicipital tenosynovitis. *J An Anim Hosp Assoc* 2002;38:169-175.
11. Bergenhuyzen ALR, Vermote KAG, van Bree H, and Van Ryssen B. Long-term follow-up after arthroscopic tenotomy for partial rupture of the biceps brachii tendon. *Vet Comp Ortho Traumatol* 2010;23:51-55.

## Sildenafil



By Rebecca Quinn  
DVM, DACVIM  
(Internal Medicine and Cardiology)

[angell.org/cardiology](http://angell.org/cardiology)  
[cardiology@angell.org](mailto:cardiology@angell.org)  
617-541-5038

Sildenafil citrate was developed with the intention of treating people with angina (chest pain due to ischemic heart disease). Interestingly, researchers discovered that sildenafil did very little to improve this condition, but did result in an unexpected side effect. Sildenafil underwent clinical trials, and in 1998 became the first FDA-approved drug in the United States for treatment of erectile dysfunction. We are all familiar with the brand-name drug Viagra®, but sildenafil citrate is also marketed as Revatio®. Sildenafil citrate under the brand name Revatio® is used for treatment of human pulmonary hypertension.

In veterinary medicine, pulmonary hypertension (PH) is rarely a primary disease. Instead, PH occurs secondary to such conditions as advanced chronic degenerative valvular disease, dilated cardiomyopathy, heartworm disease, pulmonary diseases (pneumonia, collapsing trachea, asthma, bronchitis, neoplasia), and pulmonary thromboembolism. Pulmonary hypertension is being diagnosed more and more frequently in our canine and feline patients, and veterinary patients with PH often show clinical signs such as difficulty breathing, coughing, exercise intolerance, and collapse. The most common physical exam findings are pulmonary crackles, dyspnea, and split-second heart sounds. Patients may have ascites or pleural effusion. Thoracic radiographs and echocardiogram are considered the most accurate non-invasive diagnostic tools for PH. Because PH occurs secondary to other health problems, additional diagnostics, such as a CBC test, a chemistry panel, infectious disease testing, urinalysis, and endocrine testing are essential to understanding the complete clinical picture.

When PH is diagnosed, the ultimate goal is to identify and treat the underlying condition. However, in many cases, the underlying condition is so advanced that symptoms of PH persist despite appropriate primary therapy. Rarely, the cause of PH cannot be identified. In patients that continue to demonstrate clinical symptoms of PH despite appropriate treatment of their underlying illnesses, sildenafil citrate therapy is a potential therapeutic option.

Sildenafil is not approved for use in canine or feline patients but has been used off-label in experimental and clinical settings, with good responses to therapy. A possible scenario for sildenafil

therapy is an older dachshund with advanced mitral valve disease and associated congestive heart failure. If the patient is treated appropriately with furosemide, pimobendan, and enalapril, and radiographs show resolution of congestive heart failure but the patient continues to demonstrate labored breathing, an echocardiogram can assess for PH. If moderate to severe PH is confirmed, sildenafil can be used at a dose range of 1–3 mg/kg by mouth two to three times daily. Clinical improvement is often noted within 48 to 72 hours.

Sildenafil has very few reported side effects, but these can include lethargy, weakness, or gastrointestinal symptoms. The biggest “side effect” of sildenafil is usually the monthly cost to the client. In the case example mentioned above, the patient’s monthly sildenafil prescription would cost \$200-\$500 depending on the required dose.

Prior to the introduction of sildenafil to the veterinary community, patients with PH had grave prognoses. Patients often died or were euthanized due to progressive and intractable respiratory symptoms. While sildenafil therapy may not be the right choice for every patient and client, there are circumstances in which sildenafil therapy can improve the quality and quantity of our patients’ lives.

With appropriate treatment of the primary condition and the addition of sildenafil therapy, PH patients may live several weeks, months, or even years longer than they would otherwise.



[angell.org/cardiology](http://angell.org/cardiology)

If you have a patient who you suspect may benefit from sildenafil therapy, please contact the Angell Cardiology Service to discuss individual considerations for your patient and any other questions you may have. You may contact Dr. Rebecca Quinn at [rquinn@angell.org](mailto:rquinn@angell.org), email [cardiology@angell.org](mailto:cardiology@angell.org), or call the Cardiology Service at 617-541-5038. ■

## Canine Demodex



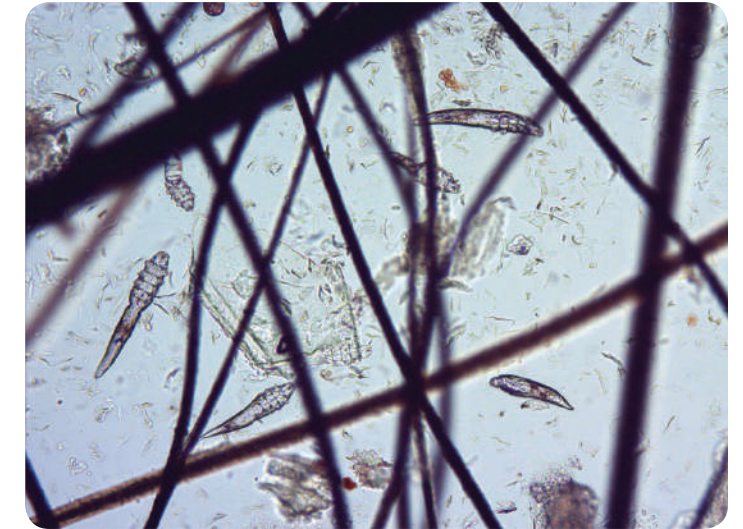
By Meghan Umstead  
DVM

[angell.org/dermatology](http://angell.org/dermatology)  
[dermatology@angell.org](mailto:dermatology@angell.org)  
617-524-5733

Canine demodex is considered a normal resident of canine skin, and transmission occurs between mom and her puppy in the first several days of life. Demodex canis is the most common demodex mite identified, and with increased numbers in the skin, these mites cause an inflammatory skin disease. They live in the hair follicle; therefore, clinical signs noted in patients include lesions surrounding the hair follicle. These clinical signs range from alopecia, erythema, papules, pustules, scales, comedones, follicular casts, folliculitis, and, in more severe cases, nodules and furunculosis. Skin lesions can occur in any location of the skin that has hair follicles, but most commonly the lesions begin on the face and forelimbs. There is often a secondary bacterial skin infection associated with the disease.

The best diagnostic method is a deep skin scrape using a spatula or dull scalpel blade submerged in mineral oil. The skin should be squeezed between scrapings to encourage the mites out of the hair follicle. Trichograms are best utilized in areas where a deep skin scrape is difficult to perform, such as around the eyes. The hairs that are plucked for a trichogram or the material from a deep skin scrape are placed in a drop of mineral oil on a microscope slide, and a coverslip placed over the mineral oil will provide a guide when reading the deep skin scrape under the microscope. Multiple sites should be scraped in order to determine if the patient has generalized or localized demodicosis. These four mite stages can be seen on the deep skin scrape: eggs, 6-legged larvae, 8-legged nymph, and 8-legged adult. When examining the deep skin scrape, the mite stage and count should be noted, as this will help determine therapeutic success or failure on subsequent deep skin scrapes. In rare situations, detecting mites may require a skin biopsy.

Canine demodicosis is categorized as either juvenile onset or adult onset and either generalized or localized. Juvenile onset occurs in puppies between 3 and 18 months of age, and “true” adult onset occurs in adults that have no previous skin issues. It is sometimes difficult to determine adult vs. juvenile onset because some puppies go undiagnosed until they are adults. Disease states that compromise the immune system should be addressed and may include poor nutrition and endoparasites in



juveniles, and Cushing’s disease and hypothyroidism in adults. Localized demodicosis will have a small focal or several small multifocal areas that often spontaneously resolve. Generalized demodicosis is multifocal and covers a larger body area than localized demodicosis. Mueller et al. suggests that localized demodicosis includes ≤ 4 lesions that are ≤ 2.5 cm in diameter (*Vet Derm* 2012), but there is no clear definition between these two types.

Localized demodicosis will often spontaneously resolve in 6 to 8 weeks, and these patients should be monitored but not systemically treated. Systemic treatment of localized demodicosis will mask patients that develop generalized disease, thus potentially keeping them in the breeding pool, and there is no data suggesting that systemic therapy will heal localized demodicosis any faster. Topical therapy may be utilized if the owner insists on some form of treatment.

Generalized canine demodicosis is more common in purebred dogs and in certain breeds of dog. The disease has a hereditary basis, and it is recommended that any dog with generalized demodicosis should not be allowed to breed. Spaying females will be especially important because the estrus cycle can trigger a recurrence. Therapy includes treating any secondary bacterial skin infection with an oral antibiotic and benzoyl peroxide–based shampoo. Amitraz (Mitaban®) is the only approved method of therapy in the USA. Ivermectin, when given orally, tends to be the standard therapy utilized today. Dogs will clinically cure before negative deep skin scrapes are found, so it is important to repeat these scrapes every few weeks until there are 2 or 3 negative skin scrapes. The deep skin scrapes should be performed in the same locations where they were

> Continued on next page

initially taken, and mite stages and numbers again counted. As treatment progresses, there should be fewer mite numbers, and the younger mite stages should not be seen if the patient is responding to therapy appropriately. Dogs are considered cured if they have negative deep skin scrapes 12 months from the time treatment was stopped.



To contact Angell's Dermatology Service, please call 617-524-5733 or email [dermatology@angell.org](mailto:dermatology@angell.org). You can also reach Dr. Umstead at [mumstead@angell.org](mailto:mumstead@angell.org). ■

[angell.org/dermatology](http://angell.org/dermatology)

## LIKE ANGELL ON FACEBOOK!



Find out the latest CE Schedule and gain access to clinical articles by Angell's specialists with content prepared just for our referring partners.

[Facebook.com/AngellReferringVeterinarians](https://www.facebook.com/AngellReferringVeterinarians)

References:

1. Miller, W.H., Griffin, C.E., Campbell, K.L. *Small Animal Dermatology*, 7th edition. Elsevier, Missouri, 2013, p. 304-313.
2. Mueller, R.S., et al. Treatment of demodicosis in dogs: 2011 clinical practice guidelines. *Veterinary Dermatology* 2012, 23, 86-e21, 86-94.
3. Scott, D.W., Miller, W.H., Griffin, C.E. *Small Animal Dermatology*, 6th edition. Saunders, Pennsylvania, 2001, p. 457-474.

## Angell CE Seminar — Save the Date!

Please visit [angell.org/ce](http://angell.org/ce) to register, or call 617-522-5011 for more information.

### Soothing the Itch: New Therapies and Strategies to Treat Atopic Dermatitis in Dogs

Complimentary Dinner & Lecture for Veterinarians & Technicians

Wednesday, April 2, 2014

6:00pm – 8:45pm

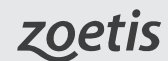2 CE Credits (pending R.A.C.E. approval)

Register by March 20, 2014, at [angell.org/ce](http://angell.org/ce).

Registration:

Please visit [angell.org/ce](http://angell.org/ce) to register.

Thanks to Our Sponsor:



Speaker:

Klaus Loft, DVM  
Angell's Dermatology Service

CE Location:

Hilton-Dedham, 25 Allied Drive, Dedham, MA 02451

Agenda:

Registration, Drinks, and Conversation, 6:00pm – 6:15pm

Dinner Served, 6:15pm

Part 1: Background on New Therapies for Atopic Dermatitis in Dogs, 6:25pm – 7:25pm

- Revisiting old treatments with new twists (shampoos, sprays, wipes, EFA, and spot-on products)

Break, 7:25pm – 7:35pm

Part 2: New Strategies in the Treatment of the Allergic Dog, 7:35pm – 8:35pm

- Skin barrier function improvement
- Using the barrier function of the skin to help in the prevention of skin infections
- Using barrier function for long-term reduction of the risk of allergic burden through the skin

Q & A, 8:35pm – 8:45pm

## Notes from Angell's Clinical/ Anatomical Pathology Service



By Patty Ewing  
DVM, MS, DACVP  
(Anatomical and Clinical Pathology)

[angell.org/lab](http://angell.org/lab)  
[pathology@angell.org](mailto:pathology@angell.org)  
617-541-5014

Our in-house laboratory gives Angell specialists unique access to expertise and significantly faster turnaround times, which can eliminate unnecessary testing. Below, pathologist Dr. Patty Ewing provides useful notes from the lab.

### What is the difference between HCT (hematocrit) and PCV (packed cell volume), and which is better for clinical use?

If you are assessing HCT/PCV over time in a hospitalized patient, the best option is consistency—use the same method. I would select spun HCT/PCV (centrifugation method) because it is directly measured rather than calculated. I would be sure that the conditions which can artifactually decrease or increase spun HCT/PCV (excess EDTA, premature termination of centrifugation, clots in the sample, *in vitro* hemolysis, and inadequate mixing of blood) are avoided.

### Detailed Explanation:

HCT/PCV is the percent of blood volume filled by erythrocytes and, thus, a measure of the oxygen-carrying capacity of the blood. If there are 100 ml of blood with a HCT of 45%, the erythrocytes occupy 45 ml. You have to carefully consider terminology and methods to answer the question above. Spun HCT and spun PCV are different names for the same thing (both are derived by the same method—determined by centrifugation of anticoagulated whole blood). Calculated HCT is determined by automated hematology instruments (impedance cell counters). It calculates HCT using the following formula:  $MCV \times RBC \text{ count} / 10$ . Because it is a calculated value, HCT depends on MCV (mean corpuscular volume) and the RBC count being measured accurately by the instrument with no complicating factors.

For example, agglutination can falsely decrease calculated HCT but will have no effect on spun PCV/HCT. Excess EDTA (too little blood volume for the size of EDTA tube used) shrinks RBCs and can result in a falsely decreased spun PCV/HCT. Inadequate centrifugation of blood (such as occurs when someone gets in a hurry and stops the centrifuge prematurely) can result in a falsely increased spun PCV/HCT, but it will not be an issue for calculated HCT because

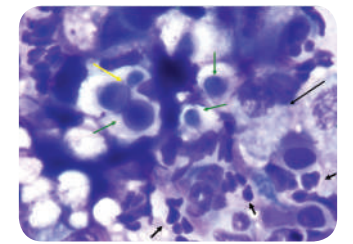
the blood is not centrifuged prior to analysis. And, to complicate matters further, our NOVA instrument is also capable of generating an HCT, and it does so using an entirely different method (electrical conductivity, frequently referred to as conductivity HCT). It is the least accurate of the methods, and for this reason, I don't recommend using the NOVA HCT for clinical use.

### How does Angell's in-house testing positively impact patient care?

Angell has had an in-house clinical laboratory for several decades. In September 2013, Angell Lab went live with in-house cortisol testing 7 days a week. Since then, the fast turnaround time due to in-house testing has positively impacted patient care. Within the first month of expanded testing, 3 cases highly suspicious for Addison's presented on emergency and were managed by Angell's Internal Medicine Service. These cases presented over the weekend, including a holiday weekend, when results normally would have been delayed by 1 to 2 days. With the in-house testing, these cases were diagnosed in less than 24 hours and started on treatment in a more timely manner. The faster turnaround time also allowed us to hold off on other diagnostics, such as ultrasound, that we may have done sooner in an azotemic patient while awaiting results.

### Ferret with Nasal Cryptococcus

I identified these *Cryptococcus* sp. yeast in nasal discharge from a ferret. Green arrows identify the purple spherical yeast surrounded by a thick clear capsule. The yellow arrow shows narrow-based budding characteristic of this fungus. Short black arrows show neutrophils, and long black arrows show macrophages in the pyogranulomatous inflammatory response typically associated with fungal infections. Cryptococcosis is more commonly seen in cats, but can be observed in ferrets. Avian (especially pigeon) droppings and contaminated soil are the main sources of infection. The ferret responded well to antifungal therapy.



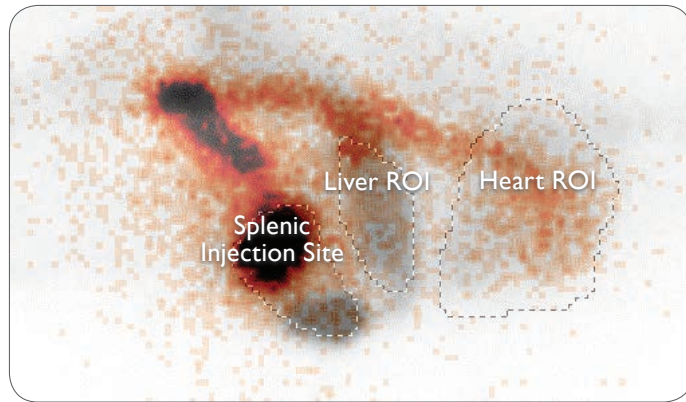
➤ Ferret with nasal cryptococcus.



For more information or to contact Angell's Pathology Service, please call 617-541-5014 or email [pathology@angell.org](mailto:pathology@angell.org). ■

[angell.org/lab](http://angell.org/lab)





↘ A summed image from the University of Tennessee of the dynamic study acquired immediately following injection of TcO4-99m-Mebro into the spleen of an Irish Wolfhound that had a left-divisional intrahepatic shunt (a.k.a. patent ductus venosus). The patient's head is toward the right. The splenic injection site is the large black spot, and the bolus travels caudodorsally, then cranioventrally, entering the heart at a 45-degree angle, signifying a portocaval shunt.

a dynamic study is acquired. We are able to watch the radiopharmaceutical bolus travel from the spleen, through the splenic vein, into the caudal vena cava, or azygous vein, and bypass the liver, terminating in the heart.

Portosystemic shunts are either intrahepatic or extrahepatic. Small-breed dogs, such as Yorkshire Terriers, tend to have extrahepatic shunts, and large-breed dogs, such as Irish Wolfhounds, tend to have intrahepatic shunts. A typical extrahepatic shunt will divert the blood from the portal

system past the liver, often from the portal vein or splenic vein, directly into the caudal vena cava. The patient's liver does not have a chance to filter the blood absorbing all the GI nutrients, and the toxins are able to flow freely to the heart and subsequently to the brain, producing the neurologic physical exam findings we expect.

Multiple acquired shunts develop with chronic portal hypertension, which can occur secondary to a dysfunctional liver. These typically form a nest of tortuous vessels within the mid-caudal abdomen, often caudal to the left kidney, and these changes are also clearly identified using TSPS.



angell.org/diagnosticimaging

Hopefully this brief overview of veterinary nuclear medicine piqued your interest. Feel free to contact the Angell Diagnostic Imaging Service at [diagnosticimaging@angell.org](mailto:diagnosticimaging@angell.org) or 617-541-5139 should you have any further questions, or if you have a case that you think may benefit from a nuclear scintigraphic study. ■

We encourage you to email Angell's specialists with questions.

Main Phone: 617-522-7282

Veterinary Referrals: 617-522-5011

### Chief of Staff

Ann Marie Manning, DVM, DACVECC  
amanning@angell.org

### \*24-Hour Emergency & Critical Care Medicine

Charles Amuguni, DVM  
camuguni@angell.org

Kiko Bracker, DVM, DACVECC  
kbracker@angell.org

Beata Dubiel, DVM  
bdubiel@angell.org

Autumn Dutelle, DVM, CVA, DACVIM (Oncology)  
adutelle@angell.org

Jessica Hamilton, DVM  
jhamilton@angell.org

Roxanna Khorzad, DVM  
rkhorzad@angell.org

Tamara Kremer Mecabell, DVM  
tmecabell@angell.org

Catherine Sumner, DVM, DACVECC  
csumner@angell.org

Megan Whelan, DVM, DACVECC  
mwhelan@angell.org

### Anesthesiology

Ashley Barton-Lamb, DVM  
abartonlamb@angell.org

### \*Avian & Exotic Medicine

Brenden Noonan, DVM, DABVP (Avian Practice)  
bnoonan@angell.org

Elisabeth Simone-Freilicher, DVM, DABVP (Avian Practice)  
esimonefreilicher@angell.org

### Behavior

Terri Bright, Ph.D., BCBA-D  
tbright@angell.org

### \*Cardiology

Nancy Laste, DVM, DACVIM (Cardiology)  
nlaste@angell.org

Rebecca Malakoff, DVM, DACVIM (Cardiology)  
rmalakoff@angell.org

Rebecca Quinn, DVM, DACVIM (Cardiology and IM)  
rquinn@angell.org

### Dentistry

William Rosenblad, DVM  
wrosenblad@angell.org

### Dermatology

Klaus Loft, DVM  
keloft@angell.org

Meghan Umstead, DVM  
mumstead@angell.org

### Diagnostic Imaging

Rebecca Manley, DVM, DACVR  
rmanley@angell.org

Joan Regan, VMD, DACVR  
jregan@angell.org

Steven Tsai, DVM, DACVR  
stsai@angell.org

### \*Internal Medicine

Doug Brum, DVM  
dbrum@angell.org

Maureen Carroll, DVM, DACVIM  
mccarroll@angell.org

Erika de Papp, DVM, DACVIM  
edepapp@angell.org

Jean Marie Duddy, DVM  
jduddy@angell.org

Kirstin Johnson, DVM, DACVIM  
kcjohnson@angell.org

Shawn Kearns, DVM, DACVIM  
skearns@angell.org

Susan O'Bell, DVM, MPH, DACVIM  
sobell@angell.org

Cynthia Talbot, DVM  
ctalbot@angell.org

### Neurology

Allen Sisson, DVM, MS, DACVIM (Neurology)  
asisson@angell.org

### Nutrition

Dana Hutchinson, DVM, DACVN  
dhutchinson@angell.org

### Oncology

Jennifer Mahoney, DVM, DACVIM (Oncology)  
jmahoney@angell.org

Carrie Wood, DVM, DACVIM (Oncology)  
cawood@angell.org

### Ophthalmology

Daniel Biros, DVM, DACVO  
dbiros@angell.org

Martin Coster, DVM, MS, DACVO  
mcoster@angell.org

### Pain Medicine

Lisa Moses, VMD, DACVIM, CVMA  
lmoses@angell.org

### Pathology (Clinical & Anatomical)

Patty Ewing, DVM, MS, DACVP  
pewing@angell.org

Pamela Mouser, DVM, MS, DACVP  
pmouser@angell.org

### \*Surgery

Sue Casale, DVM, DACVS  
scasale@angell.org

Michelle Kudisch, DVM, DACVS  
mkudisch@angell.org

Michael Pavletic, DVM, DACVS  
mpavletic@angell.org

Meghan Sullivan, DVM, DACVS  
msullivan@angell.com

Nicholas Trout, MA, VET MB, MRCVS, DACVS, DECVS  
ntrout@angell.org

\*Services available at our Waltham location.



350 South Huntington Ave.  
Boston, MA 02130  
617-522-5011

293 Second Ave.  
Waltham, MA 02451  
781-902-8400

[angell.org](http://angell.org)

[facebook.com/AngellReferringVeterinarians](https://www.facebook.com/AngellReferringVeterinarians)

Nonprofit Org.  
US Postage  
PAID  
Permit No. 1141  
Boston, MA

We mail one complimentary copy of our newsletter to each of our referring partners. Please circulate this copy within your practice.



Saturday/Sunday Appointments: Angell offers expanded appointment hours for many services. Please visit [angell.org/hours](http://angell.org/hours).



Are your clients new to Angell? Send them to [angell.org/directions](http://angell.org/directions) for detailed directions to our locations. Free parking on site.

## REFERRAL CONTACT INFORMATION

For additional information, please contact Eleanor Cousino, Angell Referral Coordinator, at **617-522-5011**, or by fax at **617-989-1635**. You may also find our appointment hours at [angell.org/hours](http://angell.org/hours).

### Anesthesiology Service

Referral Contact: Kim Swank  
Referral Line: 617-541-5048  
Referral Fax: 617-989-1660  
Email: [anesthesia@angell.org](mailto:anesthesia@angell.org)  
[angell.org/anesthesia](http://angell.org/anesthesia)

### \*Avian & Exotic Medicine Service

Referral Contact: Stacey Escalante  
Referral Line: 617-989-1561  
Referral Fax: 617-989-1668  
Email: [avianexotic@angell.org](mailto:avianexotic@angell.org)  
[angell.org/avianandexotic](http://angell.org/avianandexotic)

### Behavior Service

Referral Contact: Michalla Bishop  
Referral Line: 617-989-1520  
Referral Fax: 617-989-1627  
Email: [behavior@angell.org](mailto:behavior@angell.org)  
[angell.org/behavior](http://angell.org/behavior)

### \*Cardiology Service

Referral Contact: Rebecca Stlaske  
Referral Line: 617-541-5038  
Referral Fax: 617-989-1653  
Email: [cardiology@angell.org](mailto:cardiology@angell.org)  
[angell.org/cardiology](http://angell.org/cardiology)

### Dentistry Service

Referral Contact: Michael Johnson  
Referral Line: 617-524-5643  
Referral Fax: 617-989-1636  
Email: [dentistry@angell.org](mailto:dentistry@angell.org)  
[angell.org/dentistry](http://angell.org/dentistry)

### Dermatology Service

Referral Contact: Rebecca Stlaske  
Referral Line: 617-524-5733  
Referral Fax: 617-989-1613  
Email: [dermatology@angell.org](mailto:dermatology@angell.org)  
[angell.org/dermatology](http://angell.org/dermatology)

### Diagnostic Imaging

Referral Contact: Radiology Staff  
Referral Line: 617-541-5139  
Referral Fax: 617-989-1617  
Email: [diagnosticimaging@angell.org](mailto:diagnosticimaging@angell.org)  
[angell.org/diagnosticimaging](http://angell.org/diagnosticimaging)

### \*24 Hour Emergency/Critical Care Service

Referral Line: 617-522-5011  
Referral Fax: 617-989-1633  
Email: [emergency@angell.org](mailto:emergency@angell.org)  
[angell.org/emergency](http://angell.org/emergency)

### \*Internal Medicine

Referral Contact: Cathy Reid  
Referral Line: 617-541-5186  
Referral Fax: 617-989-1657  
Email: [internalmedicine@angell.org](mailto:internalmedicine@angell.org)  
[angell.org/internalmedicine](http://angell.org/internalmedicine)

### Neurology Service

Referral Contact: Lisa Canale  
Referral Line: 617-541-5140  
Referral Fax: 617-989-1666  
Email: [neurology@angell.org](mailto:neurology@angell.org)  
[angell.org/neurology](http://angell.org/neurology)

### Nutrition

Referral Contact: Eleanor Cousino  
Referral Line: 617-522-5011  
Referral Fax: 617-989-1635  
Email: [nutrition@angell.org](mailto:nutrition@angell.org)  
[angell.org/nutrition](http://angell.org/nutrition)

### Oncology Service

Referral Contact: Stacey Escalante  
Referral Line: 617-541-5136  
Referral Fax: 617-989-1668  
Email: [oncology@angell.org](mailto:oncology@angell.org)  
[angell.org/oncology](http://angell.org/oncology)

### Ophthalmology Service

Referral Contact: Rachael Donnelly  
Referral Line: 617-541-5095  
Referral Fax: 617-989-1647  
Email: [ophthalmology@angell.org](mailto:ophthalmology@angell.org)  
[angell.org/eyes](http://angell.org/eyes)

### Pain Medicine Service

Referral Contact: Lisa Canale  
Referral Line: 617-541-5140  
Referral Fax: 617-989-1666  
Email: [painmedicine@angell.org](mailto:painmedicine@angell.org)  
[angell.org/painmedicine](http://angell.org/painmedicine)

### Pathology Service (Clinical and Anatomical)

Referral Contact: Laboratory Staff  
Referral Line: 617-541-5014  
Referral Fax: 617-522-7356  
Email: [pathology@angell.org](mailto:pathology@angell.org)  
Sample submission forms and information at [angell.org/lab](http://angell.org/lab)

### \*Surgery Service

Referral Contact: Kim Swank  
Referral Line: 617-541-5048  
Referral Fax: 617-989-1660  
Email: [surgery@angell.org](mailto:surgery@angell.org)  
[angell.org/surgery](http://angell.org/surgery)

\*Services available at our Waltham location.