



EMERGENCY AND CRITICAL CARE

PAGE 1
Emergency Preparedness

ANESTHESIA

PAGE 1
Difficult Feline Intubations and How to Prepare for Them

INTERNAL MEDICINE

PAGE 6
Approach to Radioactive Iodine (I-131)

DIAGNOSTIC IMAGING

PAGE 8
CT and MRI: Setting Realistic Expectations and Knowing Limitations

PHYSICAL REHABILITATION

PAGE 10
Extracorporeal Shock Wave Therapy (ESWT): A Non-Invasive Treatment Option in Veterinary Medicine

AVIAN AND EXOTIC

PAGE 12
Dental Disease in Domestic Ferrets

NEUROLOGY

PAGE 14
First-Time Seizure in the Geriatric Pet



EMERGENCY AND CRITICAL CARE

Emergency Preparedness

Ashley Lockwood, DVM, DACVECC
angell.org/emergency | emergency@angell.org | 781-902-8400

Emergency medicine can be both exciting and rewarding. Regardless of size or location, every veterinary hospital has the potential to encounter pet emergencies, from vaccine reactions to anesthetic complications. Often, immediate diagnosis and intervention make the difference between life and death for these pets. So, every veterinary team member needs to broaden their knowledge and sharpen their skills. This is done through good client communication, training, equipment preparation, and understanding the art of triage.

Client Management

Client communication is one of the most important aspects of emergency preparedness in your practice. Clients remember how they were treated and how you made them feel during a very difficult time. They are faced with life and death decisions and asked to spend hundreds to thousands of dollars in a matter of minutes to hours, with much uncertainty as to the prognosis. These cases need to be handled with empathy while communicating directly and clearly. Veterinarians and support

(CONTINUED ON PAGE 2)



ANESTHESIA

Difficult Feline Intubations and How to Prepare for Them

Sandra Allweiler, DVM, DACVA, DMVA, CCRT
angell.org/anesthesia | anesthesia@angell.org | 617-541-5048

Risk factors for anesthetic-related death in cats

Endotracheal intubation has been identified as a risk factor for anesthesia-related morbidity and mortality in cats. Results from the confidential enquiry into perioperative small animal fatalities (EPSAF) (Brodgelt et al. 2007) have shown that between June 2002 and June 2004, 175 deaths were classified as anesthetic and sedation related. During the study, 79,178 anesthetic and sedation procedures were recorded, and the

overall risk of anesthetic and sedation-related death was 0.24% (95% CI 0.20–0.27). Factors associated with increased odds of anesthetic-related death were poor health status (ASA physical status classification), increasing age, extremes of weight, increasing procedural urgency and complexity, endotracheal intubation, and fluid therapy. Pulse monitoring and pulse oximetry were associated with reduced odds.

(CONTINUED ON PAGE 4)

EMERGENCY AND CRITICAL CARE

Emergency Preparedness

CONTINUED FROM PAGE 1

staff need to be properly trained and engaged to ensure that client expectations are clearly understood and managed. Clients need to understand the value of what you have to offer. So, attention to detail, minimizing wait times, and frequent updates are essential.

Preparedness

No task is too small or insignificant during an emergency. Establishing protocols for emergencies can help to reduce confusion and uncertainty for staff members when handling these cases outside of the daily routine. Having consent and stabilization forms for walk-in emergencies can help expedite diagnostics and therapy before the veterinarian can speak to the owner. Providing support staff with training and scripts can improve the emergency experience on both sides and empowers staff to be calm and confident during a very stressful time. Outlining staff roles during emergencies and continued training will help maintain confidence and teamwork.

In addition to training and practice, a well-stocked emergency station and crash cart are required for success. An emergency station that is centrally located (i.e., equidistant from surgery, radiology, laboratory, etc.) or near the entrance and unobstructed is ideal. Additional considerations include:

- Surgical suite level lighting
- Wet table / adjustable scale gurney
- Multiparameter machine with EtCO₂
- ER ultrasound
- Suction
- Oxygen with face masks of various sizes and nasal prongs
- Bandage material
- IV catheter materials
- Various fluids and pressure bag
- Crash cart

A crash cart with wheels and at least five to six drawers is recommended. Some crash carts are equipped with portable oxygen as well. Keeping the drawers well labeled and stocked will help with efficiency. A defibrillator and ECG monitor are also suggested and can often fit on top of the crash cart.

Triage

Triage is the art of differentiating between stable and critically ill or unstable patients. Every hospital should have established guidelines and trained personnel for telephone and in-hospital triage. Obtaining accurate information from the client is important, but not all clients are equipped with the appropriate knowledge to assess or describe their



Drawer	Supplies
First (top)	Emergency Drugs <ul style="list-style-type: none"> - Epinephrine - Atropine - Lidocaine - Calcium gluconate - Dextrose Assorted syringes with needles attached <ul style="list-style-type: none"> - Large saline flushes
Second / Third	Airway supplies (separated by size) <ul style="list-style-type: none"> - Endotracheal tubes - large dogs - Laryngoscopes long blade - Endotracheal tubes - small dogs and cats - Short blade - Stylet - 3cc and 6cc syringes attached to ET tube for cuff inflation - ET tube ties - Tracheostomy tubes
Fourth	IV Catheter supplies <ul style="list-style-type: none"> - Catheters (multiple sizes) - Tape - Flushes - T-sets
Fifth	Centesis supplies <ul style="list-style-type: none"> - Large bore catheters - #10 blades - 3-way stop cock - Extension sets - Syringes (12cc-60cc) Red rubber catheters Cut down packs
Sixth	Open-chest CPR packs Internal defibrillator paddles Blood pressure cuffs EZ IO Gun and catheters

EMERGENCY AND CRITICAL CARE

Emergency Preparedness

CONTINUED FROM PAGE 2

pet's condition. Several historical and/or observed problems warrant an immediate evaluation by a veterinarian, including trauma, respiratory distress, active seizures, urethral obstruction, loss of consciousness, excessive bleeding or anemia, poisonings, prolapsed organs, snake bites, heatstroke, open wounds exposing large areas of soft tissue and/or bone, burns, dystocia, or other signs of shock. Failure to appropriately evaluate these patients in a timely manner can quickly lead to death.

Often, the first triage is over the phone or in the front lobby. The front desk or phone staff should have prompts to help determine the urgency of evaluation for each patient. Clients should be questioned about mentation/responsiveness, respiratory effort, gum color, evidence of hemorrhage, or an abnormal limb position. The pet can be further evaluated by a technician or veterinarian based on these answers. While the pet is being evaluated, the client can check in, sign consent forms, and give additional known but brief history using the acronym "AMPLE."

- A – Allergy to medications or previous blood transfusions
- M – Medications/supplements, dose, last time given
- P – Past pertinent medical history
- L – Last (meal, urination, defecation – were they normal?)
- E – Events (leading to pet presenting, previously administered treatments, response, diagnostics)

The "Primary Survey" is the initial assessment of the emergency patient, and the purpose is to identify life-threatening physiologic problems. This "Primary Survey" follows the ABCs (and Ds) of triage and resuscitation. Whenever a problem is identified, immediate therapy should be initiated.

The ABC(D)s of Triage

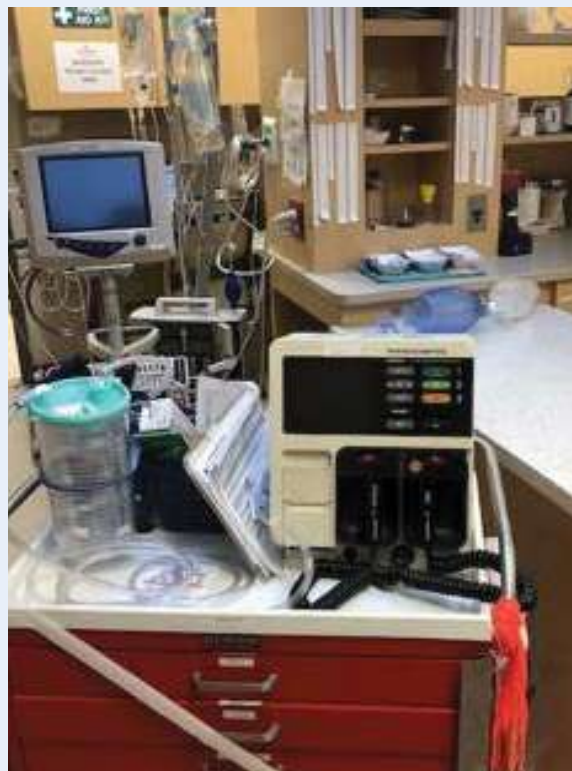- Airway (patent)
- Breathing
- Circulation
- Disability/Dysfunction (CNS)

The airway should be evaluated for foreign objects, mucus, blood, or vomit signs. If fluids (mucus, blood, vomit) are identified, the oral cavity should be suctioned using a large-bore suction catheter. If foreign objects cannot be removed easily, a Heimlich-like maneuver can be performed. If this is not successful, an emergency tracheostomy should be performed without hesitation.

If the patient is breathing, is it dyspneic? Does the patient look like it is going to fatigue or respiratory arrest? If this worsens the patient's breathing, intubation should be performed immediately, and ventilation should be initiated. In some instances, mild sedation can be helpful to alleviate the stress/anxiety a patient is experiencing.

Obstructive breathing patterns are often slow and deep, while pulmonary contusions, pulmonary edema, pneumothorax, pleural effusions, diaphragmatic hernias, and broken ribs can result in rapid, shallow (restrictive) breathing patterns.

Circulation can be assessed by looking for signs of hemorrhage, fluid loss (externally or into cavities), heart disease, assessing gum color (pale vs. cyanotic vs. brick red), femoral pulse quality, extremity temperature, and/or level of abdominal distention. Vascular access should be obtained rapidly, and fluid or pharmacologic intervention should be determined based on the level/type of shock the patient is exhibiting.



Disability/CNS dysfunction can be evaluated by determining if the patient has a reduced level of consciousness, evidence of seizures (pre-ictal, ictal, post-ictal), abnormal body and/or head posture, abnormal or asymmetric pupil size, and decreased response to light.

While resuscitation and management of the life-threatening problems are occurring, the "Secondary Survey" can begin to identify any other problems related to the trauma or illness. A complete history is obtained, and the entire body is examined (head to tail). Necessary diagnostics samples should be collected. The patient should be set up with a definitive treatment plan, and reassessment is imperative to ensure the patients ongoing recovery.

ANESTHESIA

Difficult Feline Intubations and How to Prepare for Them

CONTINUED FROM PAGE 1

What makes cats more difficult for orotracheal intubation?

Feline airways are small and more sensitive to trauma, spasm, and edema than other species. The glossoepiglottic frenulum runs from the dorsal surface of the tongue to the cranial aspect of the epiglottis. Pulling the tongue rostrally moves the tip of the epiglottis forward and down, exposing the laryngeal inlet and vocal cords.

Proper airway management is essential for safe anesthesia in cats. General anesthesia is associated with loss of protective airway reflexes and respiratory depression. The importance lies in maintaining a patent airway and supporting ventilation when required. Most anesthetic-related deaths occur after premedication during an induction or soon after anesthesia ends (within the first three hours) and are commonly caused by airway obstruction.

Laryngospasm

Cats are prone to laryngospasm, characterized by tight closure of the arytenoids in response to mechanical or chemical stimulation. Laryngospasm can occur during intubation as well as during extubation. It is rare for it to happen later during recovery. Applying 0.1 ml lidocaine 2% onto the arytenoid cartilages can blunt the spasm. Thirty seconds should be allowed for the local anesthetic to take effect. Propofol, alfaxalone, sedatives, and neuromuscular blocking agents can reduce the occurrence of laryngospasm.

Necessary equipment and methods

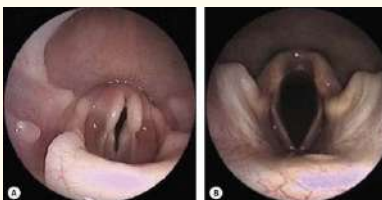A laryngoscope to visualize the rima glottidis (space between the vocal ligaments). The laryngoscope should have a long enough blade to allow correct placement at the base of the epiglottis. It should not touch the epiglottis. The light needs to be checked to be in good working order and bright. Using the flashlight from a smartphone can add an extra light source.

Endotracheal tubes

Endotracheal tubes come in a wide range of internal diameters. Endotracheal tubes with cuffs provide a secure airway; there is no leakage of oxygen or inhalation of anesthetic agents when the cuff is inflated, which allows ventilation, and placement can be confirmed by visualization between arytenoids. Disadvantages are: requiring skills and a deeper plane of anesthesia, traumatic injury and tracheal damage can occur. Overinflation of the cuff can cause necrosis or tear of the trachea. Endotracheal tubes uncuffed provide a patent airway, reduce the risk for tear, and visualize placement. They do not protect from aspiration; inhalation anesthetic leaks around the tube during spontaneous breathing and mechanical ventilation.

Endobronchial intubation is possible if the ET tube is pushed beyond the thoracic inlet. Regardless of what type or size endotracheal tube is used, the length should correspond to the distance between the patient's incisors and the point of the shoulder (thoracic inlet). Stylets can increase stiffness in the floppier silicone tubes, but the tip should be blunt and remain within the lumen of the endotracheal tube.

› Endoscopic view of normal cat (A) and dog (B). Photo credit: Dr. Nicole van Israel



Additional equipment

Cotton tipped applicators can be helpful to clear mucus and saliva, but a suction unit should be readily available to clean excess saliva, which often occurs in patients with upper respiratory tract obstruction. A urinary catheter with a 3.5 mm internal diameter ETT connector attached can be used as a stylet or to provide oxygen. A bougie is a flexible device made of braided polyester with a resin coating. It can be used instead of a urinary catheter to guide the ETT. The advantage is that it is more rigid than a urinary catheter and may be easier to place. The disadvantage is that the capnograph or oxygen supply cannot be connected unless a special bougie with a central lumen and port for ventilation is used.

V-gel: Supraglottic airway devices

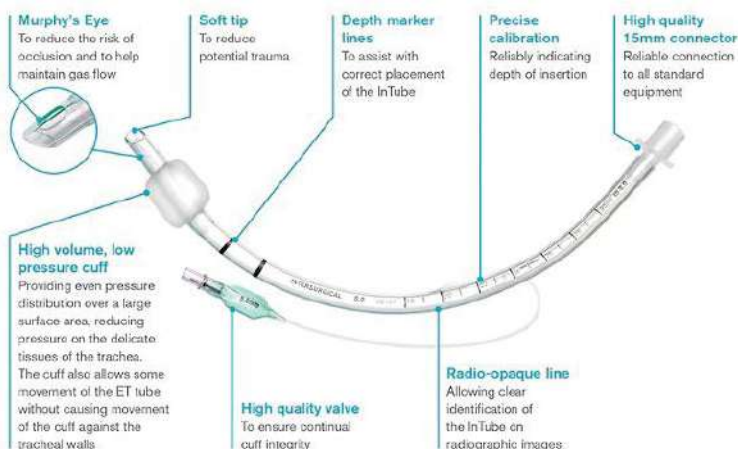
These devices do not enter the trachea and end above the larynx. They are specifically designed for the cat's pharyngeal and laryngeal anatomy. Studies have shown that the time to obtain a clinically acceptable capnograph reading is shorter when a supraglottic airway device is used compared with an ETT, fewer attempts were needed, and less propofol was required. Disadvantages are that correct placement cannot be confirmed by visualization, changes in patient position can easily dislodge the device, and it may take up to much room for oral procedures. Supraglottic airway devices are not recommended if abnormal laryngeal anatomy is present.

Fiber-optic-assisted intubation

Fiber-optic intubation (FOI) is an effective technique for establishing airway access in patients with anticipated and unanticipated difficult airways. First described in the late 1960s, this approach facilitated airway management and was added to ASA guidelines for managing difficult airways.

Video laryngoscopy (VL) is a form of indirect laryngoscopy in which the clinician does not directly view the larynx. Instead, visualization of the larynx is performed with a fiber-optic or digital laryngoscope inserted trans-nasally or transorally. Images are magnified, allowing for a detailed examination of the larynx. The images from video laryngoscopy can be displayed on a monitor and recorded.

Fiber-optic intubation involves threading an endotracheal tube over a flexible fiber-optic scope shaft. The scope is passed through the mouth or nose into the pharynx and through the vocal folds into the patient's trachea. Upon visual confirmation



ANESTHESIA

Difficult Feline Intubations and How to Prepare for Them

CONTINUED FROM PAGE 4

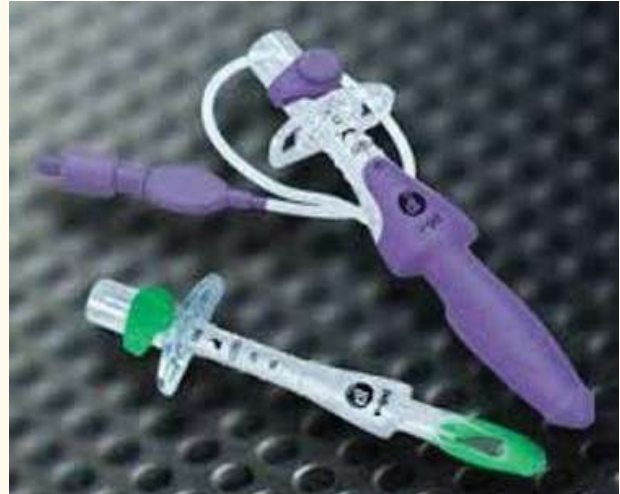of tracheal rings and carina, the fiber-optic scope is held steady while the ET tube is advanced over the fiber-optic bundle into the airway. Once the tube is in place, the scope is removed.

A new simple, fast and safe oral intubation technique for rats, which is very similar to VL for intubation in humans, has been described using a cost-effective, commercially available device for ear wax removal in humans. It may help in difficult cat intubations, but future research is warranted.

Veterinary video otoscopes that connect to an iPhone/iPod, using its camera technology to provide a high-definition image of the anatomy, have also been used for intubation. The dual-channel for flushing and removing foreign objects such as foxtails can be used to guide a urinary catheter as a stylet through the vocal folds and advance the ET tube quickly and easily. This technique has been used and facilitates intubation in rabbits and other pocket pets and may also have a place in cat intubation.

Clinical airway management continues to advance at a fast pace. Devices produced over the last 30 years have transformed airway management in human medicine, and it is only a question of time and skills until they will become readily available in veterinary medicine.

› V-gel advanced supraglottic airway device



› Emergency & Critical Care Service Open at Angell West; Urgent Care Available by Appointment

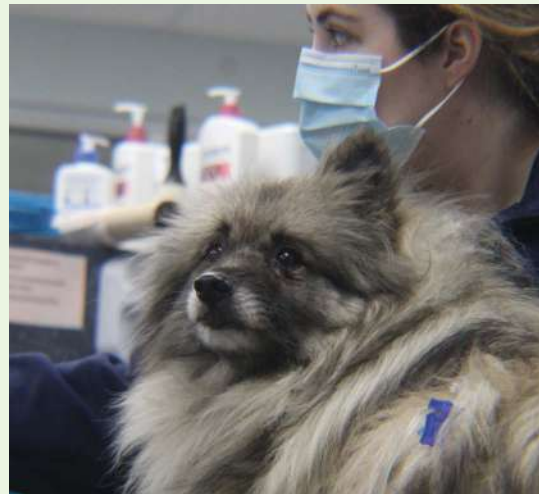We are pleased to announce that the Emergency and Critical Care service at the MSPCA-Angell West (Waltham, MA) has re-opened and is once again available 24/7 for clients whose pets need immediate medical care for life-threatening trauma or disease.

Referring veterinarians may alert staff to an incoming case by calling 781-902-8400. Due to expected high case load, there may be times when Angell West diverts cases. Please call to ensure availability.

For more information, please visit angell.org/emergency.

For non-emergent cases, the Urgent Care service at Angell West is available Monday through Thursday for dogs and cats. Exotic mammal Urgent Care appointments are available through the Angell West Avian and Exotics service on some days as well. Clients can call up to one day in advance to book an Urgent Care appointment; this is not a walk-in service.

For more information, please visit angell.org/urgentcare.





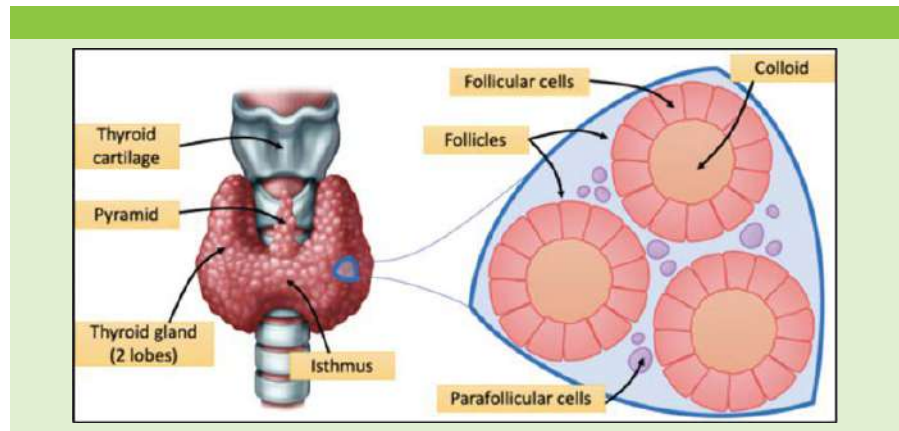
Approach to Radioactive Iodine (I-131)

Evan Mariotti, DVM, DACVIM
angell.org/internalmedicine | internalmedicine@angell.org | 617-541-5186

Anatomy and Physiology of the Thyroid Gland

In humans, the thyroid gland is located ventral to the trachea, with both lobes connected by an isthmus. In cats, there is no isthmus, and thus both lobes are separated and located on both sides of the trachea. It is made of glandular tissue with cells in follicles. Follicles are filled with colloid that incorporates the main storage of thyroid hormones. There are also parafollicular cells outside of the follicles that secrete calcitonin.

The synthesis of thyroid hormones occurs within the thyroid follicular cells and the colloid. Iodine is taken into the body and converted to iodide in the gastrointestinal tract. It is transported into the follicle cells by the Na^+/I^- symporter, oxidized in the follicular cell to the active form, and then moves into the colloid. A molecule called thyroglobulin is synthesized and undergoes exocytosis into the colloid. The thyroglobulin is then iodinated by thyroid peroxidase into monoiodotyrosine (MIT) and diiodotyrosine (DIT). MIT and DIT are either linked together to form T3 or DIT links with another DIT to form T4. Thyroglobulin then undergoes endocytosis into the follicular cells then fuses with a lysosome that cleaves off T3 and T4 via hydrolysis. T3 and T4 then leave the thyroid follicular cells to peripheral tissues. In those tissues, T4 is converted to the active form of T3.



Thyroid hormone penetrates the cell membranes and acts on the nucleus to initiate mRNA transcription. This leads to increases in oxygen consumption, increases in heat production, enhancement of the sympathetic nervous system effects by beta-adrenergic receptors, increases in heart rate and contractility, and increased lipolysis, among several other actions. Thyroid hormone is essential for normal growth. Without it during development, animals are born with disproportionate dwarfism or they die in utero.

Feline Hyperthyroidism

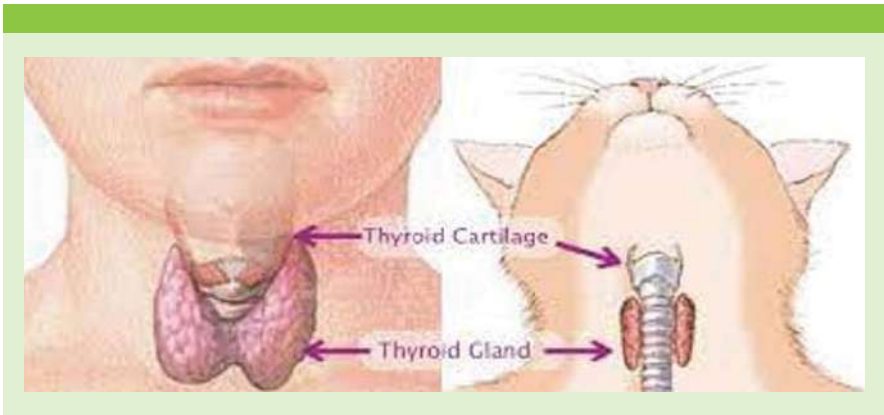
Feline hyperthyroidism (FHT) is the most common endocrine disease in the cat. It has a 6% incidence rate in all cats over the age of 9-years-old, and that

incidence rate is increasing. There is a thought that, potentially, this has to do with an increase in goitrogens in commercial cat food with varying degree of iodine as well. Hyperthyroid cats will most likely have bilateral adenomas with a greater than 50% chance of being asymmetrical. Unilateral disease occurs in much fewer patients. Cats can also have ectopic thyroid tissue anywhere from the thyroid gland area to the base of the heart. Thyroid carcinoma in cats is very rare.

Signs of FHT are commonly weight loss, goiter, a thin BCS, and heart murmur. Common diagnostics to detect FHT are total T4 and free T4. Less common diagnostics include the T3 suppression test, TRH stimulation test, and thyroid scintigraphy. Treatments for FHT include antithyroid drugs, limited iodine foods, radioactive iodine, and thyroidectomy, with each treatment having its own set of advantages and disadvantages.

Radioiodine Therapy

In the body, thyroid hormone and thyroglobulin are the only molecules that require iodine. Therefore, all ingested iodine goes only to the thyroid gland through the Na^+/I^- symporter. If iodine is tagged with radioactivity (I-131), beta particles will destroy the local tissues in the hyperactive adenomas. Adjacent normal tissues can also be destroyed by collateral damage. Radioiodine can be administered subcutaneously, intramuscularly, or through the mouth.



INTERNAL MEDICINE

Approach to Radioactive Iodine (I-131)

CONTINUED FROM PAGE 6

I-131 is indicated for cats with methimazole reactions, owners who can't medicate their cats, and owners looking for a cure. It is also considered for cats that don't like the limited iodine diets and owners who want to avoid thyroidectomy. Diagnostics needed before therapy include full labs with three months of presentation (ideally a set of labs on and off of methimazole), imaging of the chest and abdomen, and thyroid scintigraphy. As much as possible can be done at the local vet. After the appropriate diagnostics are performed, a dose of I-131 is carefully formed based on the results and patient condition. Some other facilities that perform radioiodine therapy may give the same dose to each patient (usually 3mCi). Angell uses 3mCi as a starting point, and increases or decreases may be made based on the diagnostics results.

After treatment, we house the cats in a particular ward where we monitor them for any side effects of the treatment (anorexia, laryngitis, dehydration, etc.) and give any appropriate treatments. We keep the cats for a minimum of 72 hours post-treatment per Massachusetts state law. It is at the owner's discretion if they want to take the cat home on all restrictions (contact and litter) or to board them for the full restriction timetable of 17 days after treatment when contact restrictions are lifted. Litter restriction can be lifted after 10 to 14 days.

A T4 and kidney values should be rechecked in one month and three months post-administration. If the patient is hypothyroid at the three-month mark, they will likely need supplementation with L-thyroxine. If the patient is persistently hyperthyroid, they can pursue any of the previous treatment options illustrated, but most commonly, they are retreated with radioiodine and will be euthyroid post-procedure in most cases.

› A cat with hyperthyroidism prior to treatment





CT and MRI: Setting Realistic Expectations and Knowing Limitations

Ruth Van Hatten, DVM, DACVR
angell.org/diagnosticimaging | diagnosticimaging@angell.org | 617-541-5139

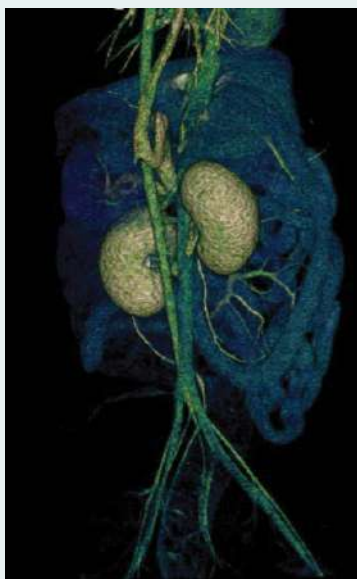
Cross-sectional imaging has become a mainstay in veterinary imaging, and what was once considered unavailable or too expensive is now widely used daily. CT and MRI have allowed veterinarians to improve the quality of care drastically, and with pet insurance being more commonplace, they are no longer considered unaffordable. The purpose of this article is to compare the pros and cons of CT and MRI and discuss the various indications in which one modality would be recommended over the other.

Computed Tomography (CT) uses numerous X-ray beams in a helical format surrounding the patient to create a 3D image. CT uses ionizing radiation approximately 10 times that of a comparable radiographic study. This does impose a greater risk of DNA damage than radiographs; however, the benefits greatly outweigh these risks when indicated. It is generally accepted that the shorter life expectancy of our domestic pets decreases the chances of long-term side effects of radiation exposure. Compared to MRI, CT is very quick and has become even faster with increased slices and newer models. This has allowed some studies to be performed under heavy sedation instead of general anesthesia, specifically, emergency cases where the patient is too unstable to undergo general anesthesia and routine musculoskeletal exams (for example, evaluation for elbow dysplasia). Abdominal CT has been shown to detect more lesions in dogs greater than 25kg compared to abdominal ultrasound because the larger size of the patients and gastrointestinal gas hampers complete visualization of all organs on ultrasound. In addition, thoracic CT has been shown to better detect pulmonary nodules compared to radiography.

Three-phase CT angiograms have been used to evaluate vascular anomalies such as portosystemic shunts, aortic arch malformations, arteriovenous malformations, and anomalous coronary arteries. Three-phase angiograms can be performed with power contrast injectors and high slice CT machines. This allows improved surgical planning as arteries can be differentiated from veins, and the vascular

FIGURE 1

› 3D image of CT angiography demonstrating a single congenital extrahepatic portosystemic shunt extending from the portal vein to the azygos vein.



anatomy has better resolution. In addition, three-phase studies have been shown to increase the detection of insulinomas and specific metastatic lesions within the abdomen.

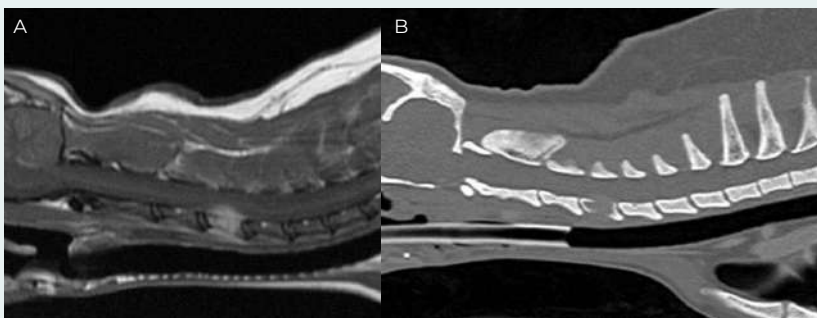
CT is the gold standard for evaluating trauma cases, as patients can be scanned quickly with improved diagnosis of subtle fractures compared to radiographs. CT has improved soft-tissue contrast compared to radiographs and evaluates the bone. CT has been shown to have a sensitivity of up to 100% for detecting acute bone lesions. In evaluating complex pelvic fractures and imaging the skull, CT is recommended as a superimposition on radiographs significantly affects thorough evaluation.

In contrast, Magnetic Resonance Imaging (MRI) uses radio waves and a magnetic field to create a 3D image. It is overall considered very safe and does not utilize ionizing radiation. Because a magnetic field is involved in creating the image, the main risk factors are projectiles secondary to the strong magnetic field and possible motion and heating of ferromagnetic objects within the body (e.g., metallic implants). It is important to note that this is considerably more of a concern in human medicine, where patients commonly have pacemakers and aneurysmal clips. MRI is significantly longer than CT, and general anesthesia is required as motion while imaging results in significant artifacts. In addition, the cost of an MRI scan can be two to three times that of a CT scan.

So when is MRI better than CT? MRI is considered the gold standard for neuroimaging. MRI allows superb soft tissue contrast allowing differentiation between grey and white matter

FIGURE 2

› MRI of the neck in T1w plus contrast (A) and a CT in bone algorithm (B) in the sagittal plane. The T4 vertebral body contains an expansile tumor resulting in lysis of the bone and secondary compression of the spinal cord.



DIAGNOSTIC IMAGING

CT and MRI: Setting Realistic Expectations and Knowing Limitations

CONTINUED FROM PAGE 8

within the brain and spinal cord. Thus, MRI is generally recommended over CT for any patient with neurologic deficits. The few instances where CT can be used over MRI are with suspected middle ear disease resulting in peripheral vestibular signs and in some cases of suspected intervertebral disc displacement (as mineralized displaced discs can be visualized on CT). One report showed that only approximately 8% of patients that have undergone CT for thoracolumbar myelopathy required additional imaging to come to a diagnosis. Despite CT having good diagnostic capability, MRI is overall more sensitive and accurate than non-contrast CT for diagnosing intervertebral disc herniation, and thus MRI remains the gold standard. MRI has improved imaging for inflammatory lesions compared to CT in evaluating intracranial disease, but one report documents that CT is similar to MRI in measuring brain tumors (specifically gliomas). MRI has been shown to detect meningeal enhancement better and has a greater measured tumor volume than CT in dogs with nasal tumors. With superior soft-tissue contrast, MRI also allows for greater visualization of tendons and ligaments than CT. Imaging canine joints (specifically shoulder and stifle) with MRI allows improved diagnosis of tendon and ligament injuries and is commonly used in human medicine to evaluate soft tissue injuries.

In some cases, both MRI and CT are used concurrently to obtain the most information to develop a complete treatment plan, specifically, trauma cases with suspected fractures with concurrent neurologic deficits. MRI would be recommended to thoroughly evaluate the spinal cord and structural soft tissues of the vertebral column for injury and acute, traumatic disc displacement. MRI can detect inflammation in and around bone, but CT would be recommended to better evaluate the bone margins for fractures and fissure lines, in addition to surgical planning. Another example includes malformations resulting in neurologic deficits requiring surgical intervention (such as vertebral malformations such as kyphosis).

Veterinary medicine has come a long way with improvements in cross-sectional imaging. The future holds improved soft tissue resolution with thoracic and abdominal MRI compared to CT with the use of respiratory and cardiac gating to eliminate associated motion artifacts. As new developments

and technology become more readily available, improved diagnostic capability is inevitable in both CT and MRI. When determining which modality would be recommended, many factors must be considered, including patient size, stability, clinical differential diagnosis, and experience/comfort level.

REFERENCES

- Armbrust LJ, et al. JAVMA 2012;240(9):1088-1094
- Cooper JJ, et al. VRU 2014;55(2):182-189.
- Emery L, Hecht S, and Sun X. VRU 2018;59(2):147-154.
- Fields EL, et al. VRU 2012;53(5):513-517.
- Gallastegui, A, et al. VRU 2019; 60(5): 533-542.
- Hansen SC, et al. J Vet Emerg Crit Care (San Antonio) 2019; 29(3): 301-308.
- Lux CN, et al. VRU 2017; 58(3): 315-325.
- Robertson I and Thrall DE. VRU 2011; 52(1 Suppl 1): S81-84.
- Stadler KL, et al. Front Vet Sci 2017; 25(4): 157



➤ Angell's Referring Vet Portal

24/7 access to your referred patients' records angell.org/vetportal

We are pleased to offer the Angell Referring Veterinarian Portal to our referring partners. This mobile-friendly portal provides secure, 24/7 access to your referred patients' records. The system automatically updates throughout the day and provides access to:

- Online medical records
- Discharge instructions
- Referral reports
- SOAPs
- Check-in status
- Prescriptions
- Lab results
- Diagnostic images

Settings can be customized within the portal to receive notices by email or fax and you may list multiple emails to receive check-in, discharged, deceased, and update notices.

Visit angell.org/vetportal or call our referral coordinator at 617-522-5011 to gain access to your account.



Extracorporeal Shock Wave Therapy (ESWT): A Non-Invasive Treatment Option in Veterinary Medicine

Amy Straut, DVM, CCRT
 angell.org/rehab | physicalrehab@angell.org | 781-902-8400

What is Extracorporeal Shock Wave Therapy (ESWT)?

Shock waves are sound waves that carry energy and travel through tissues, gas, liquids, and solids. These sound waves are non-linear pressure waves that have both a positive and negative phase that affects interfaces between tissues with different densities.¹ The positive phase has a direct mechanical tensile force, and the negative phase creates a secondary effect via cavitation, as bubbles are formed and collide and explode, generating a second indirect shock wave effect.²

Acting as a mechanical stimulus, ESWT promotes healing through mechanotransduction,³ in which cells sense and respond to mechanical stimuli by converting them to biochemical signals that elicit specific cellular responses.

Studies conclude that shock waves generate interstitial and extracellular responses, producing beneficial effects such as:

- **Tissue Regeneration**, via neovascularization, protein biosynthesis, and cell proliferation⁴
- **Pain Relief**, via decreasing concentration of pro-inflammatory mediators and instigating release of endorphins by activating descending inhibitory systems⁵
- **Destruction of calcification in musculoskeletal structures**, via mechanical fragmentation, phagocytosis⁶

Combining these effects can lead to improved functional outcomes of injured tissues.

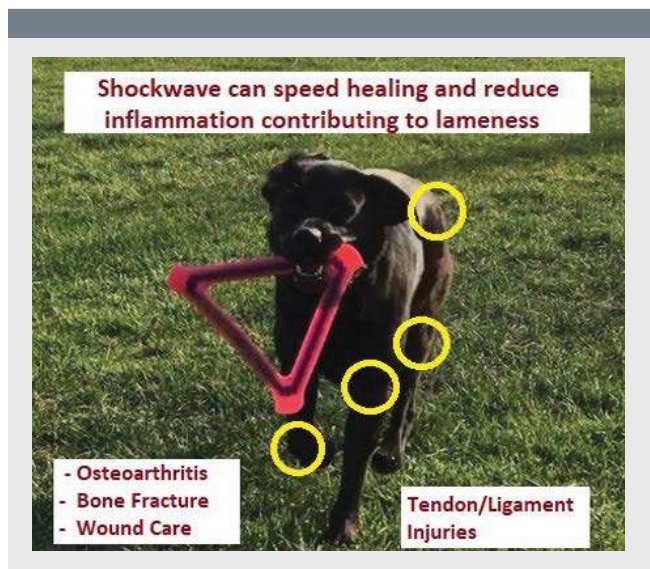
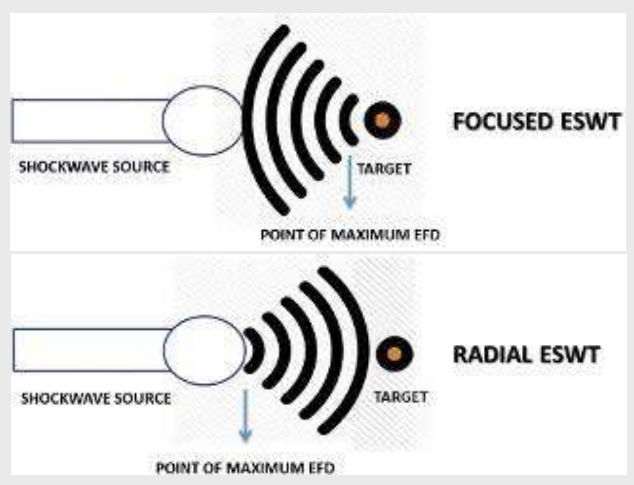


FIGURE 1

› The fundamental differences between focused and radial ESWT:⁴



Shock wave treatment is administered via a hand-held device called a trode. The trode is placed directly on the treated area of the body and is typically optimized for transmission using a conductive gel.

Types of ESWT

1. **Focused Shock wave (FSWT)** Delivered from a device that generates a pressure field that converges at a selected depth in body tissues where maximum pressure is reached.
2. **Radial Shock wave (RSWT)** Delivered by a device that reaches maximal pressure at the device source itself and is relayed into tissues.

Comparing Focused ESWT with Radial ESWT

FSWT is termed “Focused” because the generated pressure field converges at an adjustable focus at a selected depth in the body tissues. **This focus point is where the maximum pressure is reached.** These waves are generated in water within the trode, which allows for a more natural transference of waves into the body (limited reflection).

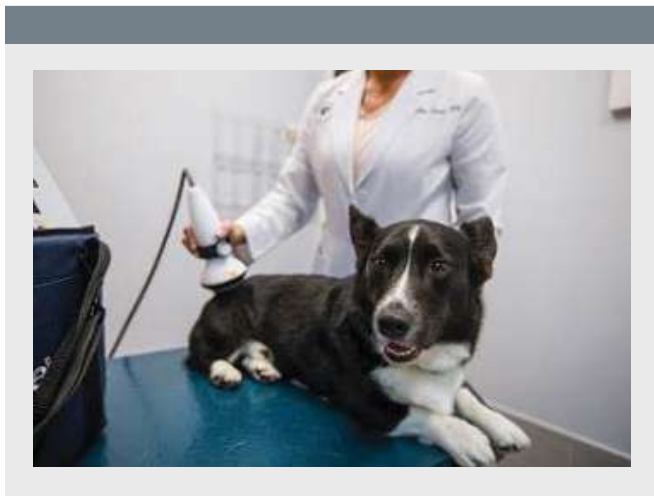
RSWT produces radial waves that produce their **maximal pressure at the source of generation (trode).** These waves are generated in air, where a projectile hits the end of the trode, which then transmits the generated pressures waves into the body.

As a result, RSWT has a more superficial effect than FSWT, penetrating and focusing their energy much deeper into the body.

PHYSICAL REHABILITATION

Extracorporeal Shock Wave Therapy (ESWT)

CONTINUED FROM PAGE 10



Uses of ESWT

A shock wave is a non-invasive modality, making it an alternative for non-surgical patients. It may also be an excellent supplemental modality for pain management as part of a physical rehabilitation plan.

ESWT is commonly used for

- Tendon & Ligament Healing (Supraspinatus, Biceps, Achilles, & Patellar tendinopathies)
- Osteoarthritis (elbow, stifle, hip)
- Bone Healing (delayed union, slow fracture healing)

Contraindications of ESWT

- Bone tumors
- Metabolic bone conditions where bone may be too fragile
- Location at open growth plate
- Area where active infection is present
- Over body cavities where air/gas is present (abdomen, thorax)

Clinical Use

The typical shock wave treatment session is relatively quick (five to 10 mins), and for some patients that require lower energy settings, sedation is often not needed. However, treatment at higher energy settings can be loud and may be acutely painful, and sedation may be required. Light sedation with oral administration of Gabapentin and Trazodone before the appointment may be adequate. If a higher level of sedation is needed, it is reasonable to administer dexmedetomidine +/- analgesic in a healthy dog.

Treatment of musculoskeletal conditions is recommended every three weeks for one to three treatments or until clinical improvement is achieved. Disease resolution is not normally expected when ESWT is used to manage osteoarthritis, so the treatment protocol is often repeated every six to 12 months (one to three treatments).

Patients typically begin experiencing the pain relief benefits of ESWT within 24 to 48 hours but can be mildly uncomfortable during the initial post-administration waiting period. NSAIDs are usually adequate coverage for pain management during this waiting time.

ESWT is typically used in conjunction with a physical rehabilitation program, including activity control and therapeutic exercises for return to best function. Please get in touch with our Physical Rehabilitation Services Team with questions regarding the integration of ESWT into a patient's treatment protocol.

The MSPCA-Angell hospitals in Waltham and Boston are equipped with cutting-edge ProPulseVersaTron FSWT equipment. Our orthopedic surgeons in both locations can evaluate and recommend a shock wave treatment protocol for a post-surgery plan or as a possible alternative treatment plan to surgery.

Referral for shock wave treatment directly with our Physical Rehabilitation Team requires a veterinary orthopedic surgeon to evaluate the pet, and shock wave has been approved as an appropriate treatment plan.

Referral forms for both Surgery and Physical Rehabilitation services can be easily submitted online at angell.org/referrals.

REFERENCES

1. Leeman J, Shaw K et al. Extracorporeal shockwave therapy and therapeutic exercise for supraspinatus and biceps tendinopathies in 29 dogs. *Vet Rec*. 2016; Oct 15; 179(15):385.
2. Cleveland R. The acoustics of shock wave lithotripsy. *AIP Conf Proc*. 2007 (1): 900.
3. Khan K, Scott A, Mechanotherapy: how physical therapists' prescription of exercise promotes tissue repair. *Br J Sports Med*. 2009; 43(4): 247-252.
4. Simplicio C, Purita J et al. Extracorporeal shock wave therapy mechanisms in musculoskeletal regenerative medicine. *J Clin Ortho and Trauma*. 2020; (11): S309-S318.
5. Saggini R, Di Stefano A et al. Clinical application of shock wave therapy in musculoskeletal disorders. *J Biol Regul Homeost Agents*. 2015 (3) 533-545.
6. Lowe M et al. Shockwave therapy is effective for chronic calcifying tendonitis of the shoulder. *J Bone Joint Surg Br*. 1999, 81: 863-867.



Avian and Exotic Dental Disease in Domestic Ferrets

Patrick Sullivan, DVM, DABVP (Avian practice)
angell.org/avianandexotic | avianexotic@angell.org | 617-989-1561

Domestic ferrets (*Mustela putorius furo*) are commonly seen at primary care veterinary hospitals and avian and exotics specialty practices. Ferrets have a brachyodont dentition, with 28 to 30 deciduous teeth and 34 permanent teeth. Much like dogs and cats, periodontal disease is seen in many ferrets as they age. Similar to those species, ferrets also require routine dental prophylaxis to reduce the risk of permanent damage to the dentition and gingiva. The dental formula of an adult ferret is 2(I 3/3; C 1/1; P 3/3; M 1/2).

Plaque accumulation mineralizes and becomes calculi, which allows an overgrowth of bacteria on the crown and at the edge of the gingiva. The degree of periodontal disease can be categorized into 4 stages, based on the severity of the condition. These stages will be described in greater detail below. Compared to feral ferrets of New Zealand, domestic ferrets have a much higher degree of dental pathology. Diet is thought to play a role in this condition, as wild and domestic ferrets obligate carnivores. Dry kibble diets, while nutritionally balanced, can be pretty abrasive on the enamel of the teeth. Over time this can cause weakening and discoloration. While semi-moist or wet foods are thought to promote dental calculi in other species, ferrets have been

shown to develop periodontal disease when fed exclusively dry kibble. Whole prey diets may slow the progression of periodontal disease in domestic ferrets, but this may be difficult for some owners. If not appropriately made, homemade diets are often lacking in essential nutrients.

In addition to periodontal disease, ferrets can also sustain dental trauma. Due to their curious behavior and penchant for chewing non-food items, fractures of the crowns are not uncommon. The maxillary canine teeth are often damaged due to chewing on cage bars or other hard objects or secondary to a fall. Superficial damage to the tooth may also occur, but frequently this does not require extraction. Exposure of the pulp cavity, or periapical abscess formation, would warrant extraction of the affected tooth.

Stages of Periodontitis

Stage 1: Gingivitis - Erythema and possible swelling noted at the edge of the gingiva. This condition is caused by bacterial colonization on the plaque, mineralizing, and becoming dental calculi if left untreated. Calculi will not be removed by brushing and requires ultrasonic scaling under general anesthesia.



Stage 2: Early Periodontitis - Progression of gingivitis may lead to infection of the gingiva, bone, and surrounding tissue. Gingival recession (up to 25%) or periodontal pocketing may be noted at this time as well. While not common, abscessation of the gingiva can occur during this stage.

Stage 3: Moderate Periodontitis - Worsening of gingival recession (up to 50%) and root exposure are seen in this stage. Large periodontal pockets are identified during probing and may bleed. Food material may be found in these pockets and between exposed roots.

› Dr. Sullivan performing a dental prophylaxis on a ferret patient.



Dental Disease in Domestic Ferrets

CONTINUED FROM PAGE 12

Stage 4: Advanced Periodontitis - Gingival recession is greater than 50%, often with blood or purulent material around tooth roots. Tooth loss is common at this stage, and several teeth extractions may be required, despite intervention. Gingiva is often so painful at this point that the patient may need sedation or even full anesthesia.

Dental Prophylaxis

Ferrets requiring a dental prophylaxis will need to be anesthetized and intubated during the procedure. Aside from a physical exam, a preoperative CBC and chemistry panel should be performed to ensure there are no underlying conditions that may increase the anesthetic risk or change the protocol for the patient. Due to their high metabolic rate and risk of hypoglycemia, ferrets should only fast for two hours before anesthesia. Much the same as other dental procedures in small animals, once anesthetized, ferrets require endotracheal intubation to protect the airway during ultrasonic scaling and polishing. A cuffed 3.0 endotracheal tube is often used, but this size tube is occasionally too large, and an uncuffed tube is needed. In this case, it is vital to keep the head angled slightly down to avoid aspiration. All crowns are scaled using an ultrasonic scaler, and the gingiva is probed for any abnormal pocketing or abscessation. Once it is determined that all teeth appear healthy and no extractions are required, the crowns are polished using an animal safe prophylaxis paste.

If extractions are deemed necessary, the technique will depend on which tooth is being removed. Canine teeth can be removed using a periodontal flap technique, where the gingiva is incised and reflected away to allow access to the root. A high-speed pneumatic drill may be used to burr away surrounding bone, allowing an elevator to be introduced into the socket to break down periodontal ligament attachments. For teeth with multiple roots, it may be necessary to section the tooth into pieces to remove each root individually. Sockets can then be flushed with a chlorhexidine solution and sutured using a polydioxanone suture.

Conclusion

While there is no way to avoid dental pathology in ferrets altogether, owners can certainly take proactive steps to try and improve their ferret's overall oral health. Brushing daily with a safe animal toothpaste and a soft-bristled brush is ideal. This is the best way to reduce the amount of plaque that accumulates on the crowns and at the edge of the gingiva. Water additives and cat dental treats may also benefit, but all treats must be evaluated for the risk of possible gastrointestinal obstruction if large pieces are bitten off and swallowed whole. Finally, annual or biannual exams are needed to evaluate the oral cavity and track any changes in the medical record.

REFERENCES

- Johnson-Delaney, Cathy A. 2007. Ferret Dental Disorders: Pictorial of Common Clinical Presentations. *Exotic DVM* 9(2): 40-43.
- Cooper, Janyce. 2017. Ferret Dentistry: No Weaseling About It. *Today's Veterinary Nurse*. Jan/Feb.
- Quesenberry, Katherine A., Carpenter, James W. 2012. Ferrets, Rabbits, and Rodents Clinical Medicine and Surgery. Third Edition. St. Louis (MO): Elsevier. Chapter 3, Gastrointestinal Diseases; p. 27



First-Time Seizure in the Geriatric Pet

Rob Daniel, DVM, DACVIM (Neurology)

angell.org/neurology | neurology@angell.org | 617-541-5140

A first-time seizure in the geriatric pet usually prompts an emergent visit, whether to the general practice or an emergent/tertiary care facility. When the pet has presented to the hospital, the pet may be fully recovered, experiencing post-ictal signs, or actively seizing.

Epileptic activity in a pet that hasn't experienced seizures in either recent or distant history offers a myriad of possible causes after initial questioning has determined that the episode experienced was likely seizure and not one of the 'great pretenders,' such as syncopal, vasovagal event, cataplectic or narcoleptic activity. Although late-onset epilepsy is a possibility, consideration should be given to a particular cause. Differential diagnoses are degenerative (e.g., cerebral cortical atrophy), metabolic (hypothyroidism, hypoglycemia, nutritional), neoplastic (primary vs. secondary), inflammatory (infectious, non-infectious), traumatic, toxic (endogenous, such as those related to hepatopathy, or exogenous) and vascular.

A point-of-care panel to assess PCV, TP, blood glucose, BUN is advised, along with blood pressure. Intravenous support through the implementation of an IV catheter should be considered and decided upon based on recent history, clinical examination findings at the time of presentation, and an initial suggested action plan discussed with the pet's family. A minimum database can be collected at such a time and either held or submitted, including a CBC, serum biochemistry profile, urinalysis, and thyroid panel. A particular geographic region will often add particular tests to this 'minimum' database, such as infectious disease testing.

General physical examination and neurologic examination are vital in deciding on an action plan. Cardiovascular auscultation and abdominal palpation should be included in the first-time seizure patient. This can help support seizure over a possible syncopal event or a vasovagal episode caused by intra-abdominal hemorrhage secondary to a splenic or hepatic mass. Considering the older age in this signalment and neoplastic differential diagnoses, paying particular attention to the lymph nodes and rectal examination as part of the complete examination is advised.

A seizure implies a forebrain neuroanatomic diagnosis, and once a detailed history has increased confidence in such a clinical sign, such a neuroanatomic diagnosis can be deduced through reflection alone. Aspects of the neurologic examination that include the forebrain in testing, namely mentation assessment, particular cranial nerve testing such as menace response testing, nasal septum stimulation testing, and postural reaction testing, can further support this neuroanatomic diagnosis. Paying particular attention to asymmetry during postural reaction testing and cranial nerve testing can help increase suspicion for a particular structural cause, such as a vascular event or neoplastic process. Notably, the absence of inter-ictal neurologic deficits does not exclude the structural differential diagnoses.

Once it has been established that a seizure has indeed occurred, arriving at a forebrain neuroanatomic diagnosis, the pet has been examined, and initial patient support has been instituted, ranging from monitoring in hospital with or without IV access to a multi pharmacy in trying to control seizure activity, a decision must be made as to whether or not to start maintenance antiepileptic medications. Making such a decision can be relatively straightforward or complicated by comorbidities, the family's wishes, or the practitioner's confidence in deciding on an appropriate time to start maintenance therapy or an appropriate first-line anticonvulsant.

Deciding against when to start maintenance therapy can often be helped along by signalment of the pet, severity of seizure, seizure frequency (if such a history exists and this is not truly a first-time seizure), expected compliance of the family, the family's wishes regarding treatment and particular anticonvulsant drug choice. In general, instituting maintenance therapy after a second seizure can often help assess the efficacy of the medication, decision-making on behalf of the family to pursue further testing towards establishing a cause for the seizure, and owner compliance. Starting maintenance therapy after a solitary seizure is not wrong. However, questions of efficacy may arise and doubts on behalf of the family as to whether particular side effects of a given medication are a necessary step in helping to control seizure activity.

Given the widespread use, supply, lower likelihood of side effects, and higher safety index of drugs such as levetiracetam and zonisamide, they are routinely used as first-line maintenance therapy. The general practitioner can often implement these drugs, serve as a starting point for further seizure management to build upon, and provide beneficial therapy to increase seizure threshold until the pet is seen by a veterinary neurologist. Starting doses and recommended lab monitoring can be referenced easily from any one of many handbooks in a hospital's particular library.

Depending on a primary care veterinarian's proximity to a veterinary specialty center and, specifically, a veterinary neurologist, advising an initial neurologic consultation with a board-certified specialist after a first seizure can be helpful. A neurologic consultation can often give the family further directions on maintenance/rescue therapy and support for managing expectations and is an essential step in deciding on definitive testing, including advanced imaging of the brain.



Physical Rehabilitation at MSPCA-Angell West

Watch patients enjoy land-based and hydrotherapy treatment in our Physical Rehabilitation facility at angell.org/rehab

Canine and feline physical rehabilitation is used to treat a wide variety of orthopedic and neurological conditions. Whether recovering from an injury, cross-training, or facing a mobility issue, dogs and cats can substantially benefit from physical rehabilitation.

MSPCA-Angell West Physical Rehabilitation offers services seven days a week. Jennifer Palmer, DVM, Certified Canine Rehabilitation Therapist (CCRT), and Amy Straut, DVM, CCRT, lead our Physical Rehab team. Visit angell.org/rehab for details and video footage showing the impact of their work on our patients.

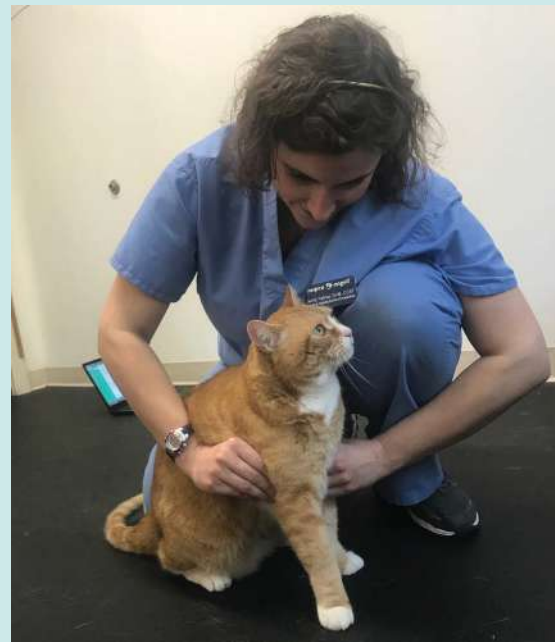Physical Rehabilitation services include:

- Hydrotherapy
- Land-based exercise
- Manual therapy
- Therapeutic laser treatment
- Massage
- Consultation and fitting of assistive devices
- Chiropractic


mspca  **angell west**



Land-based Exercise Area



Hydrotherapy – AquaPaws Water Treadmills



Hydrotherapy – Indoor Pool

› Angell Fall Continuing Education — **Registration is Open!**

Topics will range from Allergy Testing to Top 10 Things to Know When Seeing Exotic Animal Species.

Sunday, October 23, 2022

8:15am – 2:45pm

5 Interactive CE Credits (Pending RACE Approval)

FEATURED SPEAKERS:

- Terri Bright, PhD., BCBA-D, CAAB
- Kate Cummings, DVM, DACVAA
- Meagan Painter, DVM, DACVD
- Jennifer Palmer, DVM, CCRT
- Anne Staudenmaier, VMD, DABVP (Avian Practice)

Endocrinology

Wednesday, November 9, 2022

6:15pm – 8:45pm

2 Interactive CE Credits (Pending RACE Approval)

FEATURED SPEAKERS:

- David Carabetta, DVM, DACVECC
- Lisa Gorman, DVM, DACVIM



JOIN US FOR A LIVE, INTERACTIVE WEBINAR!

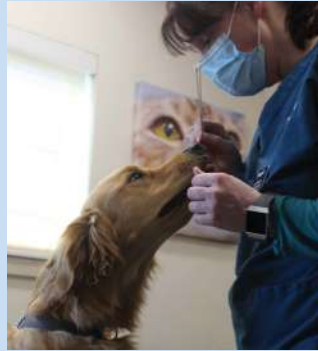To register for our Fall 2022 online webinars, please visit angell.org/ce

› Angell Offers Low-Cost, Need-Based Clinics

Angell at Essex (Danvers, MA) and **Angell at Nashoba** (Westford, MA) clinics are dedicated to providing quality care to the general public as well as offering deeply-discounted services for qualified low-income families. The clinics provide primary veterinary care, spay/neuter services, vaccinations, and surgery and dental services.

The clinics do not provide overnight care, specialty service care, or 24/7 emergency care. Appropriate cases will be referred to Angell's Boston or Waltham facilities or a surrounding specialty veterinary referral hospital.

To see if your clients qualify for financial assistance, please visit angell.org/essex or angell.org/nashoba



angell at nashoba

To schedule an appointment with the Angell at Nashoba clinic, please call **978-577-5992**.

angell at essex

To schedule an appointment with the Angell at Essex clinic, please call **978-304-4648**.



Left to Right: Dr. Laurence Sawyer, Angell at Nashoba on campus at Nashoba Valley Technical High School (Westford, MA).



Angell at Essex on campus at Essex North Shore Agricultural and Technical School (Danvers, MA).

› MSPCA-Angell Clinics in Boston, Methuen, and on Cape Cod

Offering subsidized veterinary care to help keep pets and families together.

The clinics provide spay/neuter services as well as acute outpatient surgical care, but they do not provide primary, overnight, or emergency veterinary care. The clinics are meant for families who cannot afford urgent medical care and are faced with a painful choice between euthanasia, surrender, or bringing an animal home against medical recommendations. By providing subsidized, low-cost veterinary care, the clinic provides a new pathway for families in need. We welcome your referrals to our clinics.

mspca **angell clinic**

Boston | Cape Cod | Nevins Farm

MSPCA-Angell Cape Cod and Boston clinics
Monday – Friday, 8am-4pm

MSPCA-Angell Nevins Farm in Methuen
Monday – Saturday, 8am-4pm

To refer low-income clients, please visit angell.org/referrals

MSPCA-Angell Clinic Boston: 617-541-5007 | MSPCA-Angell Clinic Cape Cod: 508-815-5226 | MSPCA-Angell Clinic Nevins Farm: 978-379-6605



STAFF DOCTORS AND RESIDENTS

■ We encourage you to contact Angell's specialists with questions.

Main Phone: 617-522-7282 (Boston) | Main Phone: 781-902-8400 (Waltham) | Veterinary Referrals: 617-522-5011
Angell at Nashoba: 978-577-5992 | Angell at Essex: 978-304-4648

CHIEF OF STAFF

Ann Marie Greenleaf, DVM, DACVECC
agreenleaf@angell.org

24-HOUR EMERGENCY & CRITICAL CARE MEDICINE, BOSTON

Alison Allukian, DVM
aallukian@angell.org

Laura Badeski, DVM
lbadeski@angell.org

Kiko Bracker, DVM, DACVECC
Service Director
kbracker@angell.org

David Carabetta, DVM, DACVECC
dcarabetta@angell.org

Callie Cazlan, DVM
ccazlan@angell.org

Elton Chan, DVM
echan@angell.org

Sara Doyle, DVM
sdoyle@angell.org

Rose Feldman, VMD
rfeldman@angell.org

Scout Ford, VMD
sford@angell.org

Molly Graham, DVM
mgraham@angell.org

Brandi Lauer, DVM
blauer@angell.org

Katherine McKean, DMV
kmckean@angell.org

Patrick Odom, DVM
podom@angell.org

Abbey Petronzio, DVM
apetronzio@angell.org

Virginia Sinnott-Stutzman, DVM, DACVECC
vsinnottstutzman@angell.org

Nathalie Suci, DVM
nsuci@angell.org

Julia VanDerslice, DVM
jvanderslice@angell.org

Megan Whelan, DVM, DACVECC, CVA
Chief Medical Officer
mwhelan@angell.org

24-HOUR EMERGENCY & CRITICAL CARE MEDICINE, WALTHAM

Jordana Fetto, DVM
jfetto@angell.org

Mina Gergis, DVM
mgergis@angell.org

Ashley Lockwood, DVM, DACVECC
alockwood@angell.org

Amanda Lohin, DVM
alohin@angell.org

Courtney Peck, DVM, DACVECC
cpeck@angell.org

Jessica Seid, DVM
jseid@angell.org

Catherine Sumner, DVM, DACVECC
Chief Medical Officer, Waltham
csumner@angell.org

ANESTHESIOLOGY

Sandra Allweiler, DVM, DACVAA, CMVA, CCRT
sallweiler@angell.org

Kate Cummings, DVM, DACVAA
kcummings@angell.org

Becca Reader, BA, DVM, DACVAA
rreader@angell.org

AVIAN & EXOTIC MEDICINE (W/B)

Brendan Noonan, DVM, DABVP (Avian Practice)
bnoonan@angell.org

Elisabeth Simone-Freilicher, DVM, DABVP (Avian Practice)
esimonefreilicher@angell.org

Anne Staudenmaier, VMD, DABVP
astaudenmaier@angell.org

Patrick Sullivan, DVM, DABVP (Avian Practice)
(Boston & Waltham)
psullivan@angell.org

BEHAVIOR (W/B)

Terri Bright, PhD, BCBA-D, CAAB
tbright@angell.org

CARDIOLOGY

Katie Hogan, DVM, DACVIM (Cardiology)
(Boston)
khogan@angell.org

Clint Lynn, DVM
clynn@angell.org

Michelle Oranges, DVM
moranges@angell.org

Jordan Vitt, DVM, DACVIM
jvitt@angell.org

DENTISTRY

Alice Ekerdt Goodman, DVM, DAVDC
aekerd@angell.org

Jessica Riehl, DVM, DAVDC
jriehl@angell.org

Joyce Tai, DVM, MS
jtai@angell.org

DERMATOLOGY (W/B)

Klaus Loft, DVM
kloft@angell.org

Meagan Painter, DVM, DACVD
mpainter@angell.org

Brooke Simon, DVM
(Residency Trained)
(Boston & Waltham)
bsimon@angell.org

DIAGNOSTIC IMAGING (W/B)

Naomi Ford, DVM, DACVR
nford@angell.org

Steven Tsai, DVM, DACVR
stsai@angell.org

Ruth Van Hatten, DVM, DACVR
rvanhatten@angell.org

INTERNAL MEDICINE (W/B)

Michelle Beehler, DVM
mbeehler@angell.org

Douglas Brum, DVM
dbrum@angell.org

Maureen Carroll, DVM, DACVIM
mccarroll@angell.org

Zach Crouse, DVM, DACVIM
zcrouse@angell.org

Lisa Gorman, DVM, DACVIM
(Waltham)
lgorman@angell.org

Jessica Hayes, DVM
jhayes@angell.org

Shawn Kearns, DVM, DACVIM
skearns@angell.org

Evan Mariotti, DVM, DACVIM
emariotti@angell.org

Susan O'Bell, DVM, DACVIM
Service Director
sobell@angell.org

Juliana Picard, DVM
jpicaard@angell.org

Annie Sheu-Lee, DVM
asheulee@angell.org

Daisy Spear, DVM
dspear@angell.org

Lindsey Summers, DVM
lsummers@angell.org

Daniela Vrabelova Ackley, DVM, DACVIM
(Waltham)
dvrabelova@angell.org

STAFF DOCTORS AND RESIDENTS

CONTINUED FROM PAGE 18

NEUROLOGY

Rob Daniel, DVM, DACVIM
(Neurology)
rdaniel@angell.org

Michele James, DVM, DACVIM
(Neurology)
mjames@angell.org

Jennifer Michaels, DVM, DACVIM
(Neurology)
jmichaels@angell.org

ONCOLOGY

Kristine Burgess, DVM, MLA, DACVIM
(Medical Oncology)
kburgess@angell.org

Kendra Lyons, DVM (Medical Oncology)
klyons@angell.org

J. Lee Talbott, DVM, DACVIM
(Medical Oncology)
jtalbott@angell.org

Jillian Walz, DVM, DACVIM
(Medical Oncology), DACVR
(Radiation Oncology)
jwalz@angell.org

OPHTHALMOLOGY

Daniel Biros, DVM, DACVO
dbiros@angell.org

Martin Coster, DVM, MS, DACVO
mcoster@angell.org

PATHOLOGY
(CLINICAL & ANATOMIC)*

Patty Ewing, DVM, MS, DACVP
pewing@angell.org

Pamela Mouser, DVM, MS, DACVP
pmouser@angell.org

PHYSICAL REHABILITATION**

Jennifer Palmer, DVM, CCRT
jpalmer@angell.org

Amy Straut, DVM, CCRT
astraut@angell.org

SURGERY (W/B)

Sue Casale, DVM, DACVS
scasale@angell.org

Caroline Choi, DVM
cchoi@angell.org

Kathryn Heidgerd, VMD
kheidgerd@angell.org

Michael Pavletic, DVM, DACVS
mpavletic@angell.org

**Nicholas Trout, MA, VET MB, MRCVS,
DACVS, DECVS**
ntrout@angell.org

Emily Viani, DVM
eviani@angell.org

URGENT CARE
BY APPOINTMENT ONLY, WALTHAM

Alina Ermilio, DVM
aermilio@angell.org

ANGELL AT NASHOBA

Mary-Kate O'Toole, DVM
mkotoole@angell.org

Laurence Sawyer, DVM
lsawyer@angell.org

(W/B) Services also available at our Waltham location

*Boston-based pathologists and radiologists serve both Boston and Waltham locations

**Available only in Waltham



› Courtesy Shuttle for Patients Needing Further Specialized Care

Angell Animal Medical Center offers the convenience of our MSPCA-Angell West facility in Waltham, MA. The Waltham facility offers Urgent Care and specialized service appointments Monday through Saturday. If needed, an oxygen-equipped courtesy shuttle can transport animals to Boston for further specialized care and then return them to Waltham. Whether in Boston or in Waltham, our specialists regularly collaborate and plan treatments tailored to our patients' emergency, surgical, and specialty needs.

WE OFFER A BROAD RANGE OF EXPERTISE AND DELIVER THIS CARE WITH
THE ONE-ON-ONE COMPASSION THAT OUR CLIENTS AND PATIENTS DESERVE.

We mail one complimentary copy of our newsletter to each of our referring partners. Please circulate this copy within your practice.

Summer 2022 | angell.org | facebook.com/mspcaangell

MSPCA-ANGELL
350 South Huntington Avenue
Boston, MA 02130
617-522-5011
angell.org

MSPCA-ANGELL WEST
293 Second Avenue
Waltham, MA 02451
781-902-8400
angell.org/waltham

ANGELL AT NASHOBA
100 Littleton Road
Westford, MA 01886
978-577-5992
angell.org/nashoba

ANGELL AT ESSEX
565 Maple Street
Danvers, MA 01923
978-304-4648
angell.org/essex

MSPCA-ANGELL CLINICS
Boston | Cape Cod | Methuen
angell.org/clinics

ANGELL.ORG/DIRECTIONS (FREE PARKING) | ANGELL.ORG/HOURS | ANGELL.ORG/CE

Please consider adding Angell's main numbers to your after-hours phone message.

▸ Our Service Locations

BOSTON & WALTHAM

Avian & Exotic Medicine
617-989-1561

Behavior
617-989-1520

Dermatology
617-524-5733

Diagnostic Imaging
617-541-5139

Internal Medicine
617-541-5186

Physical Rehabilitation*
781-902-8400

Surgery
617-541-5048

Urgent Care*
781-902-8400

BOSTON ONLY

Anesthesiology
617-541-5048

Cardiology
617-541-5038

Dentistry
617-522-7282

Neurology
617-541-5140

Oncology
617-541-5136

Ophthalmology
617-541-5095

Pathology
617-541-5014

*Available only in Waltham



24/7 Emergency & Critical Care | Boston: 617-522-5011 | Waltham: 781-902-8400