


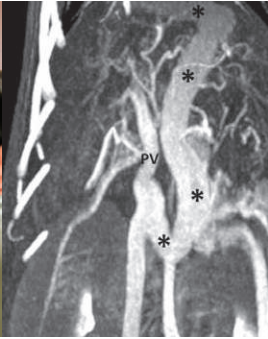

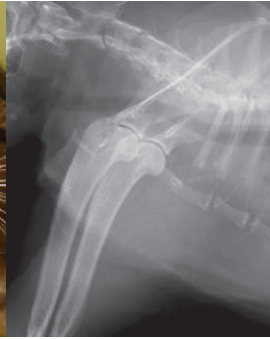



# Partners In Care

SEE INSIDE  
The new CE Schedule &  
Referral Contact Info  
on a removable postcard!

Veterinary Referral News from Angell Animal Medical Center

Fall 2014 ■ Volume 8:3 ■ [angell.org](http://angell.org) ■ [facebook.com/AngellReferringVeterinarians](https://facebook.com/AngellReferringVeterinarians)

|   |   |   |  |   |
|---|---|---|--|---|
| PERIPHERAL NERVE ANALGESIA  | PORTOSYSTEMIC SHUNTS  | FELINE HYPERADRENOCORTICISM   | MAMMARY TUMORS   | 2ND INTENTION HEALING   |
|  |  |  |  |  |
| PAGE 1  | PAGE 1  | PAGE 4  | PAGE 6   | PAGE 8  |

## DIAGNOSTIC IMAGING (CONTINUED ON NEXT PAGE)



### Imaging of Congenital Portosystemic Shunts

■ Steven Tsai, DVM, DACVR

[angell.org/diagnosticimaging](http://angell.org/diagnosticimaging)  
[diagnosticimaging@angell.org](mailto:diagnosticimaging@angell.org) 617-541-5139

The normal portal vascular system transports venous blood from the stomach, intestines, spleen, and pancreas to the hepatic sinusoids and ultimately the hepatic veins and caudal vena cava. Portosystemic shunting (PSS) occurs when abnormal vascular connections occur between the portal and systemic venous systems, bypassing the liver.<sup>1</sup> This can be acquired secondary to portal hypertension arising from chronic hepatopathy (such as cirrhosis) or congenitally due to persistence of fetal shunting vessels. Imaging diagnosis of congenital shunts is important, since surgical attenuation is the treatment of choice in clinically affected patients.<sup>2</sup>

Portosystemic shunts (PSS) can occur within the liver or outside of the liver. Intrahepatic PSS are more common in large-breed dogs, while extrahepatic PSS are more common in small- or toy-breed dogs. Yorkshire terriers in particular are overrepresented with extrahepatic PSS. Cats can also present with both intrahepatic and extrahepatic PSS, although less commonly than dogs. Congenital PSS patients can present with a spectrum of clinical signs and labwork abnormalities. They are often smaller than their littermates, fail to gain weight, may show abnormal mentation generally or after a meal, and may have chronic GI or urinary tract signs. Labwork abnormalities include microcytic nonregenerative anemia, hypoalbuminemia, decreased BUN, hypoglycemia, and hypocholesterolemia. Elevations in ALP and ALT are also common. Urinalysis may reveal ammonium biurate crystalluria. Liver function testing is routinely recommended in patients with suspected PSS, with

## ANESTHESIOLOGY (CONTINUED ON PAGE 5)



### Precision Pain Management: Peripheral Nerve Analgesia

■ Ashley Barton-Lamb, DVM, CVA

[angell.org/anesthesia](http://angell.org/anesthesia)  
[anesthesia@angell.org](mailto:anesthesia@angell.org) 617-541-5048

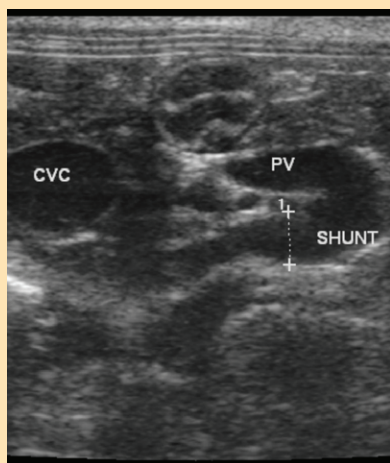
Anyone who has broken their arm or wrist as a child will tell you that orthopedic pain is debilitating. When bones are broken and mechanical instability ensues, the patient's world stops, and the pain becomes the center of all their attention. How can we as veterinarians learn to treat that severe pain in creatures that cannot verbalize these sensations and, to whatever extent, the emotions behind that pain? Even as the mechanical instability of a broken bone is resolved, both orthopedic and soft tissue pain, inflammation, and nerve pain may still be present. As the advocates for animal health, we must be aware of the complications and implications pain can have for our patients, such as delayed healing, increase in hospital stay time, and increased morbidity. Our goal should be to provide advanced surgical techniques and procedures while providing advanced pain management techniques that human medicine takes for granted.

Local/regional anesthesia is a loose term used in veterinary medicine. Local anesthesia is defined as the loss of sensation in a circumscribed area.<sup>1</sup> The term regional anesthesia is insensibility in a larger, though limited, body area.<sup>1</sup> Physicians and veterinarians have coined the term "loco-regional" anesthesia since many of our blocks can fall into both definitions. In human medicine, peripheral loco-regional anesthesia is used in the majority of orthopedic cases. In many of these operations, with more precise loco-regional nerve blocks, physicians can achieve the desired pain management that epidurals provide without the side effects, such as headache, nausea, hypotension, and potential

## DIAGNOSTIC IMAGING

FIGURE 1

Transverse ultrasound image at the level of the porta hepatis of a cat with a single extrahepatic PSS. A tortuous shunting vessel arises from the portal vein (PV), which is about half the diameter of the caudal vena cava (CVC).



elevated pre- and post-prandial serum bile acids being near 100% sensitive.<sup>1</sup>

An important differential diagnosis for dogs suspected of PSS is portal venous hypoplasia (PVH), also known as microvascular dysplasia (MVD). In this condition, there is direct communication between the (microscopic) portal venules and central hepatic veins, bypassing hepatic sinusoids.<sup>1</sup> Clinical signs of dogs with PVH/MVD are indistinguishable from those in dogs with macroscopic PSS, and Yorkshire terriers are also predisposed. For this reason, definitive imaging diagnosis of macroscopic PSS is necessary to form an accurate clinical picture.

There are many imaging options available, with plain radiography being the only modality inadequate to make a diagnosis. Abdominal radiographs may show evidence of microhepatia and renomegaly, but no direct evidence of PSS is possible. Advanced imaging options include mesenteric portography, trans-splenic portography, trans-colonic portal scintigraphy, trans-splenic portal scintigraphy, nonenhanced ultrasonography, contrast-enhanced ultrasonography, CT angiography, and MR angiography. The 3 most common imaging studies performed at Angell for PSS are ultrasound, trans-splenic portal scintigraphy, and CT angiography.

Abdominal ultrasound is the most commonly performed imaging study in PSS patients. There are several advantages to ultrasound studies for diagnosing PSS. Ultrasound is relatively low to moderate in cost, especially compared with CT. Ultrasound evaluation does not require general anesthesia, although most patients will require moderate sedation. This is because the structures being imaged are small and difficult to visualize, and slight patient motion or abdominal tenseness can prevent full evaluation of the portal system. Ultrasound also does not require exposure to ionizing radiation. Ultrasound availability is generally more widespread than CT, MR, or nuclear scintigraphy. The primary drawback to ultrasound is variable sensitivity (74-100%) and a high degree of dependence on operator skill/experience. A “shunt hunt” is not a routine component of an abdominal ultrasound, and a detailed technique is used to maximize detection of PSS. Typical secondary ultrasound findings in dogs with PSS include microhepatia, renomegaly and urolithiasis. In 1 study of dogs evaluated for potential PSS, having all 3 of these findings on ultrasound was associated with a 100% positive predictive value for PSS.<sup>3</sup> Patients with extrahepatic shunts typically will have a small portal vein at the porta hepatis, which is determined by comparing the diameter of the portal vein with the caudal vena cava or the

FIGURE 2

Long axis view of the same cat as in Figure 1; cranial is to the left. Color Doppler imaging of the shunt indicates that it crosses the diaphragm (oblique line indicated by the open arrow) and then turns and terminates on the CVC. This suggests a porto-phrenic shunt.

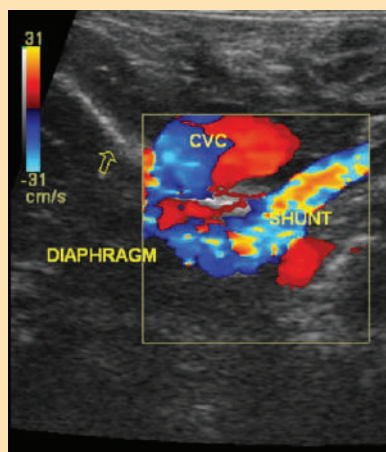
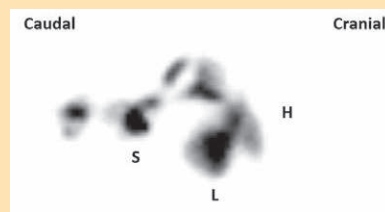


FIGURE 3

Composite image of a trans-splenic portal scintigraphy in a dog without PSS. Radiopharmaceutical uptake is seen only at the site of injection in the spleen (S) and in the liver (L), with no activity noted at the level of the heart (H) or rest of the body.

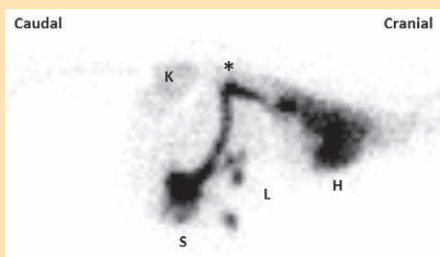

aorta. Dogs with PSS typically have a PV:Ao ratio of  $<0.65$ , while normal dogs have  $>0.8$ .<sup>3</sup> Further evidence of a shunt can be produced by injection of agitated saline into the spleen while sonographically assessing the caudal vena cava or right atrium.<sup>4</sup> Microbubbles in the saline are echogenic and may be visible in the CVC or RA in cases of PSS. Ideally, the actual aberrant vessel is visualized branching from the portal vein, typically at the level of insertion of the splenic vein or right gastric vein (Figure 1). Color Doppler interrogation of the vessel helps to indicate that blood is flowing from the portal vein into the aberrant vessel, rather than from the vessel into the portal vein, as with normal tributaries. Visualization of the shunt termination is often possible if the termination is the CVC (most common), with turbulent blood flow noted in the CVC. The termination may not be visualized if the shunt goes to the azygos vein or phrenic vein, although with azygos shunts the aberrant vessel is often seen crossing the diaphragm dorsally, adjacent to the aorta (Figure 2). Intrahepatic shunts are reportedly easier to identify with ultrasound (95-100% sensitivity). Determination of whether the intrahepatic shunt is arising from the left, central or right division of the portal vein is important, as well as whether the shunt is an actual aberrant vessel or a direct “window” connecting the PV with the CVC. This is important because intravascular coil embolization of a “window”-type shunt is not possible.

If PSS is not identified on ultrasound, the next step is typically nuclear scintigraphy or CT angiography. The advantages of nuclear scintigraphy include low to moderate cost as well as a fairly definitive “yes” or “no” answer. Disadvantages include not very widespread

FIGURE 4

⚡ Composite image of a trans-splenic portal scintigraphy in a dog with PSS. Compared with Figure 3, note that radiopharmaceutical uptake is identified at the injection site (S), then coursing dorsally and cranially in a shunt vessel (\*), bypassing the liver (L) and entering the heart (H). Note that early uptake is seen in the systemic circulation and kidneys (K).

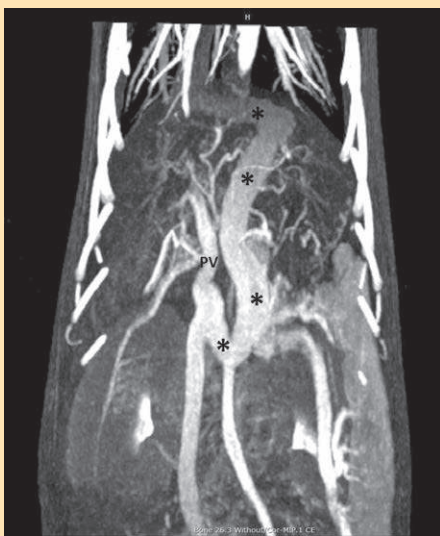

availability, lack of precise morphologic information about the shunt, and the need to quarantine the patient for 24 hours due to radioactivity (Massachusetts law). The procedure requires a heavy plane of sedation (typically propofol titration), but usually takes only 5-10 minutes. A radiopharmaceutical ( $^{99m}\text{Tc}$ -mebrofenin) is injected into the spleen with ultrasound guidance, and dynamic images of the body are acquired for several minutes. Mebrofenin has a 97% first-pass clearance rate by the liver, so in a normal dog essentially all radiopharmaceutical uptake is seen in the liver alone, with little to no systemic activity (Figure 3). In dogs with a macroscopic shunt, radiopharmaceutical uptake bypasses the liver and enters the heart first, followed by the lungs, then systemic circulation, and gradually accumulates in the liver over time (Figure 4). In dogs with PVH/MVD, uptake is seen first in the liver, but subsequently is also seen in the heart, lungs and systemic circulation. A shunt fraction can be calculated from the image data to determine the approximate percentage of portal blood bypassing the liver.<sup>5</sup>

CT angiography (CTA) has essentially supplanted mesenteric portography as the gold standard for diagnosing PSS in dogs. The primary advantage is precise morphologic information about the entire portal venous system and its relation with the systemic venous and arterial systems. Number and location of shunting vessel(s) can be determined to a degree not possible with ultrasound or scintigraphy. The disadvantages include high cost, need for general anesthesia, and lack of widespread availability of high-speed multi-slice CT. Abdominal CTA also involves a fairly high dose of ionizing radiation to the patient. Abdominal CTA typically begins with a non-contrast scan of the abdomen to determine any other morphologic abnormalities. If there is concern

FIGURE 5

⚡ Dorsal maximum intensity projection (MIP) of a CT angiogram in a dog with PSS. Cranial is at the top of the image, and the patient's right side is on the left of the image. A large tortuous shunt vessel (\*) arises from the portal vein (PV), courses caudally, to the left, cranially past the diaphragm, and then turns rightward to terminate on the CVC. This is consistent with a left gastric-phrenic shunt. Note the generally excellent visualization of the abdominal and pulmonary vasculature.



for arterio-portal malformation, an arterial phase scan may be obtained by scanning the patient during contrast injection with a power injector. The portal phase scan typically commences following a 30-to-45-second delay, and a 3-minute delayed postcontrast scan finishes the study. When performed correctly, abdominal CTA provides very-high-quality images of the portal and systemic vasculature, and the study is subject to much less interpretive error than with ultrasound or scintigraphy<sup>6</sup> (Figure 5).

In summary, portosystemic shunts are important congenital defects in dogs and cats that can be definitively diagnosed with imaging. Diagnostic workup and clinical management of PSS patients can be complex and are dependent somewhat on case specifics as well as the experience and preferences of the primary clinician, radiologist, and surgeon involved in the case. At Angell, ultrasound, scintigraphy, and CT angiography are most commonly performed in PSS patients.

## REFERENCES

- 1 Berent AC, Tobias KM. Portosystemic vascular anomalies. *Vet Clin North Am Small Anim Pract.* 2009 May 1;39:513–541.
- 2 Greenhalgh SN, Dunning MD, Mckinley TJ, et al. Comparison of survival after surgical or medical treatment in dogs with a congenital portosystemic shunt. *J Am Vet Med Assoc.* 2010 Jun 1;236:1215–1220.
- 3 D'Anjou M-A, Penninck DG, Cornejo L, Pibarot P. Ultrasonographic diagnosis of portosystemic shunting in dogs and cats. *Veterinary Radiology & Ultrasound.* 2004 Sep;45:424–437.
- 4 Gómez-Ochoa P, Llabrés-Díaz F, Ruiz S, et al. Use of transsplenic injection of agitated saline and heparinized blood for the ultrasonographic diagnosis of macroscopic portosystemic shunts in dogs. *Veterinary Radiology & Ultrasound.* 2011 Jan;52:103–106.
- 5 Daniel G. Scintigraphic diagnosis of portosystemic shunts. *Vet Clin North Am Small Anim Pract.* 2009 Jul 1;39:793–810.
- 6 Nelson NC, Nelson LL. Anatomy of extrahepatic portosystemic shunts in dogs as determined by computed tomography angiography. *Veterinary Radiology & Ultrasound.* 2011 Sep;52:498–506.

VIEW ONLINE



For more information on Angell's Diagnostic Imaging service or our online imaging consultative services, please visit [angell.org/diagnosticimaging](http://angell.org/diagnosticimaging). Dr. Tsai can be reached at 617-541-5139 or [diagnosticimaging@angell.org](mailto:diagnosticimaging@angell.org).



## Feline Hyperadrenocorticism

■ Shawn Kearns, DVM, DACVIM

angell.org/internalmedicine  
internalmedicine@angell.org 617-541-5186

**C**ase summary: Frieda, a 10-year-old FS DLH, presented primarily for evaluation of polyuria and polydipsia. Initial blood work and urinalysis were unremarkable other than mild hypernatremia and hyposthenuria (1.007). Ultrasound noted the adrenal glands were at the upper limits of normal. Over 4 months, Frieda developed insulin-resistant diabetes mellitus. A low-dose dexamethasone test was performed and lacked suppression, supporting a diagnosis of hyperadrenocorticism (HAC). Frieda was started on trilostane 2mg/kg BID. She has since come off insulin therapy and has been doing well clinically with good control based on ACTH stimulation for monitoring.

Feline hyperadrenocorticism (HAC) is a rare disease affecting usually middle-aged to older patients. Many signs are similar to canine HAC (PU/PD, symmetric alopecia, infections and peripheral neuropathy). Cats, however, also can suffer from a skin fragility syndrome, and insulin-resistant diabetes is also common with cats. The skin fragility may be so severe that simple restraint or grooming may tear the skin.

Results of initial blood testing including a CBC, general profile and urinalysis may be unremarkable, though most often these patients have changes consistent with diabetes mellitus. Increased ALP, ALT, cholesterol, and glucose are common. Acromegaly is another differential for insulin resistance and can usually be excluded with testing such as IGF-1; patients with acromegaly do not suffer from skin fragility.

The urine cortisol : creatinine ratio (UCCR) is a useful screening test for HAC, as in dogs, and should ideally be collected at home on 2 consecutive days. An alternative “at home” oral dexamethasone suppression test has been suggested in dogs and may be considered in cats, especially those with skin fragility syndrome. The owner is instructed to collect 2 urine samples from the patient on 2 consecutive mornings and store them

in the refrigerator. After collection of the 2nd urine sample, the owner should administer 3 doses of dexamethasone (0.1 mg/kg/dose) orally at 8-hour intervals. Urine is collected on the morning of the 3rd day and UCCR is determined on all 3 samples. The 1st 2 urine samples establish the diagnosis of hyperadrenocorticism; both results must be abnormal. If both values are abnormal, then the average of the 2 values is used as the “baseline” value and compared with the 3rd value obtained after dexamethasone administration. A diagnosis of pituitary-dependent hyperadrenocorticism (PDH) is established if the UCCR result from the 3rd urine sample is less than 50% of the “baseline” value. Patients failing to meet these criteria could have either adrenal-dependent hyperadrenocorticism (ADH) or PDH.

The ACTH stimulation test is not a sensitive test in cats, as it is only abnormal in 50–60% of cats with HAC. The low-dose dexamethasone test is considered to be the test of choice for diagnosis of feline HAC and is performed using a higher dose of dexamethasone (0.1 mg/kg IV) than in the dog. Cortisol concentrations will be suppressed at 8 hours in normal cats, but not in cats with HAC. Most often, additional testing such as abdominal ultrasound or a high-dose dexamethasone test is needed for differentiation of pituitary versus adrenal-dependent disease. As with dogs, 85% of cats with HAC have the pituitary-dependent form of the disease, while 15% are diagnosed with functional adrenocortical tumors.

Occasionally sex hormones, rather than cortisol, are associated clinical signs of HAC. These are most commonly associated with adrenal cortical carcinomas, and a sex hormone profile measured before and after ACTH stimulation may be needed for diagnosis.

Adrenalectomy is the treatment of choice in cats with adrenal-dependent disease. If the tumor is secreting cortisol, control of clinical signs may be achieved with trilostane prior to surgery; however, there is some

concern that use of trilostane may lead to tumor enlargement in both dogs and cats. Although, in the past, bilateral adrenalectomy was considered the treatment for pituitary-dependent disease, trilostane has been used in the last several years with very acceptable outcomes, including improvement in insulin resistance and skin fragility. It must be kept in mind that not all cats respond and the drug is not licensed in this species. Other options in cats with PDH include hypophysectomy (limited facilities) or radiation therapy of the pituitary tumor.

Feline HAC is a rare but important endocrine disease of cats. Testing should be considered in patients with compatible clinical signs. Definitive treatment may improve quality of life and long-term survival.

VIEW ONLINE



For more information, please contact Angell's Internal Medicine service at 617-541-5186 or [internalmedicine@angell.org](mailto:internalmedicine@angell.org).

# Precision Pain Management: Peripheral Nerve Analgesia

■ Ashley Barton-Lamb, DVM, CVA

angell.org/anesthesia anesthesia@angell.org 617-541-5048

cardiovascular collapse.<sup>2</sup> While loco-regional anesthesia has been touted as being safer, there are a number of possible complications as well. Seizures (0.075%), neurological injuries (0.019%), radiculopathies (0.019%), cardiac arrest (0.014%), and 1 death (0.005%) have been reported in human literature.<sup>3</sup> Infection, systemic local anesthetic toxicity, and allergic reactions have also been reported.<sup>4</sup> However, with advanced training, proper equipment, and good clinical judgment, serious complications and side effects are rare and far less common than complications with epidurals.

There are several nerve blocks commonly used today in orthopedic procedures. The two that are the focus of this article are femoral/sciatic nerve blocks and brachial plexus blocks. Both of these techniques will require the use of a peripheral nerve stimulator. The use of an ultrasound will further increase accuracy by visualizing the nerve of interest and prove helpful in documentation of peripheral nerve location and anesthesia for the medical record. Blocks of the radial, ulnar, musculocutaneous and median nerves (RUMM blocks), retrobulbar, tibial/peroneal, pudendal, and psoas compartment are also commonly performed here at Angell Animal Medical Center.

The femoral and sciatic nerve blocks are performed in conjunction with one another for common procedures like TPLOs/TTAs/Lateral sutures or for fractures distal to the coxofemoral joint. The sciatic nerve is blocked peripherally at the level of the ischial tuberosity and the greater trochanter on the lateral aspect of the hind limb. Either pedal extension or flexion is considered an appropriate end point for the sciatic nerve stimulation. The femoral nerve is blocked at the most proximal aspect of the femoral triangle, as the femoral nerve exits the iliopsoas muscle. Stifle extension is considered the appropriate end point for femoral nerve stimulation. Careful analysis of which twitch is present is important to the success of these two blocks.

The brachial plexus block is performed on thoracic limbs for orthopedic procedures distal to the shoulder joint such as elbow arthroscopy, elbow wedge osteotomy, radius/ulna fracture repairs, and carpal arthrodesis. The brachial plexus is composed

of many different nerves that, when stimulated with a nerve stimulator, will elicit different responses. Careful analysis of which twitch is present is important to the success of the brachial plexus block.

In general, a combination of bupivacaine and dexmedetomidine is commonly used as anesthetic for these blocks, although other combinations may be used. These blocks will typically last between 18 and 24 hours. This timeframe allows the patient a comfortable recovery from anesthesia, typically without need for opioid therapy in the acute post-operative phase. Once the patient is fully recovered from anesthesia, oral medication, such as tramadol and NSAIDs, is typically used to manage pain for the next few days after the block subsides. This allows for opioid sparing, which will prevent side effects such as anorexia, constipation, vomiting, nausea, and dysphoria that may prolong recovery and hospital stay duration and potentially increase morbidity and mortality.<sup>5</sup> By using peripheral nerve blocks and avoiding epidurals and large doses of analgesics, patients are comfortable and cognizant and they are interactive with staff and owners. In addition, they are able to get up and move around on their own to eat, go outside and start rehabilitation, all of which help to speed the recovery process.

## REFERENCES

- 1 Lumb and Jones. *Veterinary anesthesia and analgesia* ed 4. Blackwell Publishing. Ames, Iowa. 2007, 5.
- 2 Barash et al. *Clinical Anesthesia* ed 6. Lippincott Williams and Wilkins. Philadelphia, Pennsylvania. 2009, 947-950.
- 3 Auroy Y, Narchi P, Messiah A, et al. Serious complications related to regional anesthesia: result of a prospective survey in France. 1997 *Anesthesiology* 87, 479-486.
- 4 Campoy and Read. *Small Animal Regional Anesthesia and Analgesia*. Wiley-Blackwell. Ames, Iowa. 2013, 7.
- 5 Rodgers A, Walker N, Schug S, et al. Reduction of postoperative morbidity and mortality with epidural or spinal anesthesia: result from overview of randomized trials. 2007 *BMJ* 321, 1-12.



VIEW ONLINE

For more information on Angell's Anesthesiology service, please visit [angell.org/anesthesia](http://angell.org/anesthesia). Dr. Barton-Lamb can be reached at 617-541-5048 or [anesthesia@angell.org](mailto:anesthesia@angell.org).



## Mammary Tumors in Dogs and Cats

■ Jennifer Mahoney DVM, DACVIM (Medical Oncology)

angell.org/oncology oncology@angell.org 617-541-5136

**W**hile the incidence of mammary gland tumors has been reduced in the United States by routine spaying of young female dogs and cats, these remain common and potentially aggressive tumors in our practice. However, the behavior of mammary gland tumors differs between the dog and cat. Approximately 50% of canine mammary tumors are malignant, versus approximately 90% of feline mammary tumors.

Most mammary tumors in both species are epithelial tumors, or carcinomas. Some canine tumors are of mesenchymal origin (sarcomas), while others are of mixed histology (carcinosarcomas, or mixed mammary tumors). In dogs, English springer spaniels, cocker spaniels and other small breeds appear to be at increased risk for mammary tumor development, while Siamese cats also have an increased incidence (and tend to develop mammary tumors at a younger age than other breeds).

Ovariohysterectomy status is a significant risk factor for the development of mammary tumors in dogs, and intact female cats are also overrepresented (by a factor of 7) among cats with mammary carcinoma. Estrogens regulate transcription of proto-oncogenes, and most canine mammary carcinomas express estrogen receptors. Spaying dogs before their 1st estrus significantly decreases the risk of mammary tumor development to less than 1%. The risk increases to 8% in dogs spayed before their 2nd estrus, and 26% in dogs spayed after their 2nd estrus. One study showed that cats spayed before 1 year of age also had a significantly decreased risk of development of mammary carcinoma: if spayed before 6 months, the risk of developing mammary carcinoma was 9%, versus 14% if spayed between 6 and 12 months of age and 89% if spayed between 13 and 24 months of age.

Mammary gland tumors may be detected at home by the owner, or may be found on routine physical exam. Tumors vary in size and

appearance, and some may appear ulcerated. In dogs and cats, the caudal mammary glands are affected more commonly than the cranial glands, but location does not seem to affect prognosis. Many dogs and cats present with more than 1 mammary tumor. Up to 50% of dogs may also present with enlarged lymph nodes. Staging for patients with mammary tumors should include a minimum database, aspirates of enlarged axillary and/or inguinal lymph nodes, and 3-view thoracic radiographs. For caudal mammary tumors, an abdominal ultrasound is also recommended to evaluate the medial iliac lymph nodes and internal organs.

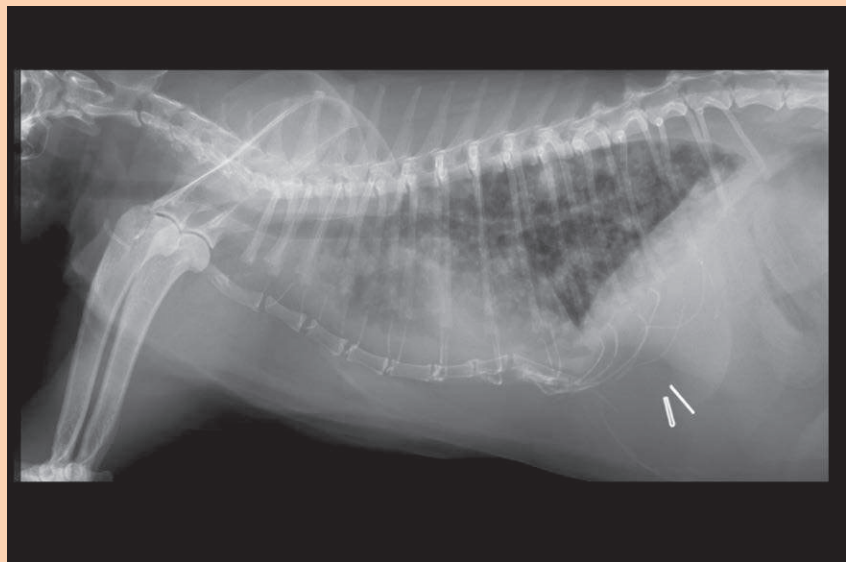
There are a variety of prognostic factors to predict outcome in both canine and feline mammary tumors. Tumor size is an important prognostic factor in both species. In dogs, tumors less than 3cm in diameter

are associated with prolonged survival versus larger tumors. In cats, tumor size is often considered the most important prognostic factor. Feline tumors less than 2cm in diameter are associated with a median survival time of over 3 years, versus 2 years for tumors 2-3cm in diameter and 6 months for tumors larger than 3cm in diameter. Stage is also important in both species, with both lymph node and distant (lung) metastasis associated with poor prognosis. Other prognostic factors in dogs include tumor type (carcinomas have a better prognosis than carcinosarcomas or sarcomas; inflammatory carcinomas, however, are associated with a grave prognosis); steroid hormone receptor status; and high indices of proliferation markers. Tumor grade is an important prognostic factor in both dogs and cats. Tumor grade is a measure of tumor differentiation, determined by level of tubule formation, nuclear and cellular pleomorphism, and mitotic index. Surgical approach also determines outcome in feline mammary tumors, with a longer disease-free interval reported for cats treated with chain mastectomy versus conservative excision.

In dogs, the type of surgery performed does not appear to influence survival as long as the entire tumor is removed with clean margins. Depending on the size of the tumor

FIGURE 1

▶ 14-year-old FS domestic short hair cat with metastatic mammary carcinoma approximately 8 months after bilateral staged chain mastectomies.



## REFERENCES

Jeglum, KA, deGuzman E, Young KM: Chemotherapy of advanced mammary adenocarcinoma in 14 cats, *J Am Vet Med Assoc* 187:157-160, 1985.

Mauldin GN, Matus RE, Patnaik AK, et al.: Efficacy and toxicity of doxorubicin and cyclophosphamide used in the treatment of selected malignant tumors in 23 cats, *J Vet Intern Med* 2:60-65, 1988.

McNeill CJ, Sorenmo KU, Shofer FS, et al.: Evaluation of adjuvant doxorubicin-based chemotherapy for the treatment of feline mammary carcinoma, *J Vet Intern Med* 23:123-129, 2009.

Overley B, Shofer FS, Goldschmidt MH, et al.: Association between ovariohysterectomy and feline mammary carcinoma, *J Vet Intern Med* 19:560-563, 2005.

Schneider R, Dorn CR, Taylor DO: Factors influencing canine mammary cancer development and postsurgical survival, *J Natl Cancer Inst* 43:1249-1261, 1969.

Sorenmo K. Canine mammary gland tumors, *Vet Clin Small Anim* 33:573-596, 2003.

Sorenmo KU, Worley DR, Goldschmidt MH. Tumors of the Mammary Gland, in *Withrow and MacEwen's Small Animal Clinical Oncology*, 5th ed, Elsevier 2013

VIEW ONLINE



If you have a patient with a mammary tumor, please feel free to contact the Angell Oncology service with questions on staging and treatment options:

**617-541-5136** or email at [oncology@angell.org](mailto:oncology@angell.org). You can also reach Dr. Mahoney at [jmahoney@angell.org](mailto:jmahoney@angell.org).

and/or presence of lymph node involvement, nearby mammary glands and nodes may also need to be removed. It is important to remember that the 1st and 2nd mammary glands drain to the axillary lymph nodes, while the 4th and 5th mammary glands drain to the inguinal lymph nodes. The 3rd mammary gland primarily drains to the axillary lymph node, but may also drain to the inguinal. For the most part, lymphatic drainage in the dog is ipsilateral, although there can also be drainage to contralateral nodes, especially with malignant mammary tumors. In cats, because of the potential for contralateral lymphatic drainage, the treatment of choice is a staged bilateral chain mastectomy, or at minimum a unilateral chain mastectomy for cats with unilateral tumors. Local recurrence has been reported in up to 50% of cats treated with conservative surgery.

There are few clinical studies evaluating the use of systemic treatment for mammary tumors, and despite the metastatic potential, the efficacy of chemotherapy is still debated. We recommend post-operative chemotherapy for dogs with high-risk mammary tumors (large tumor size, positive lymph nodes, high grade or other aggressive pathology characteristics). Doxorubicin, carboplatin, and oral metronomic protocols have all been used to treat canine mammary tumors with varying success. Cats with macroscopic mammary tumors or metastases have a 40-50% response rate to treatment with combination doxorubicin and cyclophosphamide. However, in a retrospective study evaluating the adjuvant use of a retro-agent doxorubicin in cats with tumors <2cm in diameter, survival time was shorter (15 months) than with surgery alone (3 years). A more recent study demonstrated improved survival in cats treated with chain mastectomy and adjuvant chemotherapy versus chain mastectomy alone (5.4 years vs. 13.8 months). Additional prospective studies are needed to determine the most appropriate use of chemotherapy for dogs and cats with mammary tumors. In our practice, we evaluate each case individually in an effort to develop the best treatment plan for each pet and its owner. Sometimes palliative care with pain medications and potentially antibiotics is most appropriate for patients with advanced, ulcerated mammary tumors.

## WELCOME TO ANGELL...


*Angell is pleased to welcome the following doctors to our team this month.*



■ Rob Daniel, DVM, DACVIM (Neurology)

Neurology Service, MSPCA-Angell West & Angell Boston

Dr. Rob Daniel joined Angell this month after completing his residency in neurology and neurosurgery at the University of Missouri. He hails from Canada where he received his DVM at the University of Guelph in 2010 and completed a rotating internship at the Veterinary Emergency Clinic and Referral Centre in Toronto in 2011. Dr. Daniel will provide consults at both MSPCA-Angell West in Waltham and at Angell in Boston, and perform procedures out of our Boston location.



■ Ivan Martinez, DVM, DACVIM (Medical Oncology and Internal Medicine)

Oncology Service, Angell Boston

Dr. Ivan Martinez joined Angell on September 2 after practicing in South Carolina at Upstate Veterinary Specialists in Greenville. He graduated from the University of Barcelona, College of Veterinary Medicine, Bellaterra, Spain in 1997 where he also completed an internship in Small Animal Medicine and Surgery in 2000. He completed a second rotating internship at the Ohio State University Veterinary Hospital in 2002 and went on to complete residencies in Internal Medicine (2005) and Oncology (2008) both at Michigan State University. He is double boarded in Small Animal Internal Medicine and Medical Oncology and will practice at Angell in Boston.



■ Virginia Sinnott, DVM, DACVECC

Emergency/Critical Care Service, Angell Boston

Dr. Virginia Sinnott is a graduate of Tufts University School of Veterinary Medicine and completed her Emergency and Critical Care residency at University of Pennsylvania, where she was the recipient of the Intern Mentor Award for outstanding teaching and mentoring. Dr. Sinnott is also a former recipient of the American Association of Feline Practitioners award for Outstanding Interest and Ability in Feline Medicine and Surgery.



## 2<sup>nd</sup> Intention Healing in Full-Thickness Skin Wound Management—Revisited

■ Michael Pavletic, DVM, DACVS

angell.org/surgery surgery@angell.org 617-541-5048

### OVERVIEW

Veterinarians rely on healing by 2<sup>nd</sup> intention (contraction and epithelialization) for a number of challenging wounds involving most body regions. Myofibroblasts are responsible for wound contraction or the centripetal advancement of the bordering skin. Epithelial cell migration in full-thickness skin wounds originates from the germinal epithelial layer (stratum basale) of the skin edges comprising the perimeter of the defect.

Wound contraction and epithelial cell migration occur independent of each other. Both processes are influenced by the cytokines (growth factors) released in the wound healing process, as well as the microenvironment created by the topical medication/dressing applied to the wound. Young dogs and cats, less than 6 months of age, can heal remarkably well by 2<sup>nd</sup> intention, primarily as a result of wound contraction alone.

It is important to note that most open wounds that heal by 2<sup>nd</sup> intention close primarily by wound contraction. From a cosmetic standpoint, this centripetal advancement of healthy skin covers the wound with normal hair-bearing skin. Cosmetically, wound areas that heal by epithelialization are largely devoid of hair follicles and are highly visible in fur-bearing animals, unless adjacent hair regrowth obscures their presence. Additionally, the epithelial layer is only a few cell layers thick and may lack the durability to sustain day-to-day normal “wear and tear.” With unstable scars, surgical resection and closure by skin stretching, skin advancement, skin flaps or free grafts would be necessary.

It must be noted that wound contraction normally peaks out by 42 days after its initiation. When wound contraction effectively ceases, any remaining open wound would require coverage by epithelialization. If a sizeable defect remains at this 6-week juncture of open wound management, the veterinarian must decide whether surgical closure would

be the best option for the patient versus prolonged wound care to promote epithelial cell migration.

### WOUND CLOSURE CONSIDERATIONS

When dealing with contaminated and infected wounds, a variable amount of open wound care is necessary to promote formation of a healthy granulation bed before considering potential wound closure options. Necrotic tissue, contaminants, and the resident bacterial population must be addressed with surgical and medical management. During this first week of open wound care, the veterinarian has time to assess the wound daily and formulate a plan on how best to close the wound. Healthy granulation tissue formation is a clear signal to the clinician that healing is underway and the underlying tissues are healthy enough to promote its development. Moreover, healthy granulation tissue forms a protective barrier to help blunt invasive infection. It is important to remember that, after acute injury, tissue swelling with elastic retraction of the traumatized skin margins actually exaggerates the wound size by 25-30% during the first week of trauma. As swelling recedes, typically after the first week of care, the veterinarian can more accurately assess the size of the wound.

Clinical experience is invaluable for determining whether a given challenging wound can heal by 2<sup>nd</sup> intention. The size and location of the open wound play a major role in determining whether contraction and epithelialization is a practical and realistic option to close a problematic skin defect. In general, moderate-sized wounds involving the trunk, and smaller problematic wounds involving the extremities, may be prime candidates for 2<sup>nd</sup> intention healing. For effective wound contraction, the skin around the perimeter of the wound should have a variable degree of mobility and elasticity. This is especially relevant when dealing with lower-

FIGURE 1A

⚡ Half the skin circumference of this cat's lower hind limb was lost to trauma. Healing by 2<sup>nd</sup> intention is unrealistic for this wound.

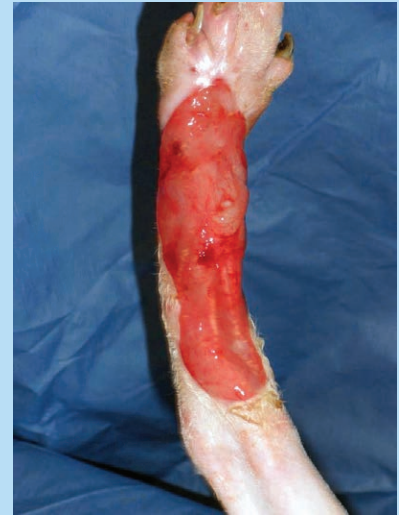
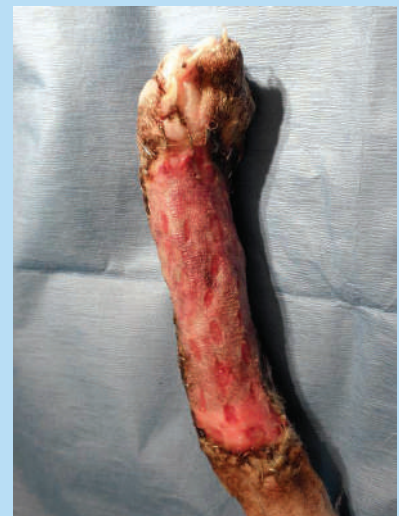
FIGURE 1B

⚡ A mesh graft was used to successfully close this defect.



extremity defects. Skin defects approaching 180 degrees of the limb circumference normally require reconstructive surgery in the form of skin grafts or flaps. Wounds that are closer to 90 degrees (or less) of the

FIGURE 2A

⚡ Chronic, fibrotic wound bed of several months duration. 2nd intention healing failed to close this wound.

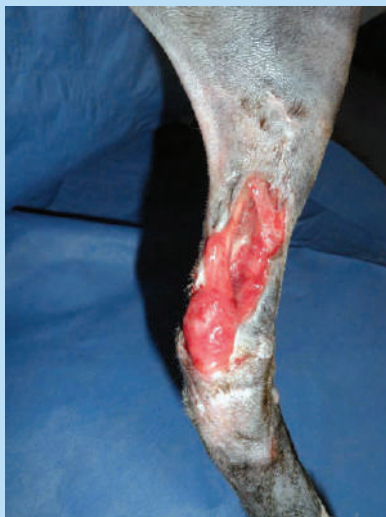
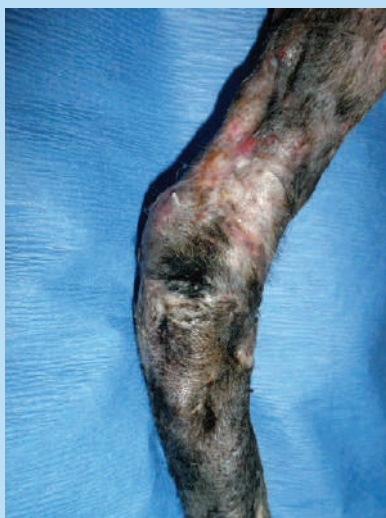
FIGURE 2B

⚡ Successful closure with a transposition flap and mesh graft combination.



circumference of the limb have a better chance at healing by 2nd intention (Figures 1 and 2).

FIGURE 3A

⚡ Area of surgical dehiscence, inner left thigh of a dog. The skin margins have yet to adhere to the granulation bed, thereby delaying the possibility of healing by second intention.

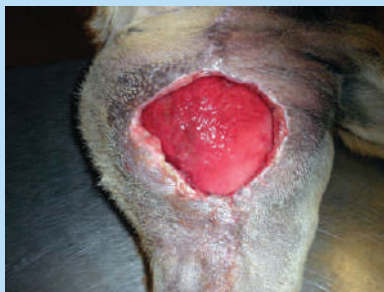
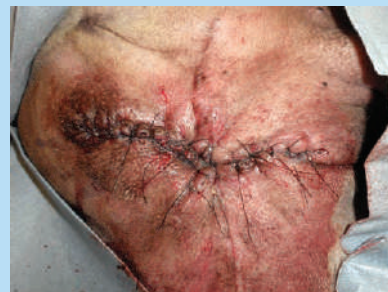
FIGURE 3B

⚡ Due to the delay in second intention healing and the problematic area of the wound, the skin was mobilized and the wound successfully closed.



### COMPLICATIONS OF 2ND INTENTION HEALING

The clinician must be alert to these common factors that delay or prevent wound contraction, including:

- Paucity of loose elastic skin for effective contraction (counter-tension)
- Restrictive scar tissue
- Unhealthy wound bed
- Poor regional circulation
- Repeated regional trauma
- Skin margins failing to attach to the underlying granulation bed\* (see Figure 3)

(\*The latter point is commonly overlooked by clinicians. A skin margin fully detached from the adjacent granulation bed over time will contract or curl under itself, with epithelial cells migrating over the underlying dermal border. A “pocket wound” forms, preventing normal 2nd intention healing. To promote effective contraction and epithelialization, the contracted skin border may require debridement followed by suturing the skin directly to the granulation bed. Once both surfaces adhere, 2nd intention healing can occur.)

For epithelialization to occur, a healthy, vascularized granulation wound bed is required. A chronic, fibrotic granulation bed is poorly suited to support this process. Survival and migration of epithelial cells are optimized by providing a moist, protective environment. A variety of wound dressings and topical

agents are available to help promote this healing process. A bandage is normally used to secure most dressings and protect the wound from trauma. In areas of motion, immobilization with a splint is advisable. Excessive motion may cause the bandage and dressing to rub on the wound, delaying or preventing 2nd intention healing.

Regional scarring and wound contraction can result in wound contracture, a disorder resulting in the relative loss of normal range of motion (primarily involving flexion surfaces of the body). When managing challenging wounds, part of the periodic wound examination is to identify the early presence of this pathologic process. In most cases, contracture management requires the use of skin grafts or skin flaps to close the defect after surgically dividing the restrictive scar bands.

### COMBINING 2ND INTENTION HEALING AND RECONSTRUCTIVE SURGERY

With those wounds that have potential to close by contraction and epithelialization, the veterinarian can opt out to “ride the wave of wound contraction” and see how far the wound can close over the following few weeks (Figure 4). Even if 2nd intention slows and falls short of wound closure, the wound normally is much smaller and surgical closure would be easier and more economical to perform.

Lower-extremity defects, secondary to trauma or surgery (e.g., tumor resection), can be closed primarily on a number of occasions

## REFERENCES

Pavletic M.M. (2010). *Atlas of Small Animal Wound Management and Reconstructive Surgery*. Wiley Blackwell, Ames, Iowa.

VIEW ONLINE



Mike Pavletic, DVM, DACVS, is the Director of Surgical Services at Angell Animal Medical Center. He is the author of the acclaimed *Atlas of Small Animal Wound Management and Reconstructive Surgery*, published in 2010 by Wiley Blackwell. For more information about Angell's Surgery service, please visit [angell.org/surgery](http://angell.org/surgery). To contact Angell's surgeons by phone or to refer a patient to the Angell Surgery service, please call 617-541-5048 or email [surgery@angell.org](mailto:surgery@angell.org). You can also reach Dr. Pavletic at [mpavletic@angell.org](mailto:mpavletic@angell.org).

FIGURE 4A

⌵ Burn eschar, dorsal lumbar area of a cat. This was determined to be a partial and full-thickness burn. Conservative management was initiated, including partial surgical debridement of loose mummified skin followed by topical silver sulfadiazine ointment.

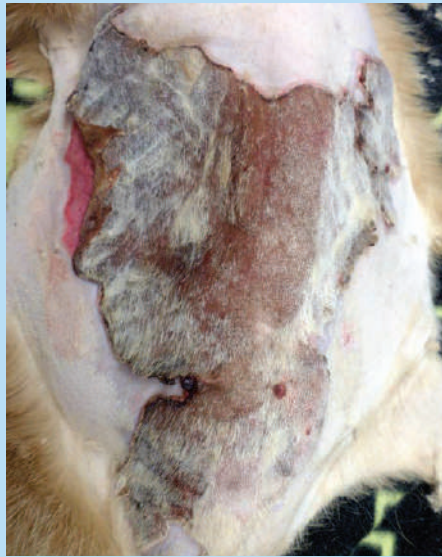
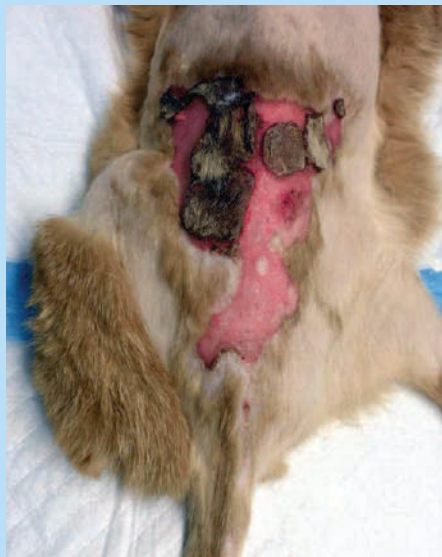
FIGURE 4B

⌵ Serial debridement and open wound management, week 4. Note the remarkable decrease in the size of this full-thickness wound, secondary to wound contraction. Partial thickness burned areas quickly re-epithelialized from survival of the compound hair.



with the use of release/relaxing incisions and local skin flaps. In essence, tension-relieving incisions allow closure of a problematic wound while relying on 2nd intention healing to close the incisional (donor) defects created to mobilize the skin. Another option to facilitate closure of a smaller, problematic lower-extremity wound is the use of a small pedicle graft to partially close the defect. A small transposition flap can be developed, not to close the entire wound of the lower extremity, but to close the central portion of the wound. The skin flap essentially closes a major portion of the defect while creating 2 smaller open wounds that can heal more effectively (and faster) by 2nd intention healing.

## FINAL COMMENTS

Advances in reconstructive surgery, including the use of skin flaps, free grafts and skin stretching, enable surgeons to close challenging wounds quickly and effectively. The advantages of primary closure include rapidly returning function to the patient, reducing discomfort associated with prolonged open wound care, and eliminating the cumulative costs and time associated with multiple bandage changes and hospital visits. These advantages are weighed against the costs of surgery and anesthesia. Second intention healing can be an effective option for open wounds, provided that the wound size and location are conducive to this healing process. The veterinarian can always consider surgical closure if contraction and epithelialization slow or fail to close the wound adequately. Combining 2nd intention healing with surgical closure, as noted, also can be a very effective option to consider for challenging wounds.

## STAFF DOCTORS

■ We encourage you to email Angell's specialists with questions.

Main Phone: 617-522-7282 (Boston), 781-902-8400 (Waltham) Veterinary Referrals: 617-522-5011

**CHIEF OF STAFF**

**Ann Marie Manning, DVM, DACVECC**  
amanning@angell.org

**\*24/7 EMERGENCY & CRITICAL CARE**

**Charles Amuguni, DVM**  
camuguni@angell.org

**Lauren Baker, DVM**  
lbaker@angell.org

**Kiko Bracker, DVM, DACVECC**  
kbracker@angell.org

**Emily Finn, DVM**  
efinn@angell.org

**Jessica Hamilton, DVM**  
jhamilton@angell.org

**Roxanna Khorzad, DVM**  
rkhorzad@angell.org

**Megan Krauth, DVM**  
mkrauth@angell.org

**Tamara Kremer Mecabell, DVM**  
tmecabell@angell.org

**Virginia Sinnott, DVM, DACVECC**  
vsinnott@angell.org

**Catherine Sumner, DVM, DACVECC**  
csumner@angell.org

**Megan Whelan, DVM, DACVECC**  
mwhelan@angell.org

**ANESTHESIOLOGY**

**Ashley Barton-Lamb, DVM, CVA**  
abartonlamb@angell.org

**\*AVIAN & EXOTIC MEDICINE**

**Brendan Noonan, DVM, DABVP**  
(Avian Practice)  
bnoonan@angell.org

**Elisabeth Simone-Freilicher, DVM, DABVP**  
(Avian Practice)  
esimonefreilicher@angell.org

**BEHAVIOR**

**Terri Bright, Ph.D., BCBA-D**  
tbright@angell.org

**\*CARDIOLOGY**

**Nancy Laste, DVM, DACVIM**  
(Cardiology)  
nlaste@angell.org

**Rebecca Malakoff, DVM, DACVIM**  
(Cardiology)  
rmalakoff@angell.org

**Rebecca Quinn, DVM, DACVIM**  
(Cardiology and Internal Medicine)  
rquinn@angell.org

**DENTISTRY**

**William Rosenblad, DVM**  
wrosenblad@angell.org

**\*DERMATOLOGY**

**Klaus Loft, DVM**  
keloft@angell.org

**Ursula Thomas, DVM, DACVD**  
uthomas@angell.org

**Meghan Umstead, DVM**  
mumstead@angell.org

**DIAGNOSTIC IMAGING**

**Rebecca Manley, DVM, DACVR**  
rmanley@angell.org

**Joan Regan, VMD, DACVR**  
jregan@angell.org

**Steven Tsai, DVM, DACVR**  
stsai@angell.org

**\*INTERNAL MEDICINE**

**Doug Brum, DVM**  
dbrum@angell.org

**Maureen Carroll, DVM, DACVIM**  
mccarroll@angell.org

**Erika de Papp, DVM, DACVIM**  
edepapp@angell.org

**Jean Marie Duddy, DVM**  
jduddy@angell.org

**Kirstin Johnson, DVM, DACVIM**  
kcjohnson@angell.org

**Shawn Kearns, DVM, DACVIM**  
skearns@angell.org

**Susan O'Bell, DVM, MPH, DACVIM**  
sobell@angell.org

**Cynthia Talbot, DVM**  
ctalbot@angell.org

**\*NEUROLOGY**

**Rob Daniel, DVM, DACVIM (Neurology)**  
rdaniel@angell.org

**Allen Sisson, DVM, MS, DACVIM**  
(Neurology)  
asisson@angell.org

**NUTRITION**

**Dana Hutchinson, DVM, DACVN**  
dhutchinson@angell.org

**ONCOLOGY**

**Lyndsay Kubicek, DVM, DACVR**  
(Radiation Oncology)  
lkubicek@angell.org

**Jennifer Mahoney, DVM, DACVIM**  
(Medical Oncology)  
jmahoney@angell.org

**Ivan Martinez, DVM, DACVIM**  
(Medical Oncology and Internal Medicine)  
imartinez@angell.org

**Carrie Wood, DVM, DACVIM**  
(Medical Oncology)  
cawood@angell.org

**OPHTHALMOLOGY**

**Daniel Biros, DVM, DACVO**  
dbiros@angell.org

**Martin Coster, DVM, MS, DACVO**  
mcoster@angell.org

**PAIN MEDICINE**

**Lisa Moses, VMD, DACVIM, CVMA**  
lmoses@angell.org

**PATHOLOGY****(CLINICAL & ANATOMIC)**

**Patty Ewing, DVM, MS, DACVP**  
pewing@angell.org

**Pamela Mouser, DVM, MS, DACVP**  
pmouser@angell.org

**\*SURGERY**

**Sue Casale, DVM, DACVS**  
scasale@angell.org

**Michele Kudisch, DVM, DACVS**  
mkudisch@angell.org

**Michael Pavletic, DVM, DACVS**  
mpavletic@angell.org

**Meghan Sullivan, DVM, DACVS**  
msullivan@angell.com

**Nicholas Trout, MA, VET MB, MRCVS,**  
**DACVS, DECVS**  
ntrout@angell.org

\*Services also available at our  
Waltham location.



Nonprofit Org.  
US Postage  
PAID  
Permit No. 1141  
Boston, MA

We mail one complimentary copy of our newsletter to each of our referring partners. Please circulate this copy within your practice.

Fall 2014 ■ Volume 8:3 ■ [angell.org](http://angell.org) ■ [facebook.com/AngellReferringVeterinarians](https://facebook.com/AngellReferringVeterinarians)

MSPCA-ANGELL

350 South Huntington Avenue  
Boston, MA 02130  
617-522-5011  
[angell.org](http://angell.org)

MSPCA-ANGELL WEST

293 Second Avenue  
Waltham, MA 02451  
781-902-8400  
[angell.org/waltham](http://angell.org/waltham)

Please consider adding Angell's main numbers to your after-hours phone message.

■ [angell.org/directions](http://angell.org/directions) (free parking) ■ [angell.org/hours](http://angell.org/hours) ■ [angell.org/ce](http://angell.org/ce)

## NEUROLOGY SERVICE NOW AVAILABLE AT ANGELL WEST

Our Waltham location features board-certified specialists and criticalists working in close collaboration with our Angell-Boston team to provide a spectrum of services for your clients and patients. Come visit our new facility!

Please call **781-902-8400** to book appointments or referrals, or visit [angell.org/waltham](http://angell.org/waltham) for a full list of expanding Waltham services.

*MSPCA-Angell West hospital services currently include...*

24/7 EMERGENCY & CRITICAL CARE

AVIAN & EXOTIC MEDICINE

CARDIOLOGY

DERMATOLOGY

INTERNAL MEDICINE

NEUROLOGY

SURGERY