

BARTONELLA	CANINE CUTANEOUS MAST CELL TUMOR	FELINE TOOTH RESORPTIONS	LEPTOSPIROSIS	CARDIOVASCULAR EFFECTS OF SYSTEMIC HYPERTENSION IN CATS	HEALTHY INTERACTION BETWEEN JUVENILE PET BIRDS AND VETERINARY PROFESSIONALS
					
PAGE 1	PAGE 1	PAGE 3	PAGE 6	PAGE 8	PAGE 10

INTERNAL MEDICINE



Bartonella

■ Maureen C. Carroll DVM, DACVIM

angell.org/internalmedicine
internalmedicine@angell.org
617-541-5186

As veterinarians, we are expected to be experts in the field of infectious disease. As a result, we must now become learned in more and more infectious organisms that not only affect our veterinary patients but can also infect the human counterparts with whom these animals are associated. Flea and tick-borne diseases are at the center of our attention as veterinarians, and our knowledge of *Bartonella* is evolving rapidly. Although much has been learned about this organism in the past two decades, years of research are likely necessary to fully understand the spectrum of its pathogenicity.

Bartonella was originally isolated from an HIV-infected person, and was first diagnosed in a dog (1993) diagnosed with endocarditis. In general this organism is now known to be associated with cases of endocarditis and myocarditis, granulomatous disease, chronic intravascular infection, and vasoproliferative disorders in humans and animals.

Today there are 32 named and many other unnamed species of *Bartonella*. Among the many species, we do know that *B. henselae* and *B. clarridgeiae* can be pathogenic in cats; *B. vinsonii (berkhoffii)* and *B. clarridgeiae* in dogs. Exposure to these serovars can be found throughout most of the United States and the world.

(CONTINUED ON NEXT PAGE)

ONCOLOGY



Canine Cutaneous Mast Cell Tumors: Updates in Grading, Prognostic Markers, and Therapy

■ Ivan Martinez, DVM, DACVIM (Internal Medicine and Medical Oncology)

angell.org/oncology
617-541-5136
oncology@angell.org

Mast cell tumors (MCTs) are the most common cutaneous tumor in dogs, representing around 16-21% of all skin tumors, and may occur as solitary nodules or multiple masses.¹ Mast cell tumors may also present at non-cutaneous sites, including a visceral form affecting liver, spleen, abdominal lymph nodes, bone marrow, or the gastrointestinal tract. Overall, MCTs have an extremely wide range of clinical appearances, with varied biologic behavior and prognosis, and therefore therapy is not uniform for all and must be tailored to the specific situation of each individual patient. This can add to confusion when discussing the various treatment options with pet owners.

For the particular case of cutaneous MCTs, multiple factors can help us predict biologic behavior and therefore guide our therapeutic recommendations. The most consistent and reliable of such factors is the tumor grade, which only can be determined from histopathology (not cytology) and therefore requires removal or biopsy of the tumor. Historically MCTs are divided into 3 different grades (I-II-III or low-intermediate-high based on Bostock and Patnaik grading systems), where low-grade MCTs are relatively non-aggressive with a low chance of metastasis (<10-20%), high-grade MCTs are aggressive and have a metastatic potential of 55-96%, and intermediate-grade (or grade II) MCTs are a "gray area," where some behave

(CONTINUED ON PAGE 4)

INTERNAL MEDICINE

Bartonella is a very fastidious gram negative rod that remains in a mammalian host as an intraerythrocytic and interendothelial bacteria, and can remain so for a prolonged period of time. Other cell targets for this organism include: microglial cells, macrophages, and CD34 bone marrow progenitor cells, which may play a role in cytopenias we can observe with *Bartonella* (humans and dogs).

TRANSMISSION

Bartonella spp is transmitted by more vectors than any other infectious agent: ticks, sandflies, human lice, cat fleas, rodent fleas, and horn flies. In cats *Bartonella* is found most frequently in flea-infested animals; in dogs the tick is the usual vector of transmission, although fleas are also a vector. In flea endemic areas, seroprevalence in cats can be as high as 90%; bacteremia rates 50% and greater. As this organism can live in flea dirt for >9 days, year-round flea control is very important. Transmission between animals and humans can occur via scratch with a claw contaminated with flea dirt, or via open wounds in contact with flea dirt, or from biting or licking from infected animals.

BARTONELLA IN CATS

Although controlled studies in cats are limited, our knowledge continues to evolve. *Bartonella henselae* lives in the cat flea. Cats infested with fleas are 40% more likely to be *Bartonella* positive on serology or PCR than cats without fleas. Alternatively, there is a high prevalence rate in non-clinical carriers in the general cat population, thereby hindering our ability to establish disease causation, regardless of flea status.

Although we often associate *Bartonella* with endocarditis and myocarditis, these manifestations are usually observed in research settings in cats. Cats who present with clinical signs associated with naturally acquired *Bartonella* usually suffer from fever and lymphadenopathy, lethargy, uveitis, gingivitis, and sometimes neurological symptoms. If one examines a patient with these symptoms that is flea-infested, *Bartonella* should be on the list of differentials.

Interestingly, *Bartonella* in cats usually does not result in any biochemical or hematological abnormalities.

BARTONELLA IN DOGS

Although the full spectrum of disease manifestations in dogs is unclear, we do know that human bartonellosis mimics what we see

in dogs. *B. vinsonii* in dogs can cause chronic intraerythrocytic and intraendothelial infections that can result in vasoproliferative disease, in addition to endocarditis (Boxers over represented), myocarditis, peliosis hepatis, granulomatous disease, granulomatous hepatitis, lymphadenitis, rhinitis, epistaxis, encephalitis, skin lesions, vasculitis, panniculitis, polyarthritis, uveitis, and meningitis, among others. Sometimes dogs can present with only fever of unknown origin and epistaxis.

Hematologically, monocytosis and eosinophilia can be observed in ~1/3 of dogs; thrombocytopenia in ~50%, and anemia is also common. As in cats, biochemical abnormalities are uncommon.

DIAGNOSIS

As a rule of thumb for the diagnosis for any disease: A “positive” result on a blood test or a culture does not necessarily prove causation for disease. We can observe false positive and false negative results in both bacteremic and non-bacteremic patients.

Dogs: Serology for antibodies to *B. vinsonii* (*berkoffii*) is a very specific test, as <4% of sick dogs are seropositive. Therefore, a positive is indication of exposure and/or active disease and should be treated. Because the sensitivity of antibody detection is so low, combined testing is recommended for dogs. The tests of choice are a combination of 1. and 2. below:

1. PCR (blood)
2. BAPGM culture (insect medium) on blood

Cats: Testing should be reserved for cats with suspected clinical disease due to prevalence of subclinical carrier state in this species.

Serology for antibody detection in cats can be useful for determining exposure; however, due to the carrier state, its usefulness as a sole test is questionable. PCR on whole blood for DNA detection, however, is often positive before seroconversion occurs, so using this diagnostic in addition to serology will be of better diagnostic utility in sick cats. Culture on blood can also be performed in lieu of PCR.

Therefore, testing of choice in cats is a combination of 1. and 2. below:

1. PCR or BAPGM culture on blood
2. Serology for antibody detection (blood)

Sample submissions for all *Bartonella* testing can go to Galaxy Laboratories or Colorado State University:

www.galaxylaboratories.com
csu-cvmb.colostate.edu

TREATMENT

Azithromycin is no longer recommended, as *Bartonella* develops rapid resistance to this drug.

The recommended therapy includes Doxycycline 10 mg/kg po/12-24 combined with a fluoroquinolone for 4-6 weeks.

Doxycycline as a sole therapeutic will not clear most *Bartonella* infections.

PUBLIC HEALTH

Bartonella spp can be transmitted to dogs, cats, and humans via flea or tick bites, or via the bite, lick, or scratch from a bacteremic animal. Infected flea dirt in the mouths, fur, or nails of animals are also risk factors to humans. Flea and tick control is therefore imperative in preventing transmission of this organism to humans. As mentioned earlier, the human disease manifestations are very similar to the canine, and therefore can result in significant morbidity to the human population, veterinarians most importantly! Any fluid—blood, body cavity, joint, cerebrospinal fluid, etc.—from an infected animal can harbor live organisms. Proper and safe specimen handling at all times is of paramount importance among those in the veterinary community.

For more information, please contact Angell's Internal Medicine service at **617-541-5186** or internalmedicine@angell.org.



Feline Tooth Resorptions

■ William Rosenblad, DVM

angell.org/dentistry
dentistry@angell.org
617-524-5643

Feline tooth resorptions are a progressively destructive disease of cat teeth. They have been previously known as resorptive lesions, FORL (Feline Odontoclastic Resorptive Lesions), neck lesions, and cervical line lesions and are sometimes inappropriately called “feline cavities.” They are very common (research studies estimate that as many as 65% of domestic cats are affected). I generally expect that every cat will be affected, until I can prove otherwise with dental radiographs. There is no known etiology. These lesions can affect any teeth.

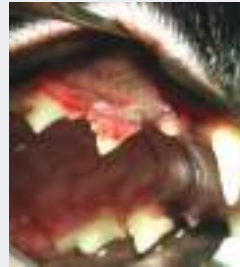The lesions of the premolars and molars usually begin along or just below the gingiva and may first be noticed as gingival hyperplasia grows into the defect in the tooth. (Fig. 1) Any tooth or gingival damage at the normal gingival margin predisposes that tooth to plaque and calculus buildup; teeth affected by these lesions often have more periodontal disease. (Fig. 2) These diseased teeth are eventually lost, sometimes leaving behind infected roots. The canine teeth are more commonly affected along the root, below the gingival margin. When these teeth are affected, the bone around the root becomes inflamed. This can often be seen as a supra-gingival swelling. Sometimes these teeth seem to “grow” or become longer, sometimes referred to as super-eruption (I prefer the term extrusion). (Fig. 3) This happens because the bone surrounding the tooth root weakens as it becomes inflamed. The bony separation is usually noticeable on dental radiographs. (Fig. 4) Eventually the tooth is completely loosened and falls out, leaving an open, infected, inflamed socket. Other times, the root is resorbed enough that the top, or crown, of the tooth falls off, appearing to have broken off. When this type of lesion occurs, the tooth root will appear striated or wispy and less radio-opaque. (Fig. 5) Quite often, when the incisors are affected, so are the canines, and vice versa.

These lesions can be very painful (cats have more nerve endings in their teeth than humans) and the secondary periodontal disease may cause more pain and potentially affect other areas of the body. Signs that may be seen with these lesions are decreased dry food chewing, vomiting (especially of undigested food), chewing more on one side of the mouth, halitosis, and decreased grooming. Acute, painful malocclusions can occur when teeth weakened by tooth resorptions luxated and occlude abnormally with the opposing teeth. (Fig. 6) “Chattering” (movement of the lower jaw, or other local twitching) can often be elicited by palpation of the affected teeth. Attempts to repair or treat these lesions have been generally unsuccessful. The current recommended treatment is extraction of the affected teeth or any problematic root remnants.

Pet owners often ask how their cats will chew with fewer teeth. The answer is often “better!” after the painful, diseased teeth are removed. Once the gingival tissue heals, it can be quite tough and most cats resume eating dry food after these affected teeth are extracted.

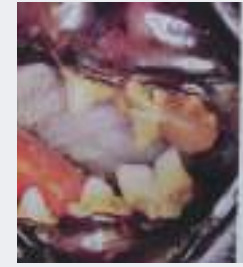For more information, please contact Dr. Rosenblad at dentistry@angell.org or 617-524-5643.

FIGURE 1



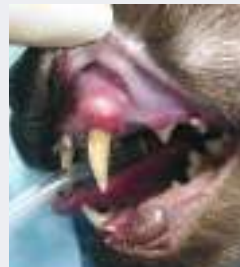↘ Gingival hyperplasia (gum proliferation) secondary to a Resorptive lesion of the upper 3rd premolar in a cat.

FIGURE 2



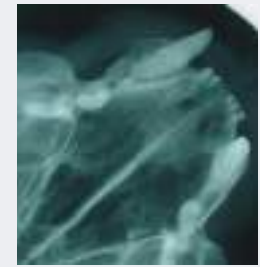
↘ Significant calculus buildup on the upper 4th premolar tooth and gum recession of the lower 1st molar tooth (note the “hole” in the root, which is actually just the exposed area between the two roots), secondary to Resorptive lesions in a cat.

FIGURE 3



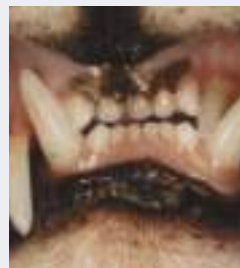↘ Supra-gingival (above the gum line) swelling with secondary gum recession of the upper canine tooth in a cat. This swelling is actually the bone around the tooth root becoming inflamed due to the Resorptive lesion process.

FIGURE 4



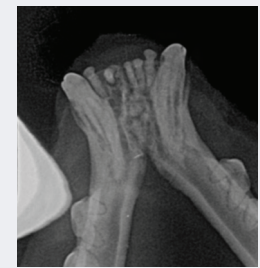↘ This radiograph shows the significant swelling/inflammation of the bone secondary to the Resorptive process along the root of the upper canine tooth. Compare to the normal bone of the other upper canine tooth.

FIGURE 5



↘ Deviated upper left canine tooth, digging into gum of lower canine tooth. This tooth has shifted as the inflamed bone around its root from the Resorptive lesion process is weak and allows the tooth become loose.

FIGURE 6



↘ The slightly less common version of Resorptive lesions of cats' canine teeth in which the root structure is resorbed (the wispy look to the tooth roots). Eventually, the crown falls off of the tooth, often leaving exposed (and painful!) root remnants.

Continued from page 1

FIGURE 1

▾ Mast cell tumor in the muzzle of a dog.



in a benign manner and some are more malignant. Since grade II tumors represent the vast majority of MCTs, accounting for up to 80%, predicting their biologic behavior sometimes can be difficult. Recently, a new two-tier grading scheme was proposed by Kiupel et al, in which cutaneous MCTs are divided into either low-grade or high-grade, without an intermediate category.² This is done based on factors such as the mitotic index, presence of multinucleated cells, and bizarre or large nuclei. This two-tier system appears to better correlate with biologic behavior than the previous methods, and it is becoming more frequently used by pathologists, who usually describe grade based on both the new and old systems in histopathology reports. This may help predict prognosis better for some MCTs and help us make therapeutic recommendations.

The mitotic index of the tumor (MI = number of mitotic figures counted in 10 high-power microscope fields) used as a single factor has also been shown to be prognostic, with a median survival time of over 70 months for MCTs with an MI of 5 or less, vs. 3 months if the MI is higher than 5.³ This is a useful marker as it should be reported in all histopathology reports and there is no need to perform special stains to evaluate it.

Some clinical features with prognostic importance include the anatomic location of the tumor as well as its size and growth rate. Tumors

in the prepuccial/inguinal/scrotal area, subungual (nailbed) region, muzzle, and other mucocutaneous sites, including the oral cavity and perineum, have been associated with aggressive behavior. Likewise, large and rapidly growing MCTs, and those causing systemic signs (i.e. anorexia, vomiting, melena), are more commonly associated with a guarded prognosis.

Finally but importantly, another useful aspect to evaluate prognosis for some MCTs are special stains (immunohistochemistry) for proliferation markers (Ki67 and AgNOR) and the receptor tyrosine kinase “KIT,” and PCR to detect activating mutations of KIT, which occur in 20-40% of MCTs. These tests are performed out of tissue samples (biopsy or tumor removal), either individually or more useful as a packet (often referred to as a “Mast Cell Tumor Prognostic Panel”), and are becoming more commonly used in clinical practice. This is offered among others by Michigan State University and available through many commercial laboratories. If a particular laboratory does not directly offer the test, it is often possible to request unstained slides or a tissue block from the tumor to submit directly to the preferred laboratory. Test results often take 2-3 weeks to return, and there is additional cost associated on top of the initial histopathology fee. Of these markers, KIT holds special importance. KIT can be evaluated both by immunohistochemistry to analyze its pattern of expression (1, 2, or 3 based on membrane, focal/stippled, or diffuse cytoplasmic staining), or by PCR to detect mutations of exons 8 and 11 of c-Kit. Dogs with KIT pattern 2 and 3 may have lower disease-free survival time and overall survival time compared to those with expression pattern 1.⁴ In addition, MCTs with c-Kit mutations have shown a shorter disease-free survival time than those without a c-Kit mutation. MCTs with high proliferation activity (Ki67 and AgNOR) have been associated with a worse prognosis and decreased survival times. This panel is particularly useful in two situations:

- For intermediate-grade mast cell tumors where a decision needs to be made on the use of only local therapy (surgery +/- radiation), vs. the need for follow-up systemic chemotherapy if results of the panel are consistent with a more aggressive tumor.
- In the case of aggressive MCTs, to help us choose the best chemotherapy option. This is due to the fact that MCTs with aberrant KIT expression (patterns 2 and 3) or those with c-Kit mutations are more likely to

respond to targeted therapy with tyrosine kinase inhibitors, rather than traditional chemotherapy, as discussed below.

Treatment of cutaneous MCTs often involves local therapy with surgery to remove the tumor/s, plus radiation therapy if wide margins cannot be obtained. For unresectable MCTs, radiation may be used as the main local treatment modality. In addition, for “high-risk” MCTs, as determined by the presence of lymph node or internal metastasis, certain anatomical locations, or high histologic grade, systemic therapy may also be recommended. This involves chemotherapy, corticosteroids, and in recent years the use of tyrosine kinase inhibitors (TKIs). This latter class of drugs are oral small molecules that inhibit signaling through KIT (among other receptors), and therefore are of particular interest in MCTs with KIT dysregulation. There are two veterinary-approved TKIs, Toleranib (Palladia, Pfizer) and Masitinib (Kinavet/Masivet, AB Science). Palladia is a fully approved drug, while Kinavet currently has conditional approval only for non-resectable or recurrent, grade II or III MCTs that have not received any prior radiation or chemotherapy (prednisone is okay). In clinical studies Palladia has demonstrated efficacy against recurrent or metastatic intermediate or high-grade MCTs, with partial and complete responses in 42.8% of dogs (60% if stable tumors included), and up to 69% response in MCTs with KIT mutations.⁵ Masitinib has also shown long-term disease control in dogs with nonresectable MCTs.⁶ Both of these drugs are currently used at Angell as part of the armamentarium to treat MCTs.

For more information, please contact Angell Oncology Service **617-541-5136** or e-mail oncology@angell.org. You can also reach Dr. Martinez at imartinez@angell.org.

Continued from page 4

REFERENCES

- 1 London CA, Thamm DH. Mast cell tumors. In Withrow SJ, Vail DM, Page RL, editors: *Withrow and McEwen's Small Animal Clinical Oncology*, ed 5, St. Louis, 2013, Elsevier-Saunders.
- 2 Kiupel M, Webster JD, Bailey KL, et al. Proposal of a 2-tier histologic grading system for canine cutaneous mast cell tumors to more accurately predict biologic behavior, *Vet Pathol* 48:147-155, 2011
- 3 Romansik EM, Reilly CM, Kass PH, et al. Mitotic index is predictive for survival for canine cutaneous mast cell tumors, *Vet Pathol* 44:335-341, 2007.
- 4 Webster JD, Kiupel M, Kaneene JB, et al. The use of KIT and tryptase expression patterns as prognostic tools for canine cutaneous mast cell tumors, *Vet Pathol* 41:371-377, 2004.
- 5 London CA, Malpas PB, Wood-Follis SL, et al. Multi-center, placebo-controlled, double-blind, randomized study of oral toceranib phosphate (SU11654), a receptor tyrosine kinase inhibitor, for the treatment of dogs with recurrent (either local or distant) mast cell tumor following surgical excision, *Clin Cancer Res* 15:3856-3865, 2009.
- 6 Hahn KA, Legendre AM, Shaw NG, et al. Evaluation of 12- and 24-month survival rates after treatment with masitinib in dogs with nonresectable mast cell tumors, *Am J Vet Res* 71:1354-1361, 2010.

ANGELL IMAGE
TRANSFER EXPRESS

Angell Animal Medical Center is pleased to announce Angell Image Transfer Express for both our Boston and Waltham locations. Referring veterinarians now can send diagnostic images to images@angell.org which automatically feeds the images into Angell's new central repository for transferred diagnostic images. This is not for online imaging consultations or fee-based radiograph interpretation. This repository makes images quickly and easily retrievable by all Angell clinicians, avoids confusion over where to send images, and prevents the need to resend images when multiple specialists collaborate on a case.

IMAGES@ANGELL.ORG

Please email images to images@angell.org and to include in the email subject line (in this order)

- the PATIENT'S FIRST NAME (in all caps)
- the owner's first and last name
- a 1-3 word description
- the Angell doctor's last name

EXAMPLE:

"FIDO, Bob Smith, lung tumor, Martinez"

Referring clinicians may cc other applicable email addresses (e.g. the Angell clinician's direct email, the service email such as "oncology@angell.org," etc.), but images@angell.org must be included.

For more information, please contact a client liason at 617-522-7282.

COMPLIMENTARY CALL SERVICE
& EMERGENCY REPORTING

ANGELL DIRECT CONNECT PROGRAM

We are pleased to offer our Angell Direct Connect after-hours call service to referring partners. This free service expedites your clients' ability to reach a live operator during an emergency and promptly provides you with call information to keep you informed of your patients' needs.

This program enables better service for both you and your clients in the following ways:

- 🐾 Client does not need to hang up the phone after receiving the voice message at your practice; instead, they can just press a number and connect to Angell Boston.
- 🐾 Live person answers the phone to immediately assist your client (no phone tree).
- 🐾 The morning reporting information we provide to you, the referring doctor, allows you to preemptively reach out to your client the following day.
- 🐾 The information will provide you with statistics regarding after-hours call volume for your practice and demand for services.

To sign up for this program, please call Mary Grace at 617-541-5181.



Leptospirosis

■ Kiko Bracker, DVM, DACVECC
angell.org/emergency 617-522-7282

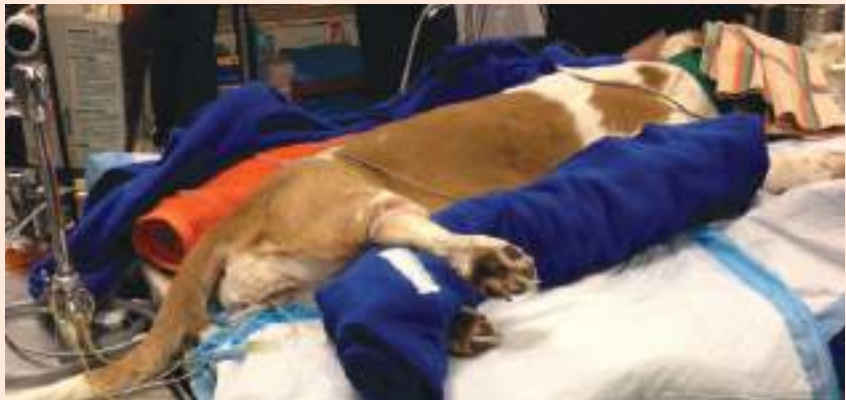Leptospirosis is a bacterially caused disease that commonly affects the kidney and the liver. The causative organism is motile spirochete (*Leptospira*) that can affect a wide array of mammals including dogs, humans, rarely cats, and a range of wildlife. Although there are well over 100 pathogenic serovars of Leptospirosis that are adapted to different hosts^{1,2}, the most commonly identified serovars found in the United States include Icterohemorrhagiae, Canicola, Pamona, Bratislava, Grippotyphosa and Hardjo. Leptospirae are shed in the urine of infected individuals, and the bacterium can persist in the environment in moist areas of limited sunshine. Infection occurs when the oral, ocular, or nasal mucous membranes of susceptible animals contact the bacteria in free standing water, vegetation, urine-contaminated soil, or other similar settings. Infection likely can also be spread by direct contact with infected individuals through grooming, fighting, or consumption. Since urbanized wildlife (raccoons, skunks, coyotes, rodents, etc.) may carry and shed leptospirosis, even animals that do not venture into more rural settings should be considered potentially at risk. The late summer and early fall show a spike in leptospirosis cases nationwide, but it can be seen year-round and it tends to be more prevalent in warmer, wetter climates. Hawaii has the most human cases in the United States.¹

PREVENTION

A tetravalent vaccination for leptospirosis is available in North America that includes the serovars Icterohemorrhagiae, Canicola, Pamona, and Grippotyphosa. Immunity lasts for at least 12 months. Vaccination breaks allowing vaccinated dogs to develop naturally occurring infections are not well documented. If clinical disease does develop despite vaccination, then it likely would be mild.² There has been some anecdotal concern that the leptospirosis vaccine results in a greater frequency of anaphylactoid reaction among small breed dogs. A larger study of vaccine reactions from 2005 did not show a greater risk with this

FIGURE 1

↘ Recumbent female dog with urinary catheter in place.



vaccine.³ Some owners may elect not to vaccinate their dogs for leptospirosis since they are not considered 'at risk'. The routine vaccination of all dogs, though, is generally recommended. We have seen clinical leptospirosis in small breed dogs coming from an urban/suburban setting, suggesting that our assessment of what 'at risk' means may need updating.

DIAGNOSIS

Leptospirosis can prove to be a diagnostic frustration. The most common diagnostic test is the microscopic agglutination test or MAT that is commonly referred to as 'lepto titers'. MAT results are often negative during the first week of illness.¹ This test can take 7 days for a final result and it is significantly affected by prior vaccination with vaccine induced titers which are usually less than or equal to 1:800, but up to 1:3200 can be seen 2-4 weeks post vaccination.⁴ Titers of greater or equal to 1:800 or a fourfold titer increase in 2-4 week convalescent titers often suggest infection.⁸ Clearly there is some significant overlap between vaccine induced titers and infection titers. Generally, it has been thought that the highest serovar titer reflects the serovar of

infection, but that is only true in about 50% of cases (human data).⁵ The absence of a convincing serologic diagnosis should not prevent appropriate treatment if the clinical picture strongly supports a diagnosis of leptospirosis.

Paired PCR tests of urine and blood are gaining popularity as a reliable and expeditious way to confidently arrive at a diagnosis of leptospirosis. Samples must be collected before any antibiotic is given or false negative results can occur. False negatives can also result if organisms are in too low a concentration.

We commonly submit both Leptospirosis titers (MAT) and PCR since the PCR is the more specific test and MAT is more sensitive.

ILLNESS

The typical clinical picture of leptospirosis is that of acute renal and hepatic dysfunction, but renal or liver failure may also occur alone. Azotemia is noted in 80-90% of dogs with leptospirosis.¹ ALP and bilirubin elevations are the most common hepatic analytes to be affected.¹ Respiratory dysfunction is also relatively common and was noted in 70% of dogs in one study, and has been

found in 9-93% of dogs in other studies.⁶ Thrombocytopenia was present in 73% of patients in the same study.⁶ Most dogs do not present with signs attributable to the urinary tract but instead have complaints of lethargy, anorexia, vomiting, diarrhea, and a painful abdomen. A diagnosis of leptospirosis is rarely suspected based on physical exam and history alone, and clinicopathologic data is generally needed to create that suspicion.

TREATMENT

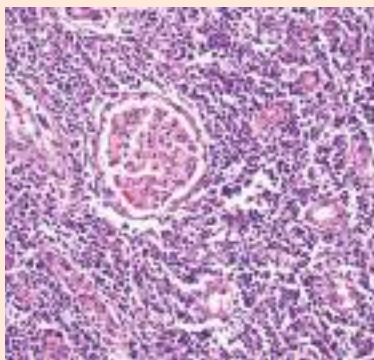
The preferred treatment for leptospirosis is Doxycycline 5mg/kg PO/IV twice daily for 2 weeks.¹ Doxycycline eliminates the organism from the renal tubular cells. Penicillin drugs including Amoxicillin and Ampicillin are also effective against leptospires. If it is not possible to give doxycycline, then Ampicillin 20mg IV QID is used as a common alternative. Ampicillin should not be used orally due to poor bioavailability by that route. Other symptomatic therapies (antiemetics, H₂-blockers, proton pump inhibitors, appetite stimulants) are used on an as-needed basis.

Fluid therapy can be a great challenge for patients with Leptospirosis. Oliguric or anuric renal failure is common and can be a life-threatening development for many of these patients. A fluid therapy algorithm is outlined below.

1. Fluid deficit (dehydration) should be replaced over 12-24 hours.
2. Maintenance fluid needs are usually supplied with a balanced crystalloid like LRS or Normosol-R.
3. Urine output should be quantified by use of a urinary catheter. This also prevents exposure of veterinary personnel and other animals to potentially infectious urine. Once the patient is rehydrated, IV fluid input should roughly match urine output. If urine output lags behind IV fluid input and the patient is gaining weight, this is a sign of oliguria and the IV fluid rate should be slowed down to better match urine output.

FIGURE 2

⚠ Photomicrograph of canine kidney with leptospirosis. Numerous leukocytes infiltrate the interstitium, separating and sometimes effacing renal tubules. This pattern is compatible with tubulointerstitial nephritis. An intact glomerulus is identified at the center of the image.



4. Conversion of oliguric (or even anuric) renal failure to polyuric renal failure can be facilitated by the use of IV diltiazem at a rate of 1-5 mcg/kg/min.⁷ We have had very positive experiences using Fenoldopam (an analog of dopamine) at 0.8mcg/kg/min.
5. Although the diuretic furosemide is often used with oliguric or anuric renal failure to manage volume overload, it does not hasten improvement in renal function.
6. If medical management of oliguric/anuric renal failure is not successful, then hemodialysis has proven to be a very effective way to manage these patients until their renal function improves (2-4 weeks).

Most patients with leptospirosis require hospitalization for 7 days or more. Many of them also need to have nasogastric or esophageal feeding tubes placed due to reluctance to eat during the period of clinical illness.

PROGNOSIS

The prognosis for dogs treated promptly and aggressively for leptospirosis is favorable (80% survival rate).¹ Anuric dogs not responding to medical management require hemodialysis to survive. Dogs that develop respiratory complications have a survival rate closer to 40%.⁸

For more information, please contact Dr. Bracker at emergency@angell.org or kbracker@angell.org, or call 617-522-7282.

REFERENCES

- 1 JE Sykes, K Hartmann, KF Lunn, GE Moore, RA Stoddard, RE Goldstein. 2010 ACVIM small animal consensus statement on leptospirosis: diagnosis, epidemiology, treatment, and prevention. *J Vet Intern Med.* 25(1);Jan-Feb 2011:1-13
- 2 Andre-Fontaine. Diagnosis algorithm for leptospirosis in dogs: disease and vaccination effects on the serological results. *Vet Rec.* May 2013;172(19):502
- 3 GE Moore, LF Guptill, MP ward. Adverse events diagnosed within three days of vaccine administration in dogs. *JAVMA.* 227;2005:1102-1108
- 4 SC Barr, PL McDonough, RL Scipioni-Ball, JK Starr. Serologic response of dogs given a commercial vaccine against serovar Grippotyphosa. *Am J Vet Res.* 66;2005:1780-1784
- 5 PN Levett. Usefulness of serologic analysis as a predictor of the infecting serovar in patients with severe leptospirosis. *Clin Infect Dis.* 36;2003:447-452.
- 6 B Kohn, et al. Pulmonary abnormalities in dogs with leptospirosis. *J Vet Intern Med.* 24;2010:1277-1282
- 7 KA Mathews, G Monteith. Evaluation of adding diltiazem therapy to standard treatment of acute renal failure caused by leptospirosis: 18 dogs (1998-2001). *Journal of Veterinary Emergency and Critical Care.* 17(2);2007:149-158
- 8 *Leptospira Serology*, P Ewing. *Clinical Veterinary Advisor: Dog and Cat*, 3rd Ed., Elsevier, 2015.



Cardiovascular Effects of Systemic Hypertension in Cats

■ Rebecca Quinn, DVM, DACVIM (Internal Medicine and Cardiology)

angell.org/cardiology cardiology@angell.org 617-541-5038

Systemic hypertension (HT) is a well-recognized condition in geriatric feline medicine. Systemic hypertension can be defined as either primary or secondary. Primary HT is diagnosed when an underlying cause cannot be identified; primary HT is the most common cause of HT in the human population. Secondary HT is defined as HT due to an underlying disease process. Almost all HT in cats is secondary; the most common causes of feline HT are hyperthyroidism and chronic kidney disease. Other, more unusual causes of secondary HT in cats can include pheochromocytoma, Cushing's disease, hyperaldosteronism, and multiple myeloma. In theory, other conditions such as acromegaly may cause or contribute to HT. If left untreated, HT can lead to severe end organ damage. Affected organs can include the eyes (vision loss, optic nerve damage), brain (hemorrhage, edema), kidneys (proteinuria, ischemia, fibrosis), and the heart.

CARDIOVASCULAR SYMPTOMS AND EXAM FINDINGS

Cats with HT may develop clinical symptoms at home indicating cardiovascular damage. These can include exercise intolerance, breathing difficulties, epistaxis, or collapse. Physical exam findings suggestive of cardiovascular damage or stress include a gallop rhythm (the presence of an S₄ heart sound), a soft systolic heart murmur, or an arrhythmia. Some patients may have abnormal lung sounds or abnormal mentation.

CARDIOVASCULAR CONSEQUENCES OF UNCONTROLLED SYSTEMIC HYPERTENSION

In human medicine, HT is often associated with stroke and myocardial infarction. This occurs as a result of microscopic artery wall tears and associated build-up of cholesterol and platelets. Arteries may become narrow enough to result in complete loss of arterial blood flow, or plaques may become dislodged and travel to vital organs. People may also experience hemorrhagic strokes, in which high arterial

pressure leads to rupture and bleeding of a vital artery. Unlike people, cats rarely have high cholesterol or primary vascular disease, factors that contribute greatly to stroke and myocardial infarction. Therefore, while these events may occur in feline HT, they are considered very rare.

Left ventricular hypertrophy is likely the most common cardiovascular consequence of prolonged HT in cats. Systemic hypertension is associated with narrowing of the arteries, which in turn increases the workload of the heart. In order for the heart to adapt, the heart walls must become thicker. If left uncontrolled, ventricular hypertrophy results in relaxation abnormalities, poor coronary blood flow, and left atrial enlargement. Cats with these changes may be more likely to experience congestive heart failure. Additionally, the thickened ventricular muscle is more sensitive to sympathetic stimulation, and these cats may also be more likely to develop cardiac arrhythmias.

More unusual cardiovascular complications of HT in cats have been reported. Aortic dissection occurs when HT causes the layers of the aorta to separate and tear. The tear can extend along the length of the ascending aorta, and allow blood to flow within the wall of the aorta itself. Aortic dissections can lead to aortic rupture, and are considered potentially life threatening.

DIAGNOSIS & TREATMENT

Blood pressure measurements in cats are most commonly obtained non-invasively using either the oscillometric technique (an automated system) or Doppler sphygmomanometry. Diagnosis of HT should be made when patient blood pressures are obtained in a calm and quiet setting, and after repeat readings indicate persistently elevated blood pressure. While the "white coat effect" must be taken into account, systolic blood pressure readings of greater than 180 mmHg support the diagnosis of HT. Because feline HT is so commonly associated with other illnesses, it is very important that these patients undergo full medical evaluations.

This typically includes labwork (complete blood count, chemistry panel, T₄ +/- free T₄, urinalysis +/- urine protein:creatinine, and endocrine testing as needed). Abdominal ultrasound or additional imaging may be required in some cats. If an underlying disease process can be identified, treatment of that condition should be initiated and the blood pressure rechecked within the appropriate time frame.

It is very important to recognize that some cats with appropriately treated underlying diseases still require anti-hypertensive therapies. Depending on the underlying cause, treatment options may include an angiotensin converting enzyme inhibitor (enalapril, benazepril), calcium channel blockers (amlodipine), or selective β blockers such as atenolol. Some patients may require more than one medication in order to appropriately control HT.

PROGNOSIS

Long-term adequate control of the underlying disease process and HT may lead to improvement, or even reversal, of cardiovascular changes. Patient symptoms and physical exam findings such as gallop sounds may resolve; control of HT is associated with improved left ventricular wall structure. Perhaps most importantly, control of HT has been linked to improved quality of life and decreased morbidity in our feline patients.

For more information, please contact Dr. Rebecca Quinn at rquinn@angell.org, send a message to the general cardiology inbox at cardiology@angell.org, or call the Cardiology Service at 617-541-5038.

ANGELL WELCOMES
NEW STAFF MEMBERS

Angell Animal Medical Center is pleased to announce that Ashley Jones, DVM, DACVIM (Cardiology) has joined our Cardiology Service and J. Lee Talbott, DVM, (Practice Limited to Medical Oncology) has joined our Oncology Service. Both Drs. Jones and Talbott will be practicing at Angell Boston.



ASHLEY E. JONES DVM, DACVIM (CARDIOLOGY)

Dr. Jones is a board-certified cardiologist. She completed her cardiology residency at the University of Florida in 2014. Her residency research project described a novel technique for atrial pacemaker implantation in dogs, and she was awarded a Resident Research Award at the 2013 ACVIM Conference in Seattle, WA. Prior to her residency, she earned her Doctor of Veterinary Medicine degree and completed a one-year small animal rotating internship at the Ontario Veterinary

College in Guelph, Ontario, Canada. Given her research experience and training at the University of Florida, Dr. Jones has a particular interest in congenital heart disease and interventional cardiac procedures, such as balloon valvuloplasties, PDA occlusions and pacemaker implantations. Dr. Jones maintains a strong passion for advancing the specialty of veterinary cardiology and thoroughly enjoys the variety of challenges she is presented with each day when managing cardiovascular disease.

EDUCATION

- Ontario Veterinary College, University of Guelph, DVM, 2010

SPECIALTY TRAINING

- Ontario Veterinary College, University of Guelph, Internship in Small Animal Medicine & Surgery, 2010-2011
- University of Florida Small Animal Hospital, Residency in Cardiology, 2011-2014
- University of Florida Small Animal Hospital, Cardiology Fellowship, 2014-2015

CERTIFICATION

- Diplomate, American College of Internal Medicine (Cardiology), 2014

REFERENCES:

Bonagura JD and Twedt DC. Kirk's Current Veterinary Therapy XV, 2014.

Brown, AL, Beatty JA, Lindsay SA, Barrs VR. Severe systemic hypertension in a cat with pituitary dependent hyperadrenocorticism. *Journal of Small Animal Practice* 53(2): 132-135, 2012.

Ettinger SJ and Feldman EC. *Textbook of Veterinary Internal Medicine*, 7th Edition, 2010.

Roderick AA, Harvey AM, Tasker S. Primary hyperaldosteronism in the cat. *Journal of Feline Medicine and Surgery* 7(3): 173-182, 2005.

Syme H. Hypertension in small animal kidney disease. *Veterinary Clinics of North America Small Animal Practice* 2011; 41 (1): 63 – 89.

Thompson J. Management of hypertension in a geriatric cat. *Canadian Veterinary Journal* 45: 427-429, 2004.

Wey AC, Atkins CE. Aortic dissection and congestive heart failure associated with systemic hypertension in a cat. *Journal of Veterinary Internal Medicine* 14(2): 208-213, 2000.



**J. LEE TALBOTT, DVM
(PRACTICE LIMITED TO MEDICAL ONCOLOGY)**

Dr. Talbott received her veterinary degree from Oklahoma State University College of Veterinary Medicine in 2011 followed by a small animal rotating internship in Denver, Colorado at Wheat Ridge Animal Hospital from 2011-2012. Dr. Talbott received advanced training in medical oncology at the University of Florida, as part of a comprehensive oncology department that combined the use of surgical oncologists,

radiation oncologists, and medical oncologists—one of only two academic training programs in the U.S. to offer this type of oncologic training. Dr. Talbott is passionate about using a multi-modal cancer treatment approach including immunotherapy, optimizing nutrition, acupuncture and integrative medical therapies for pain management and palliation, in addition to traditional treatments utilizing chemotherapy, radiation, and surgery. It is an exciting time to be in the field of veterinary oncology especially with the advancement of molecularly targeted drug therapy for treatment of cancer in our companion animals.

EDUCATION

- Oklahoma State University College of Veterinary Medicine, DVM, 2011
- Pennsylvania State University, BS in Animal Sciences, 2004

SPECIALTY TRAINING

- University of Florida, Residency in Medical Oncology, 2012-2015
- Wheat Ridge Animal Hospital, Rotating Internship in Small Animal Medicine and Surgery, 2011-2012

**EXPANDED CARDIOLOGY APPOINTMENTS
AT ANGELL WEST**

Angell is pleased to offer expanded Cardiology appointment hours at Angell West in Waltham, including regular Saturday appointments. Rebecca Malakoff, DVM, DACVIM (Cardiology) practices full time at our Waltham facility and provides echocardiograms and other Cardiology services on site.



Social Enrichment for Healthy Interaction Between Juvenile Pet Birds and Veterinary Professionals

■ Elisabeth Simone-Freilicher, DVM, DABVP (Avian practice)

angell.org/avianandexotic avianexotic@angell.org 617-989-1561

Occasionally during their lives, pet birds will visit the vet. There are many components to this experience to which a young bird should be gradually and gently acclimated: the carrier, the car ride (or other mode of transportation), towels, and restraint.

Most young birds have not yet had an opportunity to become phobic of towels, although they may exhibit neophobia (fear of novel objects). Ideally, the towels used during the veterinary visit should not be highly patterned and should be of a neutral color; remember that psittacine birds can see into the ultraviolet and infrared portions of the spectrum, so a plain white towel might seem disturbingly bright to them. If the owner has acclimated the bird to towels at home, the bird may have a preferred towel that it is used to, and the owner should be encouraged to bring this to the visit.

While the technique of quickly grabbing the bird with a towel from above and behind unfortunately may sometimes be needed in the case of an adult bird that is not tame (especially in many small species), this is not at all necessary and may be extremely frightening for the pediatric patient. Instead, the towel may be offered to the young bird to explore and chew, and then gently wrapped around the bird starting from the front. Some avian behaviorists recommend speaking to the bird first, calmly explaining what will happen next.¹ While different species and individuals may vary widely in how much of this monologue they may understand, it often does seem to have a remarkably calming effect. If the owner has already acclimated the young patient to towels, the owner may prefer to wrap the bird herself and hand him or her to the veterinarian.

Handling during the veterinary visit must be gentle and practiced; aggressive handling during the veterinary visit may precipitate phobic behaviors in psychologically sensitive species such as rose-breasted, citron-crested, and triton cockatoos and African greys¹ as well

as Poicephalus species. The practitioner and staff should enter the examination room calmly and quietly to avoid startling a bird, particularly if the bird is out of the carrier, as injury may occur.

Actual restraint should be as brief and gentle as possible. With many pediatric patients, this author often finds towel and restraint is not necessary at all. The pediatric patient may stand calmly cupped in an assistant's hand (Fig. 1), and allow a thorough physical examination including oral and caudal coelomic palpation, with the veterinarian softly speaking to the patient and maintaining eye contact. This author prefers to use words and sounds recognized and enjoyed by the parrot if these are known, or those commonly preferred by the species if the individual preferences are not known (such as soft clicks for the African species). Additionally, as noted previously, sidelong glances with slow blinks are more psittacine and less threatening than the unblinking forward stare of a predator. Stethoscopes are occasionally somewhat alarming (possibly because of their resemblance to snakes or simply because they are novel), and if the bird is seen to withdraw or appear apprehensive, this author will often stop and demonstrate the harmlessness of the instrument by tapping the bell lightly on her own cheek, and possibly that of the assistant as well, all while maintaining an encouraging eye contact and speaking softly to the patient. Once the young bird seems to accept this, the bell of the stethoscope is lightly stroked over the bird's toes, until this too is accepted, and only then is auscultation of the heart and lungs attempted.

When returning the bird to the owner, it is helpful to allow the bird to run across the table to the owner for comfort; this also can strengthen the owner-parrot bond. However, for any juveniles that seem highly stressed by the examination, returning the bird directly to the owner sometimes seems to result in an association made by the bird between the owner and the visit, and phobic behavior toward the owner can ensue.¹

FIGURE 1

▾ The pediatric patient may stand calmly cupped in an assistant's hand, and allow a thorough physical examination including oral and caudal coelomic palpation, with the veterinarian softly speaking to the patient and maintaining eye contact.



When seeing pet birds, behavioral considerations during the veterinary visit can make the experience much less stressful for the patient and much more pleasant for owners and staff. When the patient is a juvenile parrot, keeping the examination low-stress can help prevent a lifetime of fearful and phobic behaviors associated with the annual examination.

Contact Angell's Avian and Exotic service at 617-989-1561 or avianexotic@angell.org. You can also reach Dr. Simone-Freilicher at esimonefreilicher@angell.org.

REFERENCES

Adapted from: Simone-Freilicher, E, and Rupley A. "Juvenile Psittacine Environmental Enrichment" in Rupley A (Editor): *Veterinary Clinics of North America: Exotic Animal Practice*, Volume 18, Issue 2, May 2015.

1 Wilson, L. Considerations on Companion Parrot Behavior and Avian Veterinarians. *JAMS* 14-4 (2000): 273-276.

STAFF DOCTORS

■ We encourage you to email Angell's specialists with questions.

Main Phone: 617-522-7282 (Boston), 781-902-8400 (Waltham) Veterinary Referrals: 617-522-5011

CHIEF OF STAFF

Ann Marie Greenleaf, DVM, DACVECC
agreenleaf@angell.org

24/7 EMERGENCY & CRITICAL CARE (W/B)

Charles Amuguni, BVM
camuguni@angell.org

Lauren Baker, DVM
lbaker@angell.org

Kiko Bracker, DVM, DACVECC
kbracker@angell.org

Emily Finn, DVM
efinn@angell.org

Jessica Hamilton, DVM
jhamilton@angell.org

Roxanna Khorzad, DVM
rkhorzad@angell.org

Megan Krauth, DVM
mkrauth@angell.org

Tamara Kremer Mecabell, DVM
tmecabell@angell.org

Amanda Lohin, DVM
alohin@angell.org

Courtney Peck, DVM
cpeck@angell.org

Brooke Simon, DVM
bsimon@angell.org

Virginia Sinnott, DVM, DACVECC
vsinnott@angell.org

Catherine Sumner, DVM, DACVECC
csumner@angell.org

Megan Whelan, DVM, DACVECC
mwhelan@angell.org

ANESTHESIOLOGY

Ashley Barton-Lamb, DVM, DACVAA, CVA
abartonlamb@angell.org

Stephanie Krein, DVM, DACVAA
skrein@angell.org

AVIAN & EXOTIC MEDICINE (W/B)

Brendan Noonan, DVM, DABVP
(Avian Practice)
bnoonan@angell.org

Elisabeth Simone-Freilicher, DVM, DABVP
(Avian Practice)
esimonefreilicher@angell.org

BEHAVIOR (W/B)

Terri Bright, Ph.D., BCBA-D
tbright@angell.org

CARDIOLOGY (W/B)

Ashley Jones, DVM, DACVIM (Cardiology)
ajones@angell.org

Nancy Laste, DVM, DACVIM (Cardiology)
nlaste@angell.org

Rebecca Malakoff, DVM, DACVIM
(Cardiology)
rmalakoff@angell.org

Rebecca Quinn, DVM, DACVIM
(Cardiology and Internal Medicine)
rquinn@angell.org

DENTISTRY

Erin Abrahams, DVM
eabrahams@angell.org

William Rosenblad, DVM
wrosenblad@angell.org

DERMATOLOGY

Klaus Loft, DVM
keloft@angell.org

DIAGNOSTIC IMAGING*

Rebecca Manley, DVM, DACVR
rmanley@angell.org

Joan Regan, VMD, DACVR
jregan@angell.org

Steven Tsai, DVM, DACVR
stsai@angell.org

INTERNAL MEDICINE (W/B)

Daniela Ackley, DVM, DACVIM
dackley@angell.org

Doug Brum, DVM
dbrum@angell.org

Maureen Carroll, DVM, DACVIM
mccarroll@angell.org

Erika de Papp, DVM, DACVIM
edepapp@angell.org

Jean Marie Duddy, DVM
jduddy@angell.org

Kirstin Johnson, DVM, DACVIM
kcjohnson@angell.org

Shawn Kearns, DVM, DACVIM
skearns@angell.org

Susan O'Bell, DVM, MPH, DACVIM
sobell@angell.org

Cynthia Talbot, DVM
ctalbot@angell.org

NEUROLOGY (W/B)

Rob Daniel, DVM, DACVIM (Neurology)
rdaniel@angell.org

Allen Sisson, DVM, MS, DACVIM (Neurology)
asisson@angell.org

NUTRITION

Dana Hutchinson, DVM, DACVN
dhutchinson@angell.org

ONCOLOGY

Lyndsay Kubicek, DVM, DACVR
(Radiation Oncology)
lkubicek@angell.org

Ivan Martinez, DVM, DACVIM
(Medical Oncology and Internal Medicine)
imartinez@angell.org

J. Lee Talbot, DVM
(Practice Limited to Medical Oncology)
jtalbot@angell.org

OPHTHALMOLOGY

Daniel Biros, DVM, DACVO
dbiros@angell.org

Martin Coster, DVM, MS, DACVO
mcoster@angell.org

PAIN MEDICINE

Lisa Moses, VMD, DACVIM, CVMA
lmoses@angell.org

PATHOLOGY (CLINICAL & ANATOMIC)*

Patty Ewing, DVM, MS, DACVP
pewing@angell.org

Pamela Mouser, DVM, MS, DACVP
pmouser@angell.org

SURGERY (W/B)

Sue Casale, DVM, DACVS
scasale@angell.org

Michele Kudisch, DVM, DACVS
mkudisch@angell.org

Michael Pavletic, DVM, DACVS
mpavletic@angell.org

Meghan Sullivan, DVM, DACVS
msullivan@angell.org

Nicholas Trout, MA, VET MB, MRCVS,
DACVS, DECVS
ntrout@angell.org

(W/B) Services available at our Waltham and Boston locations. Behavior appointments are available in Waltham upon request.

*Boston-based radiologists and pathologists, serve both Boston & Waltham locations.



Nonprofit Org.
US Postage
PAID
Permit No. 1141
Boston, MA

We mail one complimentary copy of our newsletter to each of our referring partners. Please circulate this copy within your practice.

Fall 2015 ■ Volume 9:3 ■ angell.org ■ facebook.com/AngellReferringVeterinarians

MSPCA-ANGELL

350 South Huntington Avenue
Boston, MA 02130
617-522-5011
angell.org

MSPCA-ANGELL WEST

293 Second Avenue
Waltham, MA 02451
781-902-8400
angell.org/waltham

Please consider adding Angell's main numbers to your after-hours phone message.
See page 5 for complimentary after-hours phone services.








■ angell.org/directions (free parking) ■ angell.org/hours ■ angell.org/ce

↘ COURTESY SHUTTLE TO/FROM BOSTON FOR ANGELL WEST PATIENTS

Our Waltham facility has a complimentary shuttle that will transport patients to and from Boston if further specialized care is needed.

Please call **781-902-8400** to book appointments or referrals, or visit angell.org/waltham for a full list of expanding Waltham services.

MSPCA-Angell West hospital services currently include...*

-  24/7 EMERGENCY & CRITICAL CARE
-  AVIAN & EXOTIC MEDICINE
-  BEHAVIOR**
-  CARDIOLOGY
-  INTERNAL MEDICINE
-  NEUROLOGY
-  SURGERY

*Boston-based radiologists and pathologists serve both Boston and Waltham locations.

**Behavior appointments are available in Waltham upon request.