



ELECTROCARDIOGRAPH INTERPRETATION – BACK TO BASICS	UNDERLYING GASTROINTESTINAL DISEASE MAY MANIFEST AS NEUROLOGIC SIGNS IN CANINE PATIENTS	MEGAESOPHAGUS	HYPERCALCEMIA OF MALIGNANCY (HM)	SUBCUTANEOUS URETERAL BYPASS (SUB™) FOR THE TREATMENT OF URETERAL OBSTRUCTION IN CATS
				
PAGE 1	PAGE 1	PAGE 6	PAGE 8	PAGE 10

CARDIOLOGY



Electrocardiograph Interpretation – Back to Basics

■ Rebecca Malakoff, DVM, DACVIM (Cardiology) MSPCA-Angell West

angell.org/cardiology
cardiology@angell.org
617-541-5038

Making an Electrocardiograph (ECG) diagnosis may feel like a daunting task when a veterinarian is infrequently faced with the challenge, but confidence can be gained by practice and a systematic approach. It is often helpful to break down the interpretation into steps, rather than trying to jump to a diagnosis right away, and to pay attention to each deflection as well as the overall pattern.

A quick review of the normal conduction pathway is very helpful when faced with a potentially abnormal ECG recording. With normal conduction, the impulse starts in the sinus node, depolarizes the atria (represented by the P wave on the ECG), and travels to the atrioventricular (AV) node. The pause in transmission at the AV node leads to the PR interval on the ECG. The electrical impulse then rapidly travels down the bundle of His and the left and right bundle branches to depolarize the ventricular myocardium (represented by the QRS wave on the ECG). Finally, ventricular repolarization occurs (represented by the T wave on the ECG). It may sound basic, but keeping in mind what each wave reflects is very helpful when you need to determine which electrical disruption is creating an arrhythmia. For example, a prolonged PR interval represents a delay in conduction at the AV node (first-degree AV block), and a widened QRS complex represents prolonged conduction through the ventricles, either due to a ventricular ectopic beat or abnormal intraventricular conduction such as bundle branch block.

(CONTINUED ON NEXT PAGE)

NEUROLOGY



Underlying Gastrointestinal Disease May Manifest as Neurologic Signs in Canine Patients

■ Michele James, DVM, DACVIM (Neurology)

angell.org/neurology
neurology@angell.org
617-541-5140

Stereotypic behaviors such as fly biting, stargazing, and excessive licking of surfaces are not uncommon presenting complaints for patients being evaluated through the Neurology Service. Many times, patients exhibiting these behaviors are referred to a neurologist due to the concern for seizure activity or to a behaviorist due to the concern for obsessive compulsive disorders. However, underlying primary gastrointestinal (GI) disease should not be overlooked as a potential cause for these behaviors.

Several studies have been published over the last few years in reference to primary GI disorders in dogs, manifesting as stereotypic behaviors such as excessive licking of surfaces or fly biting. In a prospective clinical study out of Canada, underlying GI abnormalities were noted in 14 out of 19 study dogs with a history of excessive licking of surfaces. In this study by Bécuwe-Bonnet et al., all dogs included in the study underwent physical and neurologic examinations by board-certified specialists. Following examinations, bloodwork was collected for complete blood count, serum chemistry panel, pre- and post-bile acids, and canine-specific pancreatic lipase immunoreactivity. Fecal and urinary samples were also submitted for evaluation. In addition, each study dog had a standard upper GI endoscopy performed under general anesthesia, and mucosal samples were collected from various areas of the stomach and duodenum. Study dogs were also videotaped for additional behavioral evaluation. Specific treatment was

(CONTINUED ON PAGE 5)

CARDIOLOGY

Continued from page 1

One method of a systematic approach to ECG interpretation includes:

Step 1: Determine heart rate.

Step 2: Determine whether heart rate is normal, fast, or slow.

Step 3: Are QRS complexes uniform in appearance or variable? Are they normal (narrow) or wide?

Step 4: Determine whether underlying rhythm (of the R waves) is regular or irregular.

If the rhythm is irregular, is it regularly irregular (follows a repeating pattern) or irregularly irregular?

Step 5: Determine association between P waves and R waves. (Is there a P for every QRS, a QRS for every P?) Are P waves uniform in appearance or variable?

If you have completed Step 1 for a patient (counting heart rate), and determined that a tachycardia is present, the next step is to determine the type of tachycardia. Before trying to jump to an exact diagnosis, it is helpful to

determine which of the two general types of tachycardia is present by examining the QRS complexes and determining whether they are narrow or wide. A narrow-complex QRS appears narrow because the electrical impulse is using the rapid conduction system (His bundle and left and right bundles) to depolarize the ventricular myocardium. This means the electrical impulse originates above, or at, the AV node. Examples of a narrow-complex tachycardia include sinus tachycardia, atrial tachycardia, AV junctional tachycardia, atrial flutter, and atrial fibrillation.

FIGURE 1

Lead II, 25 mm/sec. This ECG shows a rapid, narrow-complex monomorphic (QRS complexes all the same shape) tachycardia. P' waves are not visible, as they are superimposed on preceding QRS/T complexes. The heart rate is 330 bpm. The diagnosis is supraventricular tachycardia.

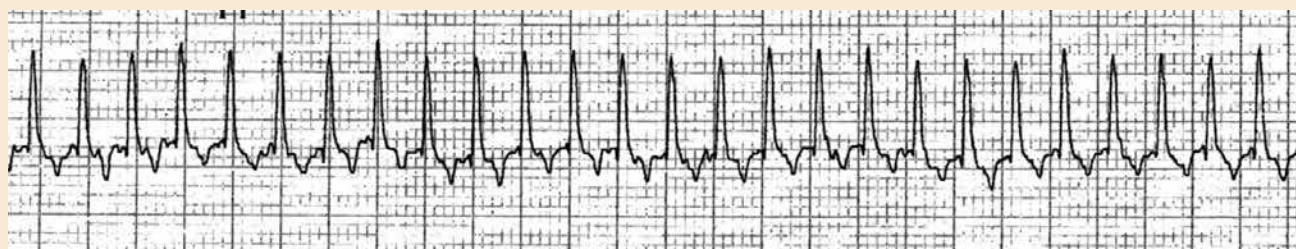

FIGURE 2

Lead II, 25 mm/sec. This is another example of a supraventricular tachycardia, showing a brief break in the tachycardia and revealing two normal P waves (arrows). Again, P' waves are superimposed on the preceding complexes during the tachycardia.

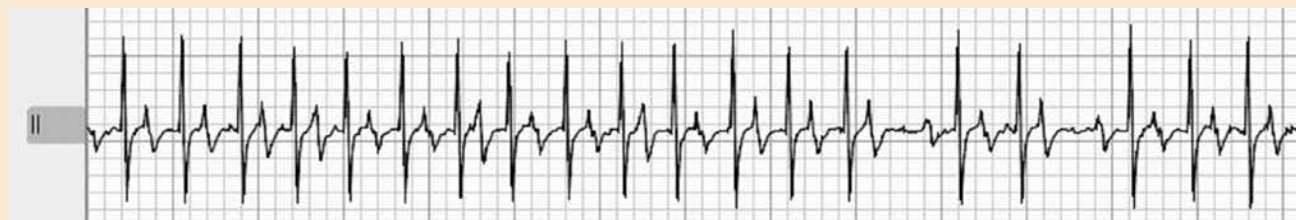

FIGURE 3

Lead II, 25 mm/sec. Although similar to the preceding examples, this ECG recording of a narrow-complex tachycardia has a more irregular pattern of R-R intervals. During the longer R-R intervals, there is no evidence of a definitive P wave or repeating P-R interval (although the baseline undulations can at times mimic a P wave, and it is important not to mistake the preceding complex T wave as a P wave). The diagnosis is atrial fibrillation.

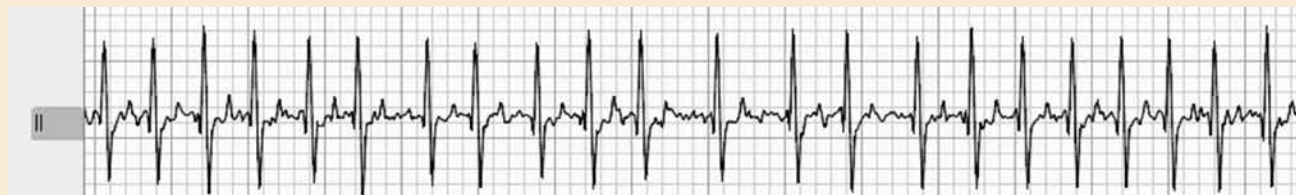

FIGURE 4

Lead II, 25 mm/sec. This ECG shows a wide-complex tachycardia, representing ventricular tachycardia.

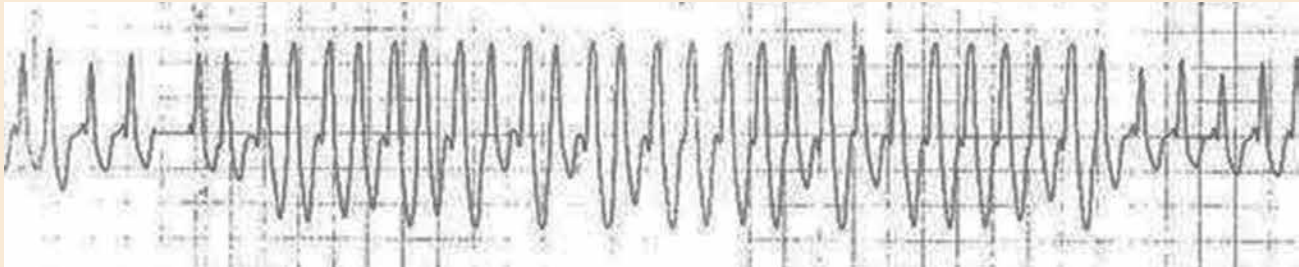


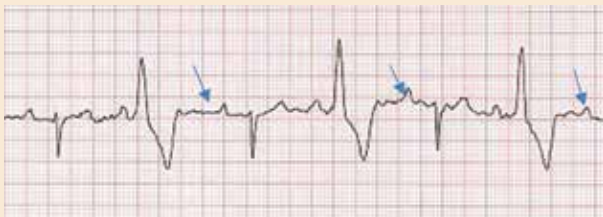
FIGURE 5

Lead II, 25 mm/sec. Another example of ventricular tachycardia, with negatively deflected QRS complexes.

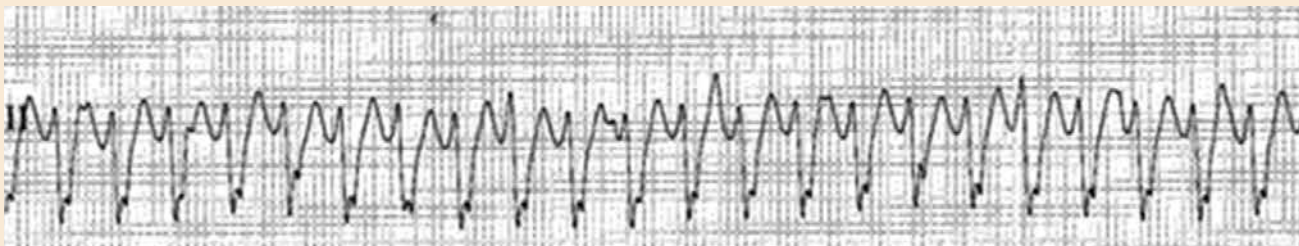

FIGURE 6

An example of VPCs where preceding P waves are visible (arrows), but not associated (no repeating PR interval) with the subsequent QRS complex.



If a QRS complex is wide, this indicates depolarization of the ventricular myocardium is delayed, often because all or part of the electrical impulse is traveling by slower cell-to-cell conduction rather than using the rapid conduction system. The majority of wide-complex tachycardia seen on ECG recordings represent ventricular tachycardia, but you can also have a wide-complex tachycardia when there is aberrant conduction of a sinus or supraventricular tachyarrhythmia, such as with bundle branch block. If in doubt, it is safest to assume a wide-complex tachycardia is ventricular tachycardia and treat accordingly.

Looking at the association between P waves and QRS complexes is also very helpful for determining whether a rapid rhythm is a supraventricular vs. ventricular tachycardia, but a few key points must be kept in mind. Most practitioners remember that a supraventricular premature complex is preceded by a P' wave, which represents aberrant atrial depolarization,

(CONTINUED ON PAGE 4)

FIGURE 7A

Right bundle branch with block.

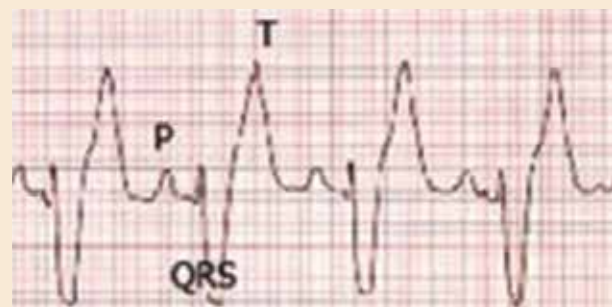
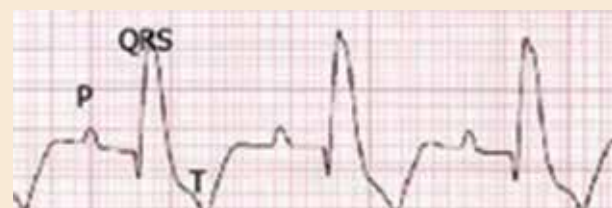

FIGURE 7B

Left bundle branch block. QRS complexes are wide, indicative of slowed intraventricular conduction, but there is a repeating PR interval preceding each complex.



Continued from page 3

FIGURE 8

Lead II, 25 mm/sec. Heart rate (QRS rate) is 60 bpm. There is repeating PR interval, but each QRS complex is followed by a nonconducted P wave (arrow). (The P waves are easy to overlook due to relative low amplitude.) Diagnosis is second-degree AV block with 2:1 conduction.

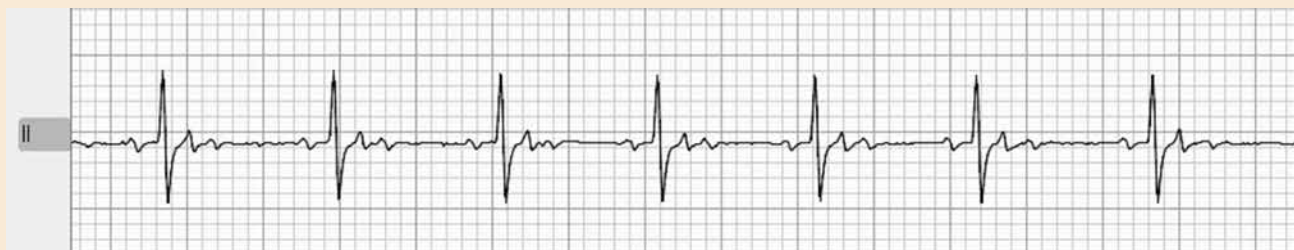
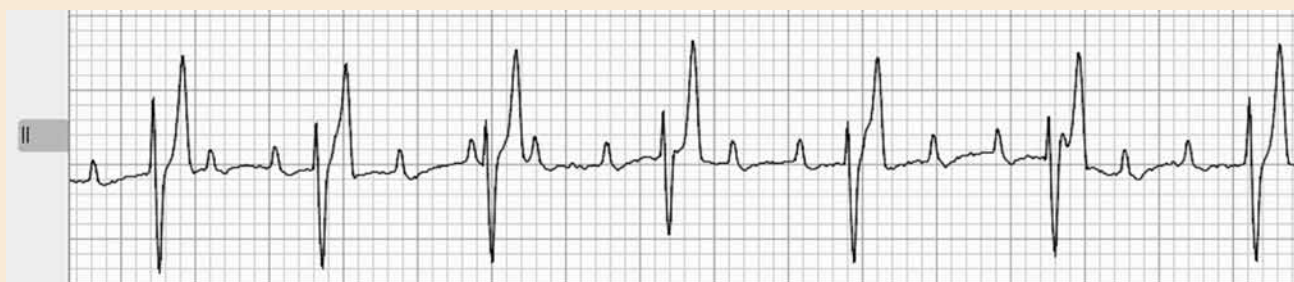
FIGURE 9

Lead II, 25 mm/sec. Heart rate (QRS rate) is 50 bpm. P waves are present, but there is no association with the QRS complexes (no repeating PR interval). Diagnosis is third-degree AV block.



and has a regular P-R interval (association). But it is easy to forget that this P' wave may not be visible, as it may be buried in the preceding T wave or QRS complex. Another common misconception is the expectation that there will be no P waves with a ventricular premature complex (VPC) or ventricular tachycardia. A normal P wave may be present (normal atrial depolarization may occur), but it has nothing to do with the subsequent VPC, which was initiated by spontaneous ventricular depolarization (no PR association). Often, these P waves may be obscured or buried within the VPC, but if the VPC is only slightly premature, you may still see a P wave preceding it. If P waves are regularly seen before wide QRS complexes, with a repeatable PR interval, this indicates bundle branch block (the electrical impulse was initiated normally in the sinus node, relayed through the AV node, but then disruption in conduction through the bundle branches led to the wide QRS appearance).

QRS complexes are wide, indicative of slowed intraventricular conduction, but there is a repeating PR interval preceding each complex.

When faced with an abnormally slow rhythm, it can be similarly helpful to then determine whether the QRS complexes are narrow or wide, and whether they are regularly preceded by P waves. If a regular PR interval occurs, one should determine whether it is normal length or prolonged (first-degree AV block). P waves that sometimes are followed by a QRS (with repeatable PR interval) but sometimes not ("dropped P waves") indicate second-degree AV block. This occurs when the AV node only intermittently transmits the signal to the ventricles to depolarize. When there is no association between the P waves and QRS complexes, this indicates AV dissociation, most commonly due to third-degree AV block (where the AV node fails to transmit any of the electrical impulses to the ventricles). Wide QRS complexes that occur later than the expected next complex, with no preceding associated P wave, are ventricular escape beats. These are fairly easy to recognize when occurring as part of third-degree AV block, but may also occur with other pauses in rhythm during sinus bradycardia or sick sinus syndrome. It is important to keep in mind that these represent

ventricular ectopy, but are not VPCs because they are not premature (and should not be treated the same).

Thorough discussion of all considerations in ECG diagnosis and arrhythmia treatment is beyond the scope of a short article, but hopefully this review will help you in reaching an ECG diagnosis with increased ease and confidence. Fortunately, in those cases where the diagnosis is still uncertain, Angell's team of cardiologists are available to help.

For more information on this and all cardiology-related questions, please contact **Angell's Cardiology Service** at **617-541-5038** or **cardiology@angell.org**. Dr. Malakoff works full-time at our Waltham location.

NEUROLOGY

Continued from page 1

recommended and started in the 14 affected study dogs with a specific GI disorder based on diagnostic test results. For the five study dogs with excessive licking behavior that did not have a specific GI disorder, nonspecific treatment such as an elimination diet and antacid were started. Study dogs were then monitored for 90 days following treatment initiation. Almost 60% of dogs with excessive licking behavior were noted to experience significant improvement in the frequency and duration of their behavior with treatment. Over half the dogs in the study with excessive licking behavior had complete resolution of their clinical signs with treatment. Based on the findings in this study, GI disorders should be included on the list of differential diagnosis in patients presenting with excessive licking behavior.

A similar prospective study by Frank et al. looked at seven dogs with fly-biting behavior and found GI disease in five of the seven dogs. Dogs in this study were treated with a combination of an elimination diet, Famotidine, Fenbendazole, Prednisone, Metronidazole, Sucralfate, and/or a prokinetic agent. Five of the seven dogs improved, and four had a complete resolution of fly-biting behavior after 30 days. Both the Bécuwe-Bonnet and Frank studies identified repeatable stereotypic behavior,

specifically excessive licking and fly biting, associated with primary GI disease, which is similar to Sandifer Syndrome observed in infants and nonverbal children. Sandifer Syndrome is a rare movement disorder characterized by spasmodic torticollis and dystonia, such that patients will have episodes where they will arch their back and hold their neck in marked extension for several minutes. Sandifer Syndrome is associated with underlying gastroesophageal reflux disease (GERD), and successful treatment of GERD with antacid therapy leads to suppression of dystonic movements and resolution of clinical signs. It is believed that the dystonic movements observed in children with Sandifer Syndrome are a vagally mediated response to esophageal pain and discomfort. The same theory may also apply to dogs with esophageal and/or upper GI tract disease and secondary discomfort that present with excessive licking or fly-biting behavior.

In practice, for patients that present to me with clinical signs of excessive licking, stargazing, and/or fly biting with an otherwise normal neurologic examination, I have GI disease on my list of differentials. I typically recommend a trial of Omeprazole at 1 mg/kg PO Q24hr for two to three weeks, particularly in patients with a history of repetitive neck extension and/or

clinical signs that appear to be worse after meals. During this time, I will ask owners to monitor for a decrease in the frequency and duration of their pet's episodes. Depending on the patient's medical history, physical exam findings, diagnostic test results, and my suspicion for partial-seizure activity, I may also place these patients on a trial of anti-seizure medication, such as Levetiracetam (20-30 mg/kg PO Q8hr) or Zonisamide (5 mg/kg PO Q12hr), at the same time or following the Omeprazole trial if no improvement is noted. Additional diagnostic workup for primary GI disease (e.g., bile acids, endoscopy, etc.) and/or neurologic disease (e.g., MRI of the brain with or without a spinal tap) may be warranted, depending on the patient's response to therapy and progression of clinical signs. It should be noted that Omeprazole not only increases gastric pH, but has also been shown to decrease the production of cerebrospinal fluid. Therefore, it is used routinely for treatment of esophagitis and gastritis, but is also used in the management of caudal occipital malformation syndrome (COMS) and syringomyelia (SM). It is possible that some patients who respond favorably to Omeprazole therapy may be benefiting from not only its antacid effects, but also from its effect on CSF production.

In summary, when presented with stereotypic behaviors such as excessive licking, fly biting, and stargazing in a canine patient, primary GI disease should be on your differential list, as many patients may respond favorably and even experience a complete resolution of clinical signs with proper treatment.

For more information, please contact
Angell's Neurology Service at 617-541-5140
 or Neurology@angell.org.

REFERENCES:

- 1 Bécuwe-Bonnet, V; Bélanger, MC; Frank, D; Parent, J; and Hélie, P. Gastrointestinal disorders in dogs with excessive licking of surfaces. *Journal of Veterinary Behavior* 2012; 7: 194-204.
- 2 Frank, D; Bélanger, MC; Bécuwe-Bonnet, V; and Parent, J. Prospective medical evaluation of 7 dogs presented with fly biting. *Can Vet J* 2012; 53: 1279-1284.
- 3 Poirier-Guay, MP; Bélanger, MC; and Frank, D. Star gazing in a dog: Atypical manifestation of upper gastrointestinal disease. *Can Vet J* 2014; 55: 1079-1082.

FIGURE 1

⚠ Stereotypic behaviors such as fly biting, stargazing, and excessive licking of surfaces are not uncommon presenting complaints for patients being evaluated through the Neurology Service.





Megaesophagus

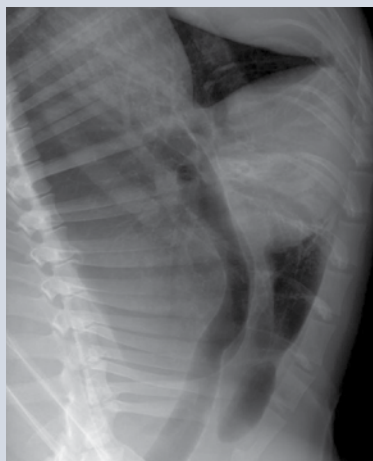■ Shawn Kearns, DVM, DACVIM Internal Medicine Service

angell.org/internalmedicine
internalmedicine@angell.org
617-541-5186

Megaesophagus (ME) is defined as a diffuse dilation of the esophagus resulting from decreased or absent motility. Esophageal motility is controlled by afferent neural pathways from receptors in the esophagus that are stimulated by the presence of food or water. Once stimulated, the impulses relay to the brain stem nuclei and swallowing center. Efferent motor pathways of the vagus nerve carry impulses to myoneural junctions in the esophagus. Although the pathogenesis of many forms of megaesophagus is not completely understood, failure along any of these pathways leads to dilation and clinical signs.

FIGURE 1

✎ Eight-year-old male castrated German shepherd diagnosed with megaesophagus at 6 months of age. Note the dilated, fluid-filled esophagus as well as air bronchograms in the right middle lung lobes, consistent with aspiration pneumonia.



Although structural diseases such as vascular ring anomalies, foreign bodies, and strictures may cause esophageal dilation, these often result in localized dilation proximal to the obstruction. Megaesophagus is often divided into congenital versus acquired causes. Congenital causes are usually idiopathic in nature, whereas acquired may be primary

(idiopathic) or secondary to other diseases such as myasthenia gravis, hypoadrenocorticism, canine dysautonomia, tetanus, polyradiculoneuritis, tick paralysis, lead toxicity, systemic lupus erythematosus, polymyositis, and possibly hypothyroidism. Evidence for hypothyroidism as a secondary cause is low; however, there is one case report demonstrating a positive response to thyroid supplementation.

Congenital ME has been documented in many breeds, including the wire-haired fox terrier, miniature schnauzer, Great Dane, Newfoundland, Rhodesian ridgeback, and Chinese Shar-Pei. Clinical signs with congenital ME most often start shortly after weaning. With acquired ME, signs usually start when patients are middle age to older (7 to 15 years).


Patients often present with clinical signs of regurgitation, which may occur shortly after eating to within hours of a meal. However, there is not always a time association with feeding noted. Other signs may include drooling, pain with swallowing, and anorexia from resulting esophagitis. Coughing, fever, lethargy, nasal discharge, and/or difficulty breathing may be seen with concurrent aspiration pneumonia. Weight loss can be marked from chronic lack of nutrition. Signs referable to a secondary disease process may also be present.

Megaesophagus is diagnosed by persistent esophageal dilation on survey radiographs. Aerophagia and reflux esophagitis may result in temporary esophageal dilation. If signs resolve quickly or there is a reason to suspect a temporary condition, repeat radiographs are warranted before proceeding with a more advanced diagnostic workup. Positive contrast studies, videofluoroscopy, and esophagoscopy are more often used to determine a cause with localized esophageal dilation or to diagnose altered esophageal motility in patients without radiographic evidence of megaesophagus.

Once testing has confirmed megaesophagus, evaluation for an underlying cause is recommended. Generally, this would include a CBC, chemistry panel, urinalysis, blood lead level, creatine kinase, acetylcholine receptor

FIGURE 2

✎ An Angell patient with megaesophagus having his meal in a Bailey's chair



antibody test, resting cortisol or ACTH stimulation, and a sTSH panel. Testing can be prioritized based on any lab work changes or clinical signs that may indicate a more likely secondary cause.

Unfortunately, there are no medical treatments that improve esophageal motility. Therapy is directed at any identified secondary causes, treatment of esophagitis, and supportive care, including nutrition and treatment of pneumonia. Feedings for patients should be small and frequent in nature with the patient in an elevated or upright position to take advantage of gravity for esophageal clearance. A Bailey chair may be feasible for some patients to assist with longer upright position times (see figure 2). Different diet consistencies (liquid, solids, and chunks/meatballs) should be tried to determine what is best for an individual patient. Using a

INTERNAL MEDICINE

Continued from page 6

doughnut-shaped e-collar or travel pillow at night may allow for additional elevation when resting and has been helpful for some patients at decreasing regurgitation. Calorie-dense diets help to decrease the total volume needed daily, but the higher fat content may not be tolerated by all patients. Animals that cannot maintain adequate nutritional balance with oral feedings should be considered for a gastrostomy tube.

Even with diligent care, these patients are susceptible to aspiration pneumonia, and this is a common reason for decreased quality of life with subsequent euthanasia. Although there is anesthetic risk with endotracheal or trans-tracheal washes, patients with repeated bouts of aspiration pneumonia would ideally undergo these procedures due to the concern for antibiotic resistance over time. Larger dogs with good temperaments often can do well with trans-tracheal washes using only light sedation and a local block. Intravenous or subcutaneous antibiotic options may need to be considered if patients are regurgitating and do not have a percutaneous gastrostomy tube. A recent case series describes the use of a wide-lumen, multi-

side holed esophagostomy tube used to do periodic esophageal suctioning at home to reduce esophageal secretions. Although there were only four patients in this series, the number of episodes of regurgitation and aspiration pneumonia were significantly reduced, so this may be considered for a select patient population.

A very recent social media posting from the University of Missouri College of Veterinary Medicine has suggested that there may be a subpopulation of dogs with megaesophagus that have an achalasia-like (asynchronous) lower esophageal sphincter disorder. In this population, balloon dilation of the esophageal sphincter and/or Botox injections may allow sphincter relaxation and passage of food. More evaluation is needed for this concept, but those that improve with esophageal sphincter relaxation may be candidates for a more permanent surgical procedure.

For patients with megaesophagus secondary to myasthenia gravis, therapeutic plasma exchange may be an option for treatment.

Therapeutic plasma exchange (TPE), or apheresis, is an extracorporeal procedure that separates blood into its components such that plasma, and antibodies within the plasma, can be removed and exchanged with donor plasma. Though reports are limited, there are canine cases that presented with fulminant myasthenia gravis that responded to TPE, including resolution of megaesophagus.

The prognosis for patients with megaesophagus remains poor, with a reported median survival time of one to three months after diagnosis. With diligent care and dedicated owners, some will survive for extended periods. Hopefully with advancement in treatment options, we can continue to improve the quality of life and survival times for these patients.

For more information, please contact **Angell's Internal Medicine Service** at 617-541-5186 or internalmedicine@angell.org.



▾ HAVE YOU TRIED ANGELL'S REFERRING VETERINARIAN PORTAL?

Angell's Referring Veterinarian Portal is a mobile-friendly online portal for referring veterinarians to gain 24/7 access to their patients' lab results, image studies, SOAPs, referral reports, check in/discharge status, discharge instructions, and more.

To receive a login and password for your clinic, please contact us at 617-522-7282.



▾ GRIEF COUNSELING

We are delighted to have welcomed Annette Scanlon, LICSW, our first MSPCA-Angell Veterinary Social Worker (VSW) on June 19th. As a licensed independent clinical social worker (LICSW), Annette will provide support, counseling, and educational services to clients and staff. Among many responsibilities, she will assist doctors working with clients to facilitate end-of-life decisions and to provide individual and group grief counseling associated with the loss of companion animals for clients of the MSPCA-Angell. (Angell provides grief counseling as a courtesy service.)



Hypercalcemia of Malignancy (HM)

■ J. Lee Talbott, DVM, DACVIM (Medical Oncology)

angell.org/oncology
oncology@angell.org
617-541-5136

Hypercalcemia of malignancy (HM) is one of the most commonly encountered paraneoplastic syndromes in veterinary medicine. HM is the inappropriate elevation of ionized calcium as a result of underlying neoplasia. The elevation in calcium is typically related to an overproduction of a substance (i.e., peptides, hormones, etc.) that is not normally released within the body. Often, the paraneoplastic syndrome parallels the underlying cancer diagnosis and may be the first clinical sign observed in patients, as is the case with HM. Additionally, the clinical morbidity associated with HM is often greater than that associated with the primary tumor. Therefore, it is imperative that every clinician have an understanding and appreciation of HM for early cancer detection and therapy.

The most common cause of hypercalcemia in veterinary patients is neoplasia, accounting for hypercalcemia in approximately two-thirds of dogs^{1,2} and one-third of cats.³ There are several types of tumors associated with hypercalcemia, with the most common cause of HM being lymphoma (10-35% occurrence). Other tumor types include anal sac apocrine gland adenocarcinoma ($\geq 25\%$), multiple myeloma (20%), parathyroid tumors, mammary gland carcinoma, thyroid carcinoma, bone tumors, thymoma, squamous cell carcinoma, melanoma, primary lung tumors, and chronic lymphocytic leukemia.⁴ Other non-neoplastic differential diagnoses for hypercalcemia include chronic renal disease/failure, hypoadrenocorticism, hypervitaminosis D, and granulomatous disease.⁵

There is a variety of proposed mechanisms that cause HM, most notably ectopic production of parathormone (PTH) or PTH-related peptide (PTH-rp) by the tumor. The HM present in patients diagnosed with lymphoma and anal sac apocrine gland adenocarcinoma is most commonly associated with increased production of PTH-rp by the tumor. PTH-rp is a 16-kDa protein with significant sequence homology to PTH; therefore, it acts and functions in a similar fashion to PTH in order to increase serum calcium. Other mechanisms that cause

HM include extensive and multifocal osteolytic metastases, tumor-associated prostaglandins, interleukin-1 β (IL-1 β , previously known as osteoclast-activating factor [OAF]), transforming growth factor- β (TGF- β), and receptor activator of nuclear factor kappa-B ligand (RANKL).^{5,6}

CLINICAL SIGNS

Dogs with HM often present with signs due to renal function impairment that begins as a decreased ability to concentrate urine, then progresses to polyuria (PU), polydipsia (PD), and progressive dehydration. This inability to concentrate urine is the direct effect of elevated serum calcium at the level of the distal tubule, decreasing its responsiveness to antidiuretic hormone (ADH). Other renal effects include decreased renal blood flow and glomerular filtration rate (GFR) as a result of severe vasoconstriction, and sometimes changes to the urothelium that may cause exposure of the basement membrane of the renal tubule. In addition to changes observed within the renal system, systemic clinical signs in more severely hypercalcemic patients may include twitching, shaking, weakness, depression, vomiting, anorexia, constipation, hypertension, arrhythmias, bradycardia, stupor, coma, and/or death.⁵ It is less common for cats to exhibit PU, PD, and weight loss as a result of hypercalcemia.

DIAGNOSIS

The diagnosis of hypercalcemia is made by documenting the presence of elevated ionized calcium (iCa), the biologically active fraction of calcium. The author's current recommendation is to perform an ionized calcium test in those cases with elevated total serum calcium (tCa), as well as those cases where neoplasia is strongly suspected and the tCa is normal. This is because there are newer reports of discordance between tCa and iCa measurements. The author advises against using formulas to correct the total serum calcium to the total protein or albumin, as these formulas do not accurately predict ionized calcium. Instead, we recommend referral to a hospital where an ionized calcium test can be performed. It is important to remember that severe lipemia or a hemolyzed sample (i.e., "lab error") may account for an elevated tCa in patients.⁷

Following a diagnosis of hypercalcemia, appropriate steps should be taken for identification of the underlying neoplasm. A thorough physical exam including a rectal exam is imperative to evaluate the anal sac glands. Additional diagnostics including a minimum database (CBC, chemistry [if not already performed], urinalysis), thoracic radiographs, abdominal ultrasound, +/- fine needle aspirates, and cytology of abnormalities noted are important to consider. Additional blood tests, such as a PTH and PTH-rp assays (typically part of a panel commonly performed at Michigan State University, called the hypercalcemia of malignancy panel) may be necessary during the diagnostic evaluation.

TREATMENT

Hypercalcemia of malignancy represents a potential medical emergency; therefore, identifying the underlying cause is vital to treatment of the specific tumor and resolution of the hypercalcemia. The most effective management of HM involves incorporation of aggressive supportive care to treat the hypercalcemia as well as treatment for the primary tumor.

The goal of symptomatic therapy is to use treatments that will promote renal excretion of calcium, increase external loss of calcium, and inhibit bone reabsorption. The duration of symptomatic therapy depends on the duration of ionized hypercalcemia in each patient, as well as the ability to identify and treat the primary neoplasm. It is the author's experience that with rapidly initiated aggressive therapy, the majority of patients show a dramatic reduction in the ionized calcium within 12 to 24 hours, with some patients having a normal iCa within three to five days. Resolution can take up to three to four weeks (for some) after treatment of the primary neoplasm; however, nearly all patients receiving symptomatic treatment feel better and have greatly improved clinical signs.

If the iCa is 1.6 mmol/L or greater, patients often exhibit clinical signs and treatment is recommended. Hospitalization is strongly recommended for any patient that has an iCa of ≥ 1.8 mmol/L. When the iCa is 2-2.2 mmol/L, the

MEDICAL ONCOLOGY

Continued from page 8

FIGURE 1

Serial iCa measurements from a patient with HM secondary to multiple myeloma. Dates are chronological from right to left. The iCa reference range is the far left column.

POC Nova Ionized Calcium		Final Report			
	Ref. Range/Males	7/26/2016 3:28 PM	7/11/2016 8:06 AM	7/10/2016 8:59 AM	7/9/2016 2:47 PM
N ICA	1.15-1.34 mmol/L	1.18	H 1.81	H 1.79	H 1.76

patient is often critically ill and showing systemic clinical signs (i.e., twitching, bradyarrhythmias, vomiting, anorexia), and hospitalization is required.⁷ It is the author's practice to recommend treatment for any patient showing clinical signs associated with hypercalcemia, regardless of how mild the elevated iCa may be.

The severity of clinical signs and associated hypercalcemia dictate the recommended therapy. While approximate lab values are provided below, each patient is considered based on their iCa and the type and severity of clinical signs present.

Mild HM with mild clinical signs (~1.6-1.8 mmol/L)

1. Intravenous (IV) fluids using 0.9% NaCl, administered for rehydration.

Moderate HM with clinical signs (~1.8 mmol/L or greater)

1. Intravenous (IV) fluids using 0.9% NaCl, administered for rehydration and diuresis.
2. Furosemide (Lasix®): 1-4 mg/kg every 8-24 hours, IV or PO.
 - a. After patient has been adequately hydrated.
3. Prednisone: 1 mg/kg PO SID to BID
 - a. After diagnosis has been obtained, ideally.

Severe HM with severe clinical signs; an oncologic emergency (~1.9 mmol/L or greater)

1. Intravenous (IV) fluids using 0.9% NaCl, administered for rehydration and diuresis.
2. Furosemide (Lasix®): 1-4 mg/kg every 8-24 hours, IV or PO.
 - a. After patient has been adequately hydrated.
3. Prednisone: 1 mg/kg PO SID to BID
4. Bisphosphonates
 - a. Pamidronate (Aredia®): 1-2 mg/kg IV (diluted in 0.9% NaCl), administered over 2 hours, as often as once per month.
 - b. Zoledronate (Zometa®): 0.1-0.25 mg/kg IV, administered over 15 minutes, as often as once per month.
5. Salmon calcitonin

- a. This can be reserved for severe refractory cases; however, is rarely necessary with treatment using the above therapies and treatment of the underlying neoplasm.

The use of normal saline is recommended for treatment of existing dehydration, expansion of the extracellular fluid volume, increasing GFR, increasing calciuresis, and decreasing calcium reabsorption by the kidneys. Furosemide is used in conjunction with normal saline diuresis to potentially inhibit calcium reabsorption in the ascending loop of Henle. Corticosteroids are best used following a diagnosis of HM, as they are extremely effective to reduce hypercalcemia by inhibition of prostaglandins, OAF, vitamin D, and intestinal calcium absorption.⁵

Bisphosphonates are often used in treatment of severe hypercalcemia or those cases refractory to supportive care and/or treatment of the underlying neoplasm. Bisphosphonates are synthetic analogs of inorganic pyrophosphates that were originally used for diagnostic purposes in bone scanning; however, they possess bone protective effects exerted through induction of osteoclast apoptosis. This results in diminished bone resorption with subsequent reductions in serum calcium levels.^{8,9} Although the use of bisphosphonates is the standard of care for human oncology patients with HM, further research is necessary to determine if single-agent bisphosphonates are as effective in veterinary patients. Until then, the best use of bisphosphonates for patients with HM is alongside adjuvant therapies (i.e., glucocorticoids, loop diuretics) that minimize renal tubular calcium reabsorption.⁹

Figure 1 shows serial iCa measurements from a canine patient that was diagnosed with HM on 7/9/16. The definitive diagnosis of multiple myeloma was made on 7/11/16, at which point definitive treatment was initiated using chemotherapy. Within 14 days (7/26/16), the iCa was within normal limits and the patient was significantly clinically improved. This patient received initial treatment with saline diuresis, prednisone, furosemide, and a single Zoledronate infusion, as well as treatment with chemotherapy (Melphalan), starting 7/11/16.

PROGNOSIS

Ultimately, the prognosis associated with HM is directly related to early identification of the underlying cause and rapid initiation of supportive therapy, as well as treatment of the primary tumor. The great majority of patients with HM, when treated rapidly and appropriately, can become normocalcemic and experience resolution of clinical signs and ultimately an improved quality of life.

For more information, please contact **Dr. Lee Talbott** at the **Angell Oncology Service** at 617-541-5136 or oncology@angell.org.

REFERENCES:

- 1 Uehlinger, P; Glaus, T; Hauser, B; et al. Differential diagnosis of hypercalcemia: A retrospective study of 46 dogs. *Schweiz Arch Tierheilkd* 1998; 140(5): 188-197.
- 2 Elliot, J. Hypercalcemia in the dog: A study of 40 cases. *J Small Anim Pract* 1991; 32: 564-567.
- 3 Savary, KC; Price, GS; and Vaden, SL. Hypercalcemia in cats: A retrospective study of 71 cases (1991-1997). *J Vet Intern Med* 2000; 14(2): 184-189.
- 4 Messinger, JS; Windham, WR; and Ward, CR. Ionized hypercalcemia in dogs: A retrospective study of 109 cases (1998-2003). *J Vet Intern Med* 2009; 23(3): 514-519.
- 5 Bergman, PJ. Paraneoplastic syndromes. *Small Animal Clinical Oncology* 2013; 5th ed. Elsevier; 83-86.
- 6 Weir, EC; Burtis, WJ; Morris, CA; et al. Isolation of 16,000-dalton parathyroid hormone-like proteins from two animal tumors causing humoral hypercalcemia of malignancy. *Endocrinology* 1988; 123(6): 2744-2751.
- 7 de Brito Galvao, JF; Schenck, PA; and Chew, DJ. A quick reference on hypercalcemia. *Vet Clin Small Anim* 2016; 1-8.
- 8 Fan, TM. Pain management in veterinary patients with cancer. *Vet Clin Small Anim* 2014; 44: 989-1001.
- 9 Fan, TM. The role of bisphosphonates in the management of patients that have cancer. *Vet Clin Small Anim* 2007; 37: 1091-1110.



Subcutaneous Ureteral Bypass (SUB™) for the Treatment of Ureteral Obstruction in Cats

■ Sue Casale, DVM, DACVS

Angell Animal Medical Center
surgery@angell.org
617-541-5048

Ureteral obstruction is becoming increasingly more common in veterinary patients and can occur for a variety of reasons.^{1,2} Although obstruction may be extraluminal (accidental ligation, compression from mass) or intramural (neoplasia, polyps, ureterocele), the most common type of ureteral obstruction is intraluminal due to calculi.^{3,4} Ureteral obstruction is seen more commonly in cats than dogs, which may be due to the small size of the feline ureter as well as the high likelihood that their calculi are composed of calcium oxalate, which cannot be dissolved medically. A majority of the ureteroliths seen in veterinary patients are composed of calcium oxalate, and in cats the incidence has been reported as high as 98%.²

Dogs with ureteral obstruction often present with urinary signs such as hematuria, pollakiuria, polyuria, and stranguria, while cats tend to have more nonspecific signs.⁴ Lethargy, anorexia, weight loss, and vomiting may accompany urinary signs or may be the only presenting signs.⁴ This can make diagnosis difficult and will often delay surgical intervention. Azotemia is a common finding and is present in 83% of cats and 50% of dogs with unilateral obstruction.² Anemia (cats), hyperphosphatemia, and hyperkalemia are also typical. Infection is more common in dogs than cats. Radiographs may show ureteral and renal calculi; however, abdominal ultrasound is the primary method used for diagnosis and should be performed on all patients with a suspected ureteral obstruction.⁵ Advanced imaging such as CT excretory urography is standard for humans, but in veterinary patients, ultrasound has similar sensitivity for ureteral dilation as CT and is more widely available.⁴

Ureteral obstruction may be partial or complete. Complete ureteral obstruction requires emergent treatment because of the risk of permanent damage to the kidney. Following complete unilateral ureteral obstruction, renal blood flow gradually declines, and by two weeks post-obstruction, renal blood flow is only 20% of normal.⁶ Glomerular filtration rate (GFR) decreases in the affected kidney and increases in the contralateral kidney. GFR can return to

FIGURE 1

▾ Subcutaneous Ureteral Bypass (SUB) device.

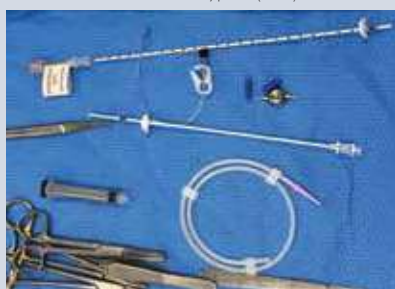

FIGURE 2

▾ SUB port and Huber (non-coring) needle.

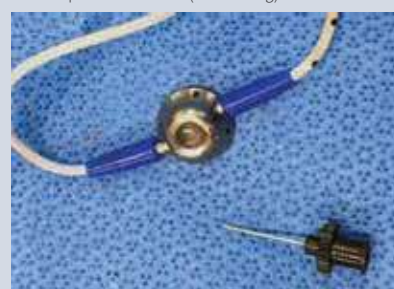

FIGURE 3

▾ The nephrostomy (top) and cystostomy (bottom) catheters during surgery.

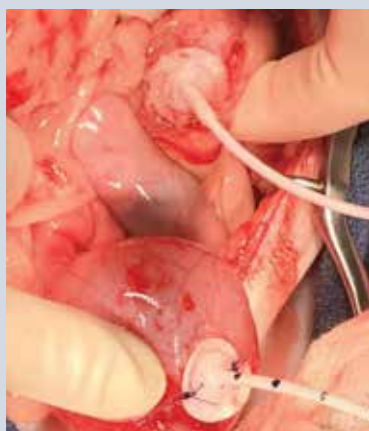
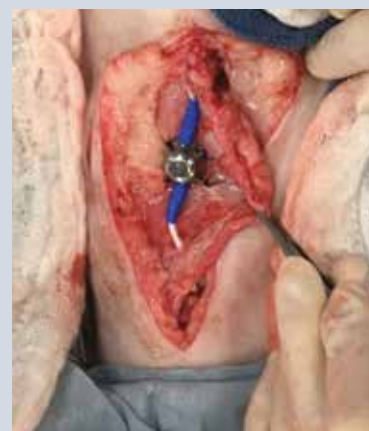
FIGURE 4

▾ The SUB port sutured subcutaneously to the body wall.



normal if the obstruction is relieved within four days.⁶ Once an obstruction has been present for two weeks, permanent damage occurs, and although GFR will improve after the obstruction has been relieved, it remains less than 50% of normal in previously healthy animals.⁶ In animals with preexisting renal disease, this damage may be even more severe. Partial obstruction also requires immediate medical attention even though hydronephrosis or hydronephrosis may not be present.³ Renal damage and decreased GFR still occur, although the damage is slower and less severe. Recovery from partial obstruction is more complete even

with delayed intervention. Experimentally, after four weeks of partial obstruction, GFR returned to normal once the obstruction was relieved.⁶

Medical management with aggressive IV fluids, mannitol CRI, alpha adrenergic blockade (tamsulosin), or smooth muscle relaxers (amitriptyline) may be attempted but fails in up to 90% of patients.^{3,7} Because management to encourage the obstruction to pass is rarely successful, calculi that are immobile based on repeated imaging traditionally require surgical removal.⁷ Surgical management includes ureterotomy, ureteroneocystostomy, pyelotomy,

SURGERY

Continued from page 10

or nephrectomy depending on the location of the obstruction. Ureterotomy is an extremely challenging surgery, especially in cats, and requires microsurgical training, surgical loupes, or an operating microscope.⁴ Urinary diversion with a nephrostomy tube is not recommended in cats because of a high complication rate, with 25% of cats developing a postoperative uroabdomen in one study.⁷ Complication (>30%) and mortality rate (>20%) with surgery is high and re-obstruction is common, with up to 40% of cats experiencing a recurrence due to either continued urolithiasis or stricture formation.^{7,8,9}

Ureteral stenting with a double pigtail stent has been reported and can be considered.¹⁰ Stents are placed either retrograde using cystoscopic guidance, antegrade through the renal pelvis, or surgically.³ Success appears to be very good in dogs, but the procedure is technically challenging in cats due to the small size of the feline ureter.^{11,12,13} The perioperative complication rate with stents is lower than ureteral surgery (10-14%), but long-term complications are high, with dysuria (17-35%), urinary tract infections (20%), recurrent obstruction (22%), and stent migration (5%) being the most common.^{3,14,15}

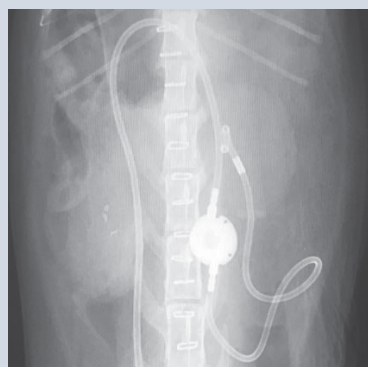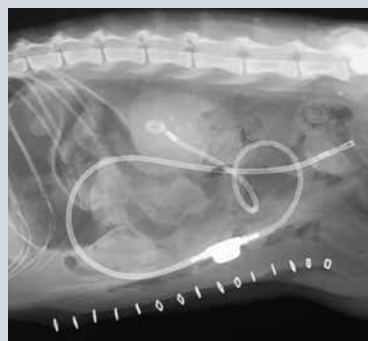
The newest technique to treat ureteral obstruction is the subcutaneous ureteral bypass (SUB™) system.^{3,12} Developed over 10 years ago based on a subcutaneous nephrovesical bypass used in human urology, the SUB device has shown improved outcome and decreased complications in cats when compared to ureteral stents.^{13,16,17,18} The SUB device consists of placement of a locking loop nephrostomy catheter within the renal pelvis and a cystotomy catheter within the bladder. The two catheters are connected by a port that is placed subcutaneously.¹⁸ The port is easily palpated under the skin and is accessed with a Huber needle to prevent coring. Urine can be easily sampled, and the system can be checked/flushed to minimize the risk of the catheters becoming occluded. The nephrostomy catheter is a 6 French pigtail catheter that is placed into the renal pelvis with or without fluoroscopic guidance.^{18,19} A dacron cuff is glued to the renal capsule to prevent leakage and to secure the catheter in place. The bladder catheter also has a dacron cuff that is both glued and sutured to the urinary bladder.¹⁸ The SUB is available in both a single port for unilateral obstruction and a three-way PantsPort™ for bilateral obstruction. The PantsPort allows a nephrostomy tube from each kidney to drain into a single cystotomy catheter.¹⁸

Complications are rare but include leakage (<5%) in the immediate postoperative period from the nephrostomy catheter, the cystotomy

catheter, or the port attachment, kinking of the device (<3%) and obstruction of the SUB (15-20%) with debris/stones/blood clots.^{13,20} The rate of postoperative obstruction is decreased with regular flushing of the device.¹⁸ Dysuria, which is the most common long-term complication seen with the double pigtail stent, is rare after SUB placement (<5%).¹³ Regular postoperative maintenance of the SUB is necessary. The device should be flushed under ultrasound or fluoroscopic guidance to avoid over-distention of the renal pelvis every three to six months to confirm patency of the device.¹⁸ A urine sample, which is easily obtained at the time of flushing, should be submitted for culture.¹⁸

FIGURES 5 & 6

Post-operative radiographs showing SUB placement



Excellent results were reported for a series of 137 cats that had SUB placement for ureteral obstruction.²¹ Over 93% of the cats survived to discharge.²¹ Renal pelvis dilation resolved and improvement in azotemia was seen. In one study, creatinine levels dropped 77.3% between admission and discharge from the hospital.¹⁹ Cats with more severe renal disease have worse long-term survival rates.²⁰ Owner satisfaction following the SUB procedure is high (>90%).¹⁹ We have been implanting SUB devices at Angell Animal

Medical Center for over two years with good success. It has quickly become our preferred treatment for cats with ureteral obstruction. The SUB device can also be used in dogs for treatment of ureteral obstruction that cannot be treated with stents or traditional surgery.

For more information about **Angell's Surgery Service**, please visit angell.org/surgery. **Dr. Casale** can be reached at **617-541-5048**, or by emailing scasale@angell.org or surgery@angell.org.

REFERENCES:

- 1 Cannon, AB; Westropp, JL; Ruby, AL; and Kass, PH. Evaluation of trends in urolith composition in cats: 5,230 cases (1985-2004). *J Am Vet Med Assoc* 2007; 231(4): 570-576.
- 2 Kyles, AE; Hardie, EM; Wooden, BG; Adin, CA; et al. Clinical, clinicopathologic, radiographic, and ultrasonographic abnormalities in cats with ureteral calculi: 163 cases (1984-2002). *J Am Vet Med Assoc* 2005; 226(6): 932-936.
- 3 Berent, AC. Ureteral obstructions in dogs and cats: A review of traditional and new interventional diagnostic and therapeutic options. *J of Vet Emerg Critical Care* 2011; 21(2): 86-103.
- 4 Hardie, EM, and Kyles, AE. Management of ureteral obstruction. *Vet Clin North Am Small Anim Pract* 2004; 34: 989-1010.
- 5 Palm, CA, and Culp, WTN. Nephroureteral obstructions: The use of stents and ureteral bypass systems for renal decompression. *Vet Clin North Am Small Anim Pract* 2016; 46: 1183-1192.
- 6 Wen, JG; Frokiaer, J; Jorgensen, TM; et al. Obstructive nephropathy: An update of the experimental research. *Urol Res* 1999; 27: 29-39.
- 7 Kyles, AE; Hardie, EM; Wooden, BG; Adin, CA; et al. Management and outcome of cats with ureteral calculi: 153 cases (1984-2002). *J Am Vet Med Assoc* 2005; 226(6): 937-944.
- 8 Roberts, SF; Aronson, LR; and Brown, DC. Postoperative mortality in cats after ureterolithotomy. *Vet Surg* 2011; 40: 438-443.
- 9 Garcia de Carellan Mateo, A; Brodbelt, D; Kulendra, N; and Alibhai, H. Retrospective study of the perioperative management and complications of ureteral obstruction in 37 cats. *Vet Anaesth Analg* 2015; 42: 570-579.
- 10 Manassero, M; Decambon, A; Viateau, V; Bedu, AS; et al. Indwelling double pigtail ureteral stent combined or not with surgery for feline ureterolithiasis: Complications and outcome in 15 cases. *J Fel Med Surg* 2014; 16(8): 623-630.
- 11 Kuntz, JA; Berent, AC; Weisse, CW; and Bagley, DH. Double pigtail ureteral stenting and renal pelvic lavage for renal-sparing treatment of obstructive pyonephrosis in dogs: 13 cases (2008-2012). *J Am Vet Med Assoc* 2015; 246(2): 216-225.

(CONTINUED ON PAGE 12)

SURGERY




Continued from page 11

- 12 Berent, AC. Interventional radiology and interventional endoscopy of the urinary tract ('endourology'). *J Fel Med Surg* 2014; 16: 51-65.
- 13 Berent, AC. Treatment of feline ureteral obstructions: Stents versus SUBs – the last 10 years of experience. *Proceedings of ACVIM*, Denver CO, 2016.
- 14 Kulendra, NJ; Syme, H; Benigni, L; and Halfacree, Z. Feline double pigtail ureteric stents for management of ureteric obstruction: Short-and long-term follow-up of 26 cats. *J Fel Med Surg* 2014; 16: 985-991.
- 15 Wormser, C; Clarke, DL; and Aronson, LR. Outcomes of ureteral surgery and ureteral stenting in cats: 117 cases (2006-2014). *J Am Vet Med Assoc* 2016; 248(5): 518-525.
- 16 Schmidbauer, J; Kratzik, C; Klinger, HC; et al. Nephrovesical subcutaneous ureteric bypass: Long-term results in patients with advanced metastatic disease – improvement of renal function and quality of life. *Eur Urol* 2006; 50: 1073-1078.
- 17 Komiakov, BK; Guliev, BG; El'-Attar, TKh; et al. Subcutaneous nephrovesical bypass in ureteral obstruction. *Urologiia* 2009; 5: 3-8.
- 18 Berent, A, and Weisse, C. Subcutaneous ureteral bypass system: A surgical guide. Norfolk Vet Products, Skokie IL.
- 19 Livet, V; Pillard, P; Goy-Thollot, I; Maleca, D; et al. Placement of subcutaneous ureteral bypasses without fluoroscopic guidance in cats with ureteral obstruction: 19 cases (2014-2016). *J Fel Med Surg* 2016; 18: 1-10.
- 20 Horowitz, C; Berent, A; Weisse, C; Langston, C; and Bagley, D. Predictors of outcome for cats with ureteral obstructions after interventional management using ureteral stents or a subcutaneous ureteral bypass device. *J Fel Med Surg* 2015; 15(12): 1052-1062.
- 21 Berent, AC; Weisse, C; and Bagley, D. Subcutaneous ureteral bypass device placement for benign ureteral obstruction in cats: 137 cats (174 ureters). *Proceedings of ACVIM*, Denver CO, 2016.

➤ ANGELL AT NASHOBA: LOW COST CARE FOR FINANCIALLY QUALIFIED CLIENTS

In 2016, Angell Animal Medical Center and Nashoba Valley Technical High School partnered to create **Angell at Nashoba**, a veterinary clinic for low income pet owners that also serves as a rigorous academic and experimental training program for students enrolled at Nashoba Valley Technical High School.

The clinic provides discounted:

-  Spay/neuter services
-  Vaccinations
-  Primary veterinary care

Open weekdays from 7:45am-4:00pm throughout the year, the clinic does not provide overnight care, specialty service care, nor 24/7 emergency service as Angell's Boston and Waltham facilities do, but will refer cases as appropriate to surrounding specialty veterinary referral hospitals.

To reach the clinic, please call **978-577-5992**. The clinic is located at: 100 Littleton Road, Westford, Massachusetts. For more information, visit angell.org/nashoba.





➤ Medical Director Dr. Laurence Sawyer provides routine care to two Ragdoll cats.



➤ ANGELL IS FIRST IN NEW ENGLAND TO UPGRADE TO STEREOTACTIC RADIATION THERAPY

The Oncology service at Angell Animal Medical Center is excited to announce we have upgraded our radiation therapy delivery unit. Our new system is a Varian TrueBeam, which allows Angell Animal Medical Center to continue delivering 3-dimensional conformal and intensity modulated radiation therapy (IMRT). In addition, **Angell is the first site in New England to offer stereotactic radiation therapy for our patients.**

Stereotactic radiation therapy is a newer form of advanced radiation technology that uses highly conformal and focused irradiation beams directed precisely at a tumor volume. This technology has several proposed advantages over traditional fractionated radiation therapy including:


-  Reduced side effects
-  Fewer anesthetic events
-  Sparing normal tissue is accomplished by avoidance of normal tissue structures (vs. delivering smaller doses of fractions over a course of therapy that uses traditionally fractionated radiation)
-  Fewer doses (e.g., traditional delivery schemes for heart base tumors involve 18-20 doses vs. 3-5 doses of stereotactic radiation)

Uses: In veterinary medicine there are multiple publications advocating the use of stereotactic radiation therapy in conditions such as brain tumors, osteosarcoma, nasal tumors, heart base tumors, injection site sarcomas and oral squamous cell carcinoma.

Stereotactic radiation therapy can also be used in a palliative setting to maintain tumor control and quality of life.

For more information on Angell's Oncology services and team, please visit angell.org/oncology. Profiles of Lyndsay Kubicek, DVM, DACVR (Radiation Oncology), Mairin Miller, DVM, and J. Lee Talbot, DVM, DACVIM (Medical Oncology) are available at angell.org/vets. The Oncology service can be reached at 617-541-5136 or oncology@angell.org.

➤ Drs. Lyndsay Kubicek (top), Mairin Miller (middle) and J. Lee Talbot (bottom) of Angell's Oncology service.



STAFF DOCTORS AND RESIDENTS

■ We encourage you to contact Angell's specialists with questions.

Main Phone: 617-522-7282 (Boston) | 781-902-8400 (Waltham) | Veterinary Referrals: 617-522-5011 | Angell at Nashoba: 978-577-5992

CHIEF OF STAFF

Ann Marie Greenleaf, DVM, DACVECC
agreenleaf@angell.org

24-HOUR EMERGENCY & CRITICAL CARE MEDICINE, BOSTON

Kiko Bracker, DVM, DACVECC
Service Co-Director
kbracker@angell.org

Kate Dorsey, DVM
kdorsey@angell.org

Roxanna Khorzad, DVM
rkhorzad@angell.org

Caitlin Koontz, DVM
ckoontz@angell.org

William (Glenn) Lane, DVM
wlane@angell.org

Beth Lieblick, DVM
blieblick@angell.org

Ashley Lockwood, DVM
alockwood@angell.org

Hannah Marshall, DVM
hmarshall@angell.org

Susan Magestro, DVM
smagestro@angell.org

Emiliana Meroni, DVM
emeroni@angell.org

Virginia Sinnott, DVM, DACVECC
vsinnott@angell.org

Megan Whelan, DVM, DACVECC, CVA
Service Co-Director
mwhelan@angell.org

24-HOUR EMERGENCY & CRITICAL CARE MEDICINE, WALTHAM

Lauren Baker, DVM
lbaker@angell.org

Alyssa Blaustien, VMD
ablaustein@angell.org

Jordana Fetto, DVM
jfetto@angell.org

Emily Finn, DVM
efinn@angell.org

Amanda Lohin, DVM
alohin@angell.org

Kate Mueller, DVM
kmueller@angell.org

Courtney Peck, DVM, DACVECC
cpeck@angell.org

Jessica Seid, DVM
jseid@angell.org

Susan Smith, DVM
ssmith@angell.org

Catherine Sumner, DVM, DACVECC
Chief Medical Officer
csumner@angell.org

Yao Yao, VMD
yyao@angell.org

ANESTHESIOLOGY

Stephanie Krein, DVM, DACVAA
skrein@angell.org

Kate Cummings, DVM, DACVAA
kcummings@angell.org

AVIAN & EXOTIC MEDICINE (W/B)

Brendan Noonan, DVM, DABVP (Avian Practice)
bnoonan@angell.org

Patrick Sullivan, DVM
psullivan@angell.org

Elisabeth Simone-Freilicher, DVM, DABVP (Avian Practice)
esimonefreilicher@angell.org

Anne Staudenmaier, VMD
astaudenmaier@angell.org

BEHAVIOR (W/B)

Terri Bright, Ph.D., BCBA-D, CAAB
tbright@angell.org

CARDIOLOGY (W/B)

Katie Hogan, DVM, DACVIM (Cardiology)
khogan@angell.org

Ashley Lange, DVM
alange@angell.org

Nancy Laste, DVM, DACVIM (Cardiology)
Director of Medical Services
nlaste@angell.org

Julia Lindholm, DVM
jlindholm@angell.org

Rebecca Malakoff, DVM, DACVIM (Cardiology)
(Waltham)
rmalakoff@angell.org

Natalie Morgan, DVM
nmorgan@angell.org

Rebecca Quinn, DVM, DACVIM (Cardiology and Internal Medicine)
rquinn@angell.org

DENTISTRY

Erin Abrahams, DVM
eabrahams@angell.org

Jessica Riehl, DVM, DAVDC
jriehl@angell.org

DERMATOLOGY

Klaus Loft, DVM
keloft@angell.org

DIAGNOSTIC IMAGING*

Naomi Ford, DVM
nford@angell.org

Steven Tsai, DVM, DACVR
stsai@angell.org

Ruth Van Hatten, DVM, DACVR
rvanhatten@angell.org

INTERNAL MEDICINE (W/B)

Daniela Ackley, DVM, DACVIM (Waltham)
dackley@angell.org

Alyssa Bryce, DVM
abryce@angell.org

Douglas Brum, DVM
dbrum@angell.org

Maureen Carroll, DVM, DACVIM
mccarroll@angell.org

Zach Crouse, DVM, DACVIM
zcrouse@angell.org

Erika de Papp, DVM, DACVIM
edepapp@angell.org

Jean Duddy, DVM
jduddy@angell.org

Kirstin Johnson, DVM, DACVIM
kcjohnson@angell.org

Lisa Gorman, DVM, DACVIM
lgorman@angell.org

Shawn Kearns, DVM, DACVIM
skearns@angell.org

Evan Mariotti, DVM
emariotti@angell.org

Susan O'Bell, DVM, DACVIM
Service Director
sobell@angell.org

NEUROLOGY (W/B)

Rob Daniel, DVM, DACVIM (Neurology)
rdaniel@angell.org

Michele James, DVM, DACVIM (Neurology)
(Boston & Waltham)
mjames@angell.org

Jennifer Michaels, DVM, DACVIM (Neurology)
(Boston & Waltham)
jmichaels@angell.org

STAFF DOCTORS AND RESIDENTS

NUTRITION

Dana Hutchinson, DVM, DACVN
dhutchinson@angell.org

ONCOLOGY

Lyndsay Kubicek, DVM, DACVR
(Radiation Oncology)
lkubicek@angell.org

Mairin Miller, DVM
mmiller@angell.org

J. Lee Talbott, DVM, DACVIM
(Medical Oncology)
jtalbott@angell.org

OPHTHALMOLOGY

Daniel Biros, DVM, DACVO
dbiros@angell.org

Martin Coster, DVM, MS, DACVO
mcoster@angell.org

PAIN MEDICINE

Lisa Moses, VMD, DACVIM, CVMA
lmoses@angell.org

PATHOLOGY (CLINICAL & ANATOMIC)*

Patty Ewing, DVM, MS, DACVP
pewing@angell.org

Pamela Mouser, DVM, MS, DACVP
pmouser@angell.org

SURGERY (W/B)

Sue Casale, DVM, DACVS
scasale@angell.org

Michele Kudisch, DVM, DACVS
(Waltham)
mkudisch@angell.org

John Litterine-Kaufman, DVM
jlitterinekaufman@angell.org

Michael Pavletic, DVM, DACVS
mpavletic@angell.org

Meghan Sullivan, DVM, DACVS
msullivan@angell.org

Nicholas Trout, MA, VET MB, MRCVS,
DACVS, DECVS
ntrout@angell.org

Emily Ulfelder, BVetMed
eulfelder@angell.org

Spencer Yeh, DVM
(syeh@angell.org)

ANGELL AT NASHOBA

Laurence Sawyer, DVM
lsawyer@angell.org

(W/B) Services also available at our Waltham location

*Boston-based radiologists and pathologists serve both Boston & Waltham locations

Angell West is extremely pleased to announce that Lisa Gorman, DVM, DACVIM and Patrick Sullivan, DVM have joined their staff as of August 2017.



LISA GORMAN, DVM, DACVIM

Dr. Lisa Gorman is a Board Certified Internal Medicine Specialist. She earned her B.A. in Biology from Cornell University in 2007. Working with animals was always a priority, with summer jobs ranging from working with injured wildlife in Thailand to training service dog puppies. She then attended veterinary school at Washington State University, where she graduated with honors in 2011. Dr. Gorman moved back to the East Coast for her small animal rotating internship at the Animal Medical Center in

New York, and then moved to the Midwest for the first time in 2012 where she completed her residency in small animal internal medicine at the University of Minnesota before joining the staff at VCA Veterinary Referral and Emergency Center. Dr. Gorman is very excited to join Angell West and the Internal Medicine Staff this year.




PATRICK SULLIVAN, DVM


Dr. Patrick Sullivan has always had an interest in exotic animals, keeping several different species growing up. Upon finishing an undergraduate degree at Mount Ida College, he went on to receive his doctorate in veterinary medicine from St. George's University in 2009. After practicing in the Boston area for 4 years, Dr. Sullivan accepted a position as an Avian and Exotics intern at Angell Animal Medical Center in Boston. Following his internship, he completed an Avian & Zoological Medicine residency at


The University of Tennessee in Knoxville. During his residency, he was able to work with companion exotic animals, as well as zoo and native wild animals. Working with conservation groups provided him with the opportunity to treat American black bears, bald eagles and non-domestic felines such as tigers, lions, leopards, and mountain lions. Dr. Sullivan finished his residency in July of 2017 and was thrilled to be able to come back home to Massachusetts to join the team at Angell West. In his free time, he enjoys live music, following Boston sports, and traveling.

MSPCA-Angell West hospital services* currently include...


 24/7 EMERGENCY & CRITICAL CARE


 AVIAN & EXOTIC MEDICINE


 BEHAVIOR

 CARDIOLOGY

 INTERNAL MEDICINE

 NEUROLOGY

 PHYSICAL THERAPY

 SURGERY



Nonprofit Org.
 US Postage
 PAID
 Permit No. 1141
 Boston, MA

We mail one complimentary copy of our newsletter to each of our referring partners. Please circulate this copy within your practice.

Fall 2017 ■ Volume 11:3 ■ angell.org ■ facebook.com/AngellReferringVeterinarians

MSPCA-ANGELL
 350 South Huntington Avenue
 Boston, MA 02130
 617-522-5011
angell.org

MSPCA-ANGELL
 WEST
 293 Second Avenue
 Waltham, MA 02451
 781-902-8400
angell.org/waltham

ANGELL AT
 NASHOBA
 100 Littleton Road
 Westford, MA 01886
 978-577-5992
angell.org/nashoba

Please consider adding Angell's main numbers to your after-hours phone message.

■ angell.org/directions (free parking) ■ angell.org/hours ■ angell.org/ce

➤ PHYSICAL THERAPY NOW AVAILABLE AT ANGELL WEST

The MSPCA-Angell is pleased to announce the addition of Physical Therapy (PT) to our Waltham specialty services. In July of 2017, Angell acquired FlowDog, a canine aquatic fitness & rehabilitation center. This acquisition is instrumental to the comprehensive, personalized care Angell strives to provide to each and every patient.

The facility will continue to operate during its regular business hours at 96 Clematis Ave. in Waltham until February 2018, when the official location will shift to the MSPCA-Angell West building at 293 Second Avenue in Waltham.

Canine physical therapy is used to treat a wide variety of orthopedic and neurological conditions. Whether recovering from an injury, cross training, or facing mobility issues, dogs can substantially benefit from PT.

Current PT services include:

-  HYDROTHERAPY
-  LAND-BASED EXERCISE
-  MANUAL THERAPY
-  THERAPEUTIC LASER
-  MASSAGE
-  CONSULTATION AND FITTING OF ASSISTIVE DEVICES
-  UNDERWATER TREADMILL*
-  ACUPUNCTURE*

*Available as of February 2018 after relocation from 96 Clematis Ave. to 293 Second Ave. in Waltham. For more information, visit www.angell.org/PT.