



OPHTHALMOLOGY

PAGE 1
Navigating Corneal Ulcerative Disasters in Dogs

EMERGENCY AND CRITICAL CARE

PAGE 1
Eight Pediatric Myths – Busted

INTERNAL MEDICINE

PAGE 6
A Review of Three Clinically Impactful Journal Articles

DENTISTRY

PAGE 8
Pediatric Dentition and Malocclusions

NEUROLOGY

PAGE 10
Canine Intervertebral Disc Disease

TECH TIP

PAGE 14
Understanding Vascular Ring Anomalies



OPHTHALMOLOGY

Navigating Corneal Ulcerative Disasters in Dogs

Daniel Biro, DVM, DACVO
angell.org/eyes | ophthalmology@angell.org | 617-541-5095

The corneal ulcer condition represents a wide spectrum of disease, from the smallest surface abrasion to the total loss of corneal stroma leading to a complete descemetocele or corneal rupture. As such, the prognosis and treatment plans vary as much as all the different types of ulcerative corneal disease we see. Small injuries can heal with time and symptomatic treatment, while complicated disease requires weeks of treatment and possibly multiple surgeries to preserve the eye and vision. Wound repair of the cornea requires minimal scarring and structural integrity to avoid functional vision loss. Fortunately, in veterinary medicine,

we are not faced with the same rigors of vision demands by contrast to human vision needs, so there is some "wiggle room" to allow for scarring and partial vision loss. In general, steroids or NSAIDs in topical form should be avoided during the wound repair period and even afterward due to their collagenolytic activity. In humans, topical steroids and topical NSAIDs can reduce scarring and preserve visual acuity and cosmesis with judicious use during ulcer healing.

(CONTINUED ON PAGE 2)



EMERGENCY AND CRITICAL CARE

Eight Pediatric Myths – Busted

Virginia B. Sinnott-Stutzman, DVM, DACVECC
angell.org/emergency | emergency@angell.org | 617-522-7282

Many of the pearls of wisdom clinicians draw on when addressing pediatric emergencies come from advice from prior mentors, and "rules of thumb" that are often not evidence-based and frequently contain absolutes and maxims that are often incorrect when applied to various situations. The goal of this article is to reveal the nugget of truth in most myths, and dissect out the pathology or evidence behind those myths so that we can apply this wisdom with better skill in our practice.

MYTH #1: PUPPIES AND KITTENS ARE ANEMIC

While it is true that at some points during the first 12 weeks of life, it is normal for most puppies and kittens to have a packed cell volume (PCV) that would be considered anemic in an adult, it is not true that this is the case for the entire 12 weeks.

(CONTINUED ON PAGE 4)

OPHTHALMOLOGY

Navigating Corneal Ulcerative Disasters in Dogs

CONTINUED FROM PAGE 1

The broad points of care in every ulcerated cornea are addressing the primary cause of the ulcer, infection control, pain and inflammation management, and wound repair. These four priorities must be addressed in every patient. The acute treatment plan for severe ulcerative keratitis is often intense, and the monitoring necessary is usually daily. In some cases, recovery can take weeks to months, and medical treatment can be augmented by surgical repair and stabilization by referral in the most severe situations. Under certain conditions, relapse is a concern, especially in the most vulnerable, including brachycephalics, those with difficult-to-treat dry eye, and those suffering from canine ocular herpes, to name three examples.

There are six achievement goals on which we will focus to walk through the experience of managing complicated corneal ulcers:

- I. Create the environment for a safe and productive examination.
- II. Establish parameters of the wound area, including size and stability.
- III. Look for common problems that can create a severe ulcer.
- IV. Consider advanced diagnostics to speed the characterization of the condition and direct therapy.
- V. Put a definitive plan in place for monitoring and therapy adjustment, but be ready to adjust treatment on the go.
- VI. Educate the client on the realities of significant corneal disease, including discussions on outlook for vision and comfort. Set realistic expectations.

I. CREATE THE ENVIRONMENT FOR A SAFE AND PRODUCTIVE EXAMINATION

The essential part of a successful corneal examination lies in getting a good and long look at the ocular surface and the anterior chamber, evaluating the adnexa, and checking the vision status of the affected eye. Comfortable and secure manual restraint with the aid of systemic pain medication as needed (methadone, buprenorphine) will neutralize the patient's anxiety, and topical anesthesia is almost always implemented (e.g., proparacaine) when there is marked blepharospasm. If possible, take any ocular surface cultures prior to topical anesthetic since the topical drops may affect the culture results. Carefully wipe away any crusting or thick mucus to not cause significant disturbance to the cornea if it has or is near rupture. After the topical anesthetic has taken effect (up to 5 minutes for full effect lasting 30 minutes) and the cornea is not fully visible due to mucus, you may consider gently irrigating the surface area with saline to reveal the ocular surface. If blood or fibrin is suspected, care must be taken, indicating a leaking cornea or recent leak due to a full thickness perforation or puncture.

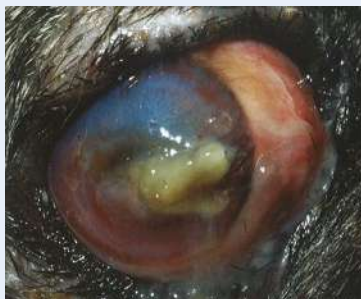II. ESTABLISH PARAMETERS OF THE WOUND AREA, INCLUDING SIZE AND STABILITY

Careful documentation of the wound will be essential to monitor progress and guide prognosis. Is it deep? What is the diameter or other dimensions of the surface area? Are the wound edges discrete or blurred? Is there any evidence of leaks? Can you visualize the anterior chamber, and is there any blood, fibrin, hypopyon, or synechiae abutting the corneal surface? Once the visualization of the cornea is possible, culture swabs should be gently taken and set aside if there are indications for it, such as stromal melting, especially if ulceration is superficial stromal or deeper. We often use cytology brushes (Microbrush brand) to test the stability of the corneal surface, briefly explore the depth or extent of corneal lacerations, dislodge superficial foreign bodies, and differentiate possible mucus from fibrin plugs. Photography is often helpful to document the wound over time, and with experience, estimating dimensions of wounds is a good practice to have some objective data in the medical record. Illustrations are also beneficial for characterizing the lesion and are done with every eye examination we do. If there is aqueous humor leakage suspected or if you suspect the eye will leak with any manipulation, then touching the tissue should be minimized until in a safe surgical setting or until the wound has stabilized sufficiently on its own with time and supportive care.

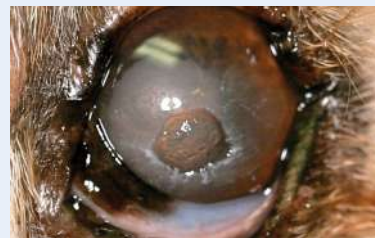III. LOOK FOR COMMON PROBLEMS THAT CAN CREATE A SEVERE ULCER

Once the patient is comfortable for evaluation and the wound area has been initially checked, a look around the injury is essential at better characterizing the conditions that may have led to the changes seen. With a good history, you may be inclined to look for other associated ocular

▶ Chronic severe deep stromal ulcerative keratitis, marked mucus build-up and probable iridocorneal apposition with virtual iris prolapse in a dog. Surgical grafting of this cornea with conjunctiva may stabilize the condition and provide the means for wound healing and globe preservation, but with extensive scarring and very limited vision. Enucleation of this globe with histopathology was ultimately elected for the most rapid recovery and pain management.



▶ Degenerative, mineralized stromal ulcerative keratitis with fragmental loss of corneal tissue leaving a deep structural defect in a dog. Not uncommon in older dogs and can present with varying degrees of pain, this type of corneal ulceration can be very slow to heal, but with adequate medical treatment and observation is typically much stronger structurally than melting corneal ulcers. This patient also has a concurrent anterior luxated cataract diminishing the prospects of improved vision with ulcer repair. Both surgical and medical treatment options can be suitable for degenerative ulcerative keratitis depending on the diameter and depth of the wound.



diseases, such as lagophthalmos, distichiae, ectopic cilia, dry eye, or foreign bodies that could be directly involved with the pathology. Some of these conditions can be addressed on the spot, while others may need long-term care. Remember, a Schirmer tear test will be lower in patients who have received topical proparacaine, so skip this test until the eye is more stable.

IV. CONSIDER ADVANCED DIAGNOSTICS TO SPEED THE CHARACTERIZATION OF THE CONDITION AND DIRECT THERAPY

The core ophthalmic tests for most eye exams include testing for a menace response, pupillary light reflexes, palpebral reflexes, Schirmer tear test, tonometry, fluorescein stain, and visualization of the eyelids, conjunctiva, cornea, anterior chamber, lens, and fundus (retina). In severe corneal disease, additional testing can also involve aerobic bacterial culture, fungal culture, cytology, Seidel testing for leakage of the aqueous humor through the cornea, and PCR testing for herpes. In an emergency situation, all tests may not be possible or indicated. However, in complicated corneal ulcers with chronic antibacterial treatment or rapid progression of the ulcer size and depth despite therapy, culture first (with an option for submission later on) and then cytology may be most helpful. Aerobic culture should be sufficient when looking at types of cultures to submit in New England, but fungal testing is warranted in some geographic areas (e.g., the South). Cytology can be Diff-Quik or Gram stain and done in a clinic or sent off to a cytologist. Seidel testing is a variation on the fluorescein test where the test strip is applied in contact briefly to an area of cornea suspected of leakage—whether an ulcer, a tear, or a surgical incision—leaving a concentrated area of fluorescein on the corneal surface, which is bright orange. If there

OPHTHALMOLOGY

Navigating Corneal Ulcerative Disasters in Dogs

CONTINUED FROM PAGE 2

is a leak, the orange quickly changes to green, and often the green streaks that result in a leaking cornea will track the course of the aqueous humor along the ocular surface. Keep the eyelids open for good test results as fluid from tears or even eyewash causes the same type of dilution. The patient has to be very still to interpret the test correctly, and any excess mucus or fluid on the ocular surface rinsed away to get the best view of the test.

V. PUT A DEFINITIVE PLAN IN PLACE FOR MONITORING AND THERAPY ADJUSTMENT, BUT BE READY FOR ADJUSTING TREATMENT ON THE GO

Treatment plans for severe corneal ulcers are often quite labor-intensive. In melting ulcers, recommendations of up to three meds hourly for several days are one standard approach to reverse the rapid melting process and save the eye. By now, cultures and cytology are turned in and there are likely CBC and chemistry panel results that will help focus the options for systemic care. In specialty care clinics with 24-hour services, round-the-clock care can be offered to lessen the burden of care and allow the clients to get some sleep. Ensuring the patient's anxiety is as low as possible will also help them take the medication without the added problems of nausea, inappetence, high blood pressure, or aggression. Unless there is a high risk from anesthesia, surgical stabilization by referral with conjunctival grafting is often offered when the ulceration is large, deep, or actively leaking and the leak is no larger than 5 to 7 millimeters. Risks for graft failure increase with a larger injury (requiring a larger graft), but recent advancements in grafting options, including amniotic membrane, synthetic, or biological collagen implants over the wound area; collagen cross-linking; and even corneal transplants in certain situations are used to save an eye that would otherwise be lost to medical therapy alone, or that would significantly accelerate the wound healing process. If possible, there is also the benefit of stabilizing the cornea with medication for

up to 24 to 48 hours before moving to surgical correction of the corneal ulcer. Grafts fail when the inflammation is profound, and the grafts succumb to neutrophilic digestion. However, with a few days of anti-inflammatory and antibiotic care, the surgical field can become more stable and accept grafts.

During hospitalization, we will often use ofloxacin, cefazolin (compounded to 55 mg/ml in bacteriostatic water-refrigerated-good for at least two weeks), and whole serum diluted up to 25-50% with artificial tears up to every hour for up to three to four days to start intensive treatment for a melting ulcer. Then we taper down to a frequency that the clients can handle at home once the wound is showing signs of repair. Atropine use can be very helpful, especially if the uveitis is profound, and can be used up to four to six times daily to dilate the pupil at the onset of treatment, but then tapered to the lower effective frequency to sustain dilation, often one to two times daily. If profound uveitis with hyphema or hypopyon, systemic antibiotics are suitable to reach therapeutic intraocular concentrations. Systemic pain medication includes carprofen and gabapentin. We also will use methadone, meloxicam, and other options depending on the patient's weight and history with these drugs. Trazadone can also be helpful if there is high anxiety, and cerenia or similar is often used during hospitalization if there is any perceived risk for nausea. When to send a healing ulcer for home care depends on what the pet owner can do and how stable the pet is. In general, we like to string together two to three successive days of improvement, feel confident the wound will not destabilize, and try to get the treatments down to at most every four to six hours.

VI. EDUCATE THE CLIENT ON THE REALITIES OF SIGNIFICANT CORNEAL DISEASE, INCLUDING THE OUTLOOK FOR VISION AND COMFORT. SET REALISTIC EXPECTATIONS.

Despite the best intentions of intensive medical therapy, some patients are poor responders, and if we do not see improvement in three to four days at the latest, we will discuss options in replacement of or in addition to the medical therapy already implemented. Obvious cases that would have us consider surgical referral immediately would be those where the cornea is already perforated or perforation is imminent. Descemetocoeles and deep ulcers also are considered for the fast track to surgical referral if the patient is stable and the goal of care will enable the preservation of some vision—or just keeping the eye knowing it will be blind if the client is averse to enucleation. If the cornea is beyond repair, considering both surgery and medication options, we can offer enucleation as the humane course of therapy for the severest cases to alleviate pain and speed the recovery quickly. For some, the financial costs are too strenuous for intensive medical care, and the clients are not equipped to treat at home to meet the patient's needs. However, if they are willing to do the best they can at home, nothing is

lost if the client wants to treat intensively at home to the best of their ability with reasonable rechecks every day. Initial testing and evaluation for a melting ulcer on emergency, including tests, cultures, and medication, can be upwards of \$800. If the patient stays for intensive eye care in the hospital, the cost can be up to \$500 per day. Urgent surgery to repair a severely damaged cornea can cost in the range of \$2,500 to \$3,500 for the surgery and post-op care alone.

SUMMARY

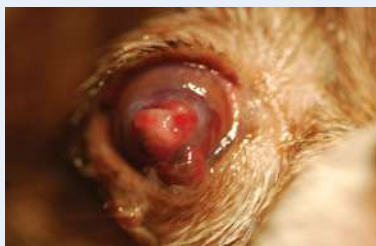Basic training in managing corneal ulceration does not always prepare one for dealing with advanced cases of corneal melting or large, deep ulcerative conditions. By considering additional steps in the path of diagnosing and treating ulcerative keratitis, some advanced cases may continue to have vision with ramped-up medical and/or surgical treatment by referral. The survival rate for serious corneal ulcers in dogs will be lower compared to patients with less severe ulcers, but with some adjustments to conventional therapy, many of these cases can stand a better chance to heal with functional vision.

At the time this newsletter is printing, Angell's Ophthalmology service is still unable to accept new patients to the service. While we hope staffing shortages will ease and soon allow us to once again accept new ophthalmology patients, our hope is to provide helpful treatment information in the meantime to address non-emergent cases at primary care clinics.

ADDITIONAL READING

- 1 Dan G. O'Neill, Monica M. Lee, Dave C. Brodbelt, David B. Church, and Rick F. Sanchez. Corneal ulcerative disease in dogs under primary veterinary care in England: epidemiology and clinical management. *Canine Genet Epidemiol.* 2017; 4: 5.
- 2 Pot SA1, Gallhöfer NS, Matheis FL, Voelter-Ratson K, Hafezi F, Spiess BM. Corneal collagen cross-linking as treatment for infectious and noninfectious corneal melting in cats and dogs: results of a prospective, nonrandomized, controlled trial. *Vet Ophthalmol.* 2014 Jul;17(4):250-60.
- 3 Ledbetter EC1, Franklin-Guild RJ2, Edelmann ML. Capnocytophaga keratitis in dogs: clinical, histopathologic, and microbiologic features of seven cases. *Vet Ophthalmol.* 2018 Nov;21(6):638-645.
- 4 Ledbetter EC1, Riis RC, Kern TJ, Haley NJ, Schatzberg SJ. Corneal ulceration associated with naturally occurring canine herpesvirus-1 infection in two adult dogs. *J Am Vet Med Assoc.* 2006 Aug 1;229(3):376-84.
- 5 Wilkie, David A. et al. Surgery of the Cornea. In *Veterinary Clinics: Small Animal Practice, Volume 27, Issue 5*, 1067 – 1107.
- 6 Ledbetter EC, Gilger BC. Diseases and surgery of the canine cornea and sclera. In: Gelatt KN, Gilger BC, Kern TJ, editors. *Veterinary Ophthalmology*, vol. 2. 5th ed. Oxford: Wiley-Blackwell; 2013. p. 976–1049.
- 7 Vanore M, Chahory S, Payen G, Clerc B. Surgical repair of deep melting ulcers with porcine small intestinal submucosa (SIS) graft in dogs and cats. *Vet Ophthalmol.* 2007;10(2):93–9.
- 8 Lacerda RP, Peña Gimenez MT, Laguna F, Costa D, Rios J, Leiva M. Corneal grafting for the treatment of full-thickness corneal defects in dogs: a review of 50 cases. *Vet Ophthalmol.* 2016;1–10.

➤ Profound chronic ulcerative keratitis with iris prolapse in a dog. There is total collapse of the anterior chamber and extensive inflammation and hemorrhage indicating complete loss of corneal structural integrity. The tissue incarcerated in the axial cornea is iris, vascularized, firm, amorphous, often with a blanched appearance and coated with mucus or fibrin and blood. Enucleation with histopathology was performed for treatment.



EMERGENCY AND CRITICAL CARE

Eight Pediatric Myths – Busted

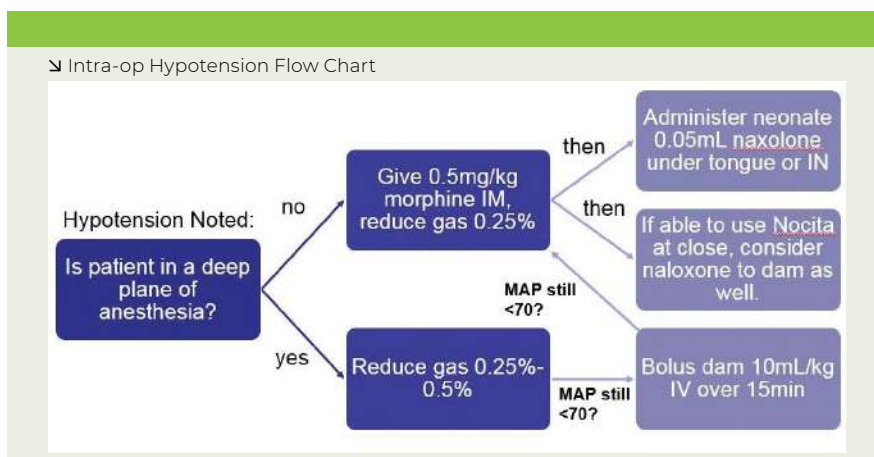
CONTINUED FROM PAGE 1

At birth, fetal red blood cells (RBCs) are larger and contain fetal hemoglobin (which has a greater affinity for oxygen than adult hemoglobin). At birth the bone marrow transitions to making adult hemoglobin and adult RBCs. Thus over the first 12 weeks for dogs and about 7 weeks for cats, as the fetal RBCs senesce and are replaced by adult (smaller) RBCs the red cell mass decreases. In addition, as the neonate grows, plasma volume expands faster than red cell mass can be produced, with the end result that PCV nadirs between 2-4 weeks for kittens and around 4 weeks for puppies. This is the truth behind the myth. However from birth through the first week of life (a time when quite a few neonates are presented to the emergency room) the PCV of both species is normal with the PCV on average being 47% for dogs at birth and 40% at 1 week and a PCV of 35% at birth for kittens that returns to the normal range by 6 weeks at an average of 30%. It's also important to point out that the data for dogs comes exclusively from beagles so PCVs may be lower in more rapidly growing large and giant breed dogs.



MYTH #2: NO OPIOIDS FOR C-SECTIONS

Many veterinarians performing C-sections avoid opioid analgesics because of the fear that it complicates resuscitation of the neonate. While this can be true when the opioid is given prior to removing the neonates from the uterus, fetal hypoxia due to hypotension from gas anesthetics can ALSO complicate resuscitation, so it is ill-advised to remove one of the most cardiovascular system-sparing drugs from our anesthetic armamentarium. The motto of C-section (or any) anesthesia is “be prepared” so adopting a step-wise protocol that incorporates opioids in the event of instability that cannot be reversed with fluids and reducing gas anesthetic is advisable. It is also important that that plan involve naloxone, usually administered sub-lingually, in the resuscitation plan for the pups.



MYTH #3: PROPOFOL IS THE SAFEST INDUCTION AGENT FOR C-SECTION

Since its invention, propofol has been the induction-agent of choice for unstable patients due to its rapid onset and metabolism. And while it is one of the safest choices, recent evidence suggest that alfaxalone may be a better choice. A 2013 study compared Apgar scores (a scoring system that grades the “liveliness” of newborns) between neonatal puppies delivered when induced with propofol and alfaxalone. The alfaxalone-induced puppies had higher Apgar scores at birth when compared to the propofol-induced puppies. While the difference faded at 4 hours, (and this would be expected as both drugs would be metabolized by then), in the case of very distressed fetuses, there may be a survival benefit and so in absence of other evidence or dam-specific needs, alfaxalone has become the go-to choice for induction of C-section at Angell.

MYTH #4: FETAL HEART RATE <160 IS ASSOCIATED WITH FETAL DISTRESS

This is one of those myths where theriogenologists shake their heads at the rest of us (myself included!). A normal fetal heart rate is >200/min so anything less than that is abnormal and most theriogenologists start considering a C-section when fetal heart rates approach 180/min. They do agree that fetal heart rates <160 do likely signal a C-section is needed, they just would have already been in surgery by then.

MYTH #5: DURING A C-SECTION, WHEN REMOVING THE PUPPY, CLAMP THE UMBILICAL CORD PRIOR TO HANDING IT TO A RESUSCITATOR

Recent literature suggests Apgar scores (a score of newborn liveliness that correlates with survival) are higher in puppies where the umbilical cord remains unclamped, and elevating the placenta for two to five minutes until placental blood drains into the fetus. This can be done either by the primary resuscitator (by placing the placenta on the back of your hand while you rub the pup) or by having a second assistant hold the placenta above the pup while the resuscitator continues rubbing/suctioning.

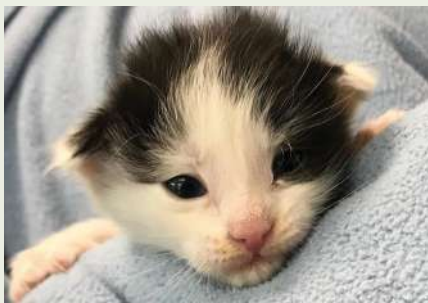MYTH #6: ONCE A C-SECTION, ALWAYS A C-SECTION

This myth has its roots in human medicine. It was once believed that the scar on a woman's uterus after C-section was too friable to allow for a vaginal birth. The fear was uterine rupture. Vaginal birth after C-section (VBAC) is now quite common. In addition, the anatomy of the dog and cat uterus is very different from a human uterus and so the risk of rupture was likely never as great for a dog or cat, so veterinarians risk losing the faith and trust of owners with this un-nuanced myth. If there are maternal-specific reasons for a dystocia such as previous pelvic injury or primary uterine inertia not due to hypocalcemia or hypoglycemia, then spay with C-section is reasonable, as long as the owner is warned that uterine rupture is still likely more likely than if the pet had not had a C-section. However if there is an extremely large fetus, or a deformed or deceased fetus with a viable litter of remaining puppies/kittens, not spaying is a reasonable choice, and should at least be open to discussion. Of course if there is a suspected genetic reason for needing a C-section, then spay should be performed at the time of C-section or planned for after the dam or queen recovers from birth.

EMERGENCY AND CRITICAL CARE

Eight Pediatric Myths – Busted

CONTINUED FROM PAGE 4



MYTH #7: OUTPATIENT PARVOVIRUS TREATMENT CARRIES A POOR PROGNOSIS

In the past, treating puppies with parvoviral enteritis on an outpatient (OP) basis seemed like a losing battle. A recent study out of Colorado State showed a similar survival rate between inpatient (IP) and simulated outpatient therapy (80% for OP and 90% for IP therapy). I suspect their success came from two fairly major changes to standard OP care. The first is that they used a very aggressive SQ fluid rate of 30ml/kg SQ q 6h (120mL/kg/day) and the other was that they used cefovecin as their antibiotic, providing 2-7 days of 100% T>MIC for the various GI pathogens that can cause sepsis. They also gave maropitant at 1mg/kg SQ daily. I believe this protocol is best employed if one of the SQ injections is given as a tech or doctor appointment so that a veterinary professional can evaluate the success of the regimen, answer any questions the owners have as they go, and ensure that at least one of the SQ injections is provided accurately per day. Some hospitals have a “package” that includes the supplies as well as 1 tech appointment a day to encourage the owners to return since they have already pre-paid for the tech appointment.

MYTH #8: YOU CAN'T USE BAYTRIL IN PUPPIES AND KITTENS

It is well known that all fluoroquinolones can cause apoptosis and delayed growth to cartilage cells. Animals given experimentally long and high doses of Baytril developed tendonopathies. However the microscopic lesions described in dogs on the package insert for Baytril were noted after 30 days of therapy. This is a very long antibiotic course. While fluoroquinolones are relatively contraindicated in animals undergoing their rapid growth phase, if such an animal experiences a life-threatening infection, there are plenty of consensus statements and guidelines that would support its use. The American Academy of Pediatrics stated in 2006, for example, that if there is a multi-drug resistant infection or a life-threatening infection or if it is the only oral option and parenteral administration is not feasible, it is permissible to use fluoroquinolones. At Angell, we pledge to use a de-escalation approach to antibiotic therapy when we prescribe Baytril to pediatric patients, meaning when using multidrug therapy, the Baytril will be discontinued as soon as the pet is not in a life-threatening state. We also discuss the risks with the owner and try to limit our courses of antibiotics. For example, recent evidences suggests two weeks or less of antibiotic therapy for pneumonia is as good as longer courses so we no longer adhere to the un-evidence based “continue antibiotics for two weeks past radiographic resolution of pneumonia” myth.

REFERENCES

- 1 Bird CE, Chapter 33: The hematologic and lymphoid systems. In: Peterson ME, Kutzler MA. Small Animal Pediatrics, the first 12 months of life. Elsevier, St. Louis, MO. 2011, pp 306-307. *This reference is an excellent one to have on your bookshelf for all things pediatric*
- 2 A. Doebeli, E. Michel, R. Bettchart, S. Hartnack, I.M. Reichler, Apgar score after induction of anesthesia for canine cesarean section with alfaxalone versus propofol, Theriogenology, Volume 80, Issue 8, 2013, Pages 850-854.
- 3 Venn EC, Preisner K, Boscan PL, Twedt DC, Sullivan LA. Evaluation of an outpatient protocol in the treatment of canine parvoviral enteritis. J Vet Emerg Crit Care (San Antonio). 2017 Jan;27(1):52-65. doi: 10.1111/vec.12561.
- 4 Wayne A., Davis M., Sinnott V.B. Outcomes in dogs with uncomplicated, presumptive bacterial pneumonia treated with short or long course antibiotics. Can Vet J. 2017;58(6):610–613.



A Review of Three Clinically Impactful Journal Articles

Doug Brum, DVM

angell.org/internalmedicine | internalmedicine@angell.org | 617-541-5186

With so many new articles coming out of veterinary literature each year, it can be hard to keep current and gain clinically relevant information that one can put into practice. This review focuses on a few recent journal articles with clinically relevant information that immediately impacts one's practice.

USE OF SILDENAFIL IN CONGENITAL IDIOPATHIC MEGAESOPHAGUS

The first article examined the use of sildenafil in congenital idiopathic megaesophagus.¹ The study included 21 puppies that were diagnosed with congenital idiopathic megaesophagus on the basis of clinical signs, plain radiographs, and esophagrams. Treatment of these dogs typically involves the use of prokinetic drugs that have varying results. Recent studies with high-resolution manometry showed that cisapride significantly increased the lower esophageal sphincter pressure in healthy dogs, and this could represent a serious concern in dogs with megaesophagus.

Swallowing and esophageal motility are complex processes between excitatory innervation, mostly vagal cholinergic fibers, and inhibitory innervation, which release nitric oxide (NO) as the primary neurotransmitter. Endogenous NO induces smooth muscle relaxation by synthesizing the second messenger, cyclic guanosine monophosphate (cGMP). Sildenafil is

a selective phosphodiesterase-type 5 (PDE-5) inhibitor that indirectly potentiates the action of endogenous NO by reducing cGMP degradation due to PDE-5. Because of this, Sildenafil is an effective vasodilator and smooth muscle relaxant. In humans and cats, Sildenafil induces the relaxation of the lower esophageal sphincter. A lower esophageal sphincter tone would facilitate the entry of the ingesta into the stomach, thus reducing the pressure inside the esophageal lumen.

The study was a randomized controlled trial, treatment, and control (placebo). The dogs were given a 1mg/KG BID dose of Sildenafil and then monitored for two weeks. Additionally, a set of in vitro experiments on muscle samples of canine lower esophageal sphincter was also performed, and the effects of increasing concentrations of Sildenafil on basal tone and electrically-stimulated motility were assessed.

The results showed that puppies in the control group had more than two-times total regurgitation episodes throughout the study period, compared to the treatment group. Additionally, Sildenafil-treated dogs gained significantly more weight, and radiographically, the relative esophageal diameter was considerably lower than the controls. The in vivo findings showed that Sildenafil dose-dependently reduced basal muscle tone and increased electrically-induced relaxation of dog lower esophageal sphincter samples.

A dog's esophagus has a striated muscle layer throughout its entire length, excluding the lower esophageal sphincter; therefore, prokinetic agents that act on smooth muscle, such as metoclopramide and cisapride (selective serotonin agonist in the 5-HT₄ receptor subtype), are not effective and could be contraindicated. Under this, 5-HT₄ serotonin receptors are not detected in the esophageal muscle of dogs. Moreover, metoclopramide and cisapride tend to increase lower esophageal sphincter tone, further hindering the emptying of esophageal content and thus potentially worsening the clinical signs.

The paper suggested a novel therapeutic approach using Sildenafil to relax the lower esophageal sphincter smooth muscle and promote the emptying of the esophagus. The ability of Sildenafil to relax smooth muscle and thus decrease esophageal peristalsis is not a concern in dogs, as the esophageal muscle is

almost entirely striated (unlike in cats and humans). Since peristalsis of the esophagus is unchanged, the dogs affected by congenital idiopathic megaesophagus treated with Sildenafil would still require to be fed from an elevated position. However, they could benefit significantly from the easier esophageal emptying and the decrease in esophageal dilatation, resulting in improved clinical signs and general health status.

We have been using Sildenafil for various other esophageal motility issues and have seen good results.

COMPARISON OF INITIAL TREATMENT WITH AND WITHOUT CORTICOSTEROIDS FOR SUSPECTED ACUTE PANCREATITIS IN DOGS

Another article, "Comparison of initial treatment with and without corticosteroids for suspected acute pancreatitis in dogs,"² is clinically relevant and perhaps a bit contrary to our past clinical belief. This article investigated the potential benefit of corticosteroids in acute pancreatitis.² Historically, the use of glucocorticoids has been avoided in dogs with acute pancreatitis because they were considered a risk factor for the condition; however, recent studies have shown this not to be the case. Glucocorticoids are known to counteract nearly all pathways of inflammation. They enhance apoptosis and increase the production of pancreatitis-associated proteins, which confer a protective effect against pancreatic inflammation. Glucocorticoids reduce the severity of lesions in pancreatic acinar cells, possibly by increasing pancreatic arterial blood flow and suppressing the production of pro-inflammatory cytokine interleukins (IL-1 β , IL-6, IL-10) and phospholipase A₂.

Glucocorticoids also benefit in the treatment of septic shock and systemic inflammatory response syndrome (SIRS). They are used to treat critical illness-related corticosteroid insufficiency—(CIRCI-adrenal insufficiency due to a severe pro-inflammatory state, resulting in hypotension and an inadequate response to fluids or vasopressor therapy). Low-dose corticosteroids are recommended as a therapy for humans with CIRCI, and their use in veterinary medicine is beginning to be recognized.



INTERNAL MEDICINE

A Review of Three Clinically Impactful Journal Articles

CONTINUED FROM PAGE 6

This study investigated the efficacy of prednisolone for the initial treatment of acute pancreatitis. Dogs diagnosed with pancreatitis (45 dogs) were treated either with prednisone (1 mg/kg/day SQ during the hospitalization period) or without prednisone (20 dogs). Aside from the prednisone, both groups received similar supportive care. The study showed that dogs treated with prednisone had improved clinical scores, a more rapid decrease in C-reactive protein, and a shorter duration of hospitalization. Although there was no difference in mortality while hospitalized, the prednisone-treated group had a significantly decreased mortality rate one month after hospitalization. These results suggest that the use of prednisone in cases of acute pancreatitis leads to a more rapid recovery and improved long-term prognosis.

A PIVOTAL FIELD STUDY TO SUPPORT THE REGISTRATION OF LEVOTHYROXINE SODIUM TABLETS FOR CANINE HYPOTHYROIDISM

The final article, “A Pivotal Field Study to Support the Registration of Levothyroxine Sodium Tablets for Canine Hypothyroidism,” looks at a study that investigated whether a lower dose of Levothyroxine would be sufficient to treat hypothyroidism. Levothyroxine sodium was administered to dogs as the whole dose q 24 hr or as half the dose q 12 hr. Dosing started at

0.1 mg/10 lb (0.022 mg/kg) and continued for approximately six months. It should be noted that the dose used for both groups is half of the generally accepted dose of 0.1mg/10lb BID. There were 92 dogs enrolled in the study.

In humans, slight variations in Levothyroxine potency or bioavailability can lead to underdosing or overdosing, and historically this has been a significant issue. There is a much wider margin of safety in dogs, but compliance in medicating is more of a concern. Giving a drug SID (once daily) instead of BID (twice daily) is far more acceptable. Additionally, there is a lot of literature about the bio-availability differences between different brands of Levothyroxine sodium tablets and the problems associated with interchanging other products. However, not much exists on the same subject for dogs. This study used one brand (Thyro-tabs 4) to assess efficacy.

The study showed no difference in the resolution of clinical and pathologic signs of hypothyroidism in either group. There was no significant difference in how quickly the dogs responded or in adverse effects. The results of this study supported a daily starting dose of 0.1 mg per 10 lb (0.022 mg per kg) body weight and showed that the treatment regimen does not affect clinical outcomes. Giving the full dose SID instead of BID should also increase owner compliance.

FOOTNOTES

- 1 Sildenafil improves clinical signs and radiographic features in dogs with congenital idiopathic megaesophagus: a randomised controlled trial F. Quintavalla, A. Menozzi, C. Pozzoli, E. Poli, P. Donati, D. K. Wyler, P. Serventi, S. Bertini, veterinary record, May 2017.
- 2 Comparison of initial treatment with and without corticosteroids for suspected acute pancreatitis in dogs H. Okanishi*,†, T. Nagata†, S. Nakane†, and T. Watari1,*
*Laboratory of Veterinary Internal Medicine, Department of Veterinary Medicine, Faculty of Bioresource Sciences, Nihon University, Fujisawa, 252-0880, Japan: Journal of Small Animal Practice (2019) 60, 298–304 DOI: 10.1111/jsap.12994 Accepted: 25 January 2019; Published online: 13 March 2019.
- 3 A Pivotal Field Study to Support the Registration of Levothyroxine Sodium Tablets for Canine Hypothyroidism—Victoria A. Lewis, DVM, RPh*, Carla M.K. Morrow, DVM, PhD, DABVT, Johnny A. Jacobsen, DVM, MSc, W. Eugene Lloyd, DVM, PhD, DABVTy (J Am Anim Hosp Assoc 2018; 54:201–208. DOI 10.5326/JAAHA-MS-6649).
- 4 Thyro-Tabs Canine (levothyroxine sodium tablets) USP, LLOYD, Inc., Shenandoah, Iowa.



➤ Angell's Referring Vet Portal

24/7 access to your referred patients' records

We are pleased to offer the Angell Referring Veterinarian Portal to our referring partners. The portal provides 24/7, secure, mobile-friendly access to your referred patients' records through angell.org/vetportal. The system automatically updates throughout the day and provides access to:

- Online medical records
- Discharge instructions
- Referral reports
- SOAPs
- Check-in status
- Prescriptions
- Lab results
- Diagnostic images

Settings can be customized within the portal to receive notices by email or fax and you may list multiple emails to receive check-in, discharged, deceased, and update notices.

Visit angell.org/vetportal or call our referral coordinator at 617-522-5011 to gain access to your account.



Pediatric Dentition and Malocclusions

Jessica Riehl, DVM, DAVDC
 angell.org/dentistry | dentistry@angell.org | 617-522-7282

Comparative to humans, our canine and feline patients have a significantly shorter interval of time when the deciduous dentition is present, and growth is occurring. However, this period of tooth development, tooth exfoliation, and jaw growth can hugely impact these pets over a much greater length of time. The key to pediatric dentistry is recognizing normal from abnormal – although it may not be an immediate problem, we can often assist in helping prevent a future issue.



DENTAL FORMULA AND ERUPTION TIMES

Knowing the dental formulas and eruption times will help us identify abnormal pathology, including missing teeth, delayed eruption, persistent/retained teeth, and supernumerary teeth. Neither the first premolar nor any of the molars have deciduous teeth (they are non-successional teeth). When differentiating between deciduous or permanent dentition, the deciduous teeth can often be identified based on the tooth shape and smaller size. It is important to remember that the deciduous third and fourth premolars will look like the adult fourth premolar and first molar in shape.

Dental formula for deciduous teeth – Canine

- I3 – C1 – P3 // I3 – C1 – P3

Dental formula for deciduous teeth – Feline

- I3 – C1 – P3 // I3 – C1 – P2

Eruption times for deciduous dentition - Canine

- Incisors 3-4 weeks
- Canines 3 weeks
- Premolars 4-12 weeks
- Molars – no deciduous

Eruption times for deciduous dentition – Feline

- Incisors 2-3 weeks
- Canines 3-4 weeks
- Premolars 3-6 weeks
- Molars – no deciduous

Dental formula for permanent teeth – Canine

- I3 – C1 – P4 – M2 // I3 – C1 – P4 – M3

Dental formula for permanent teeth – Feline

- I3 – C1 – P3 – M1 // I3 – C1 – P2 – M1

Eruption times for permanent dentition – Canine

- Incisors 3-5 months
- Canines 4-6 months
- Premolars 4-6 months
- Molars 5-7 months

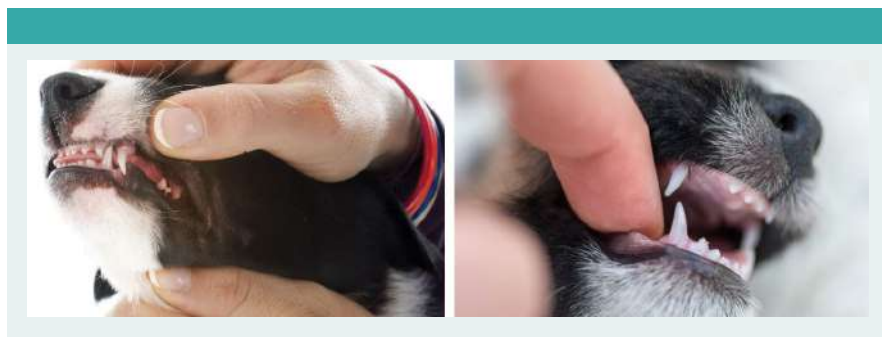Eruption times for permanent dentition – Feline

- Incisors 3-4 months
- Canines 4-5 months
- Premolars 4-6 months
- Molars 4-5 months

DECIDUOUS TEETH – PERSISTENT, (RETAINED), OR FRACTURED

Common pathology associated with deciduous teeth include persistent or retained teeth. These two terms are often used interchangeably; however, this is not appropriate as each term is specific. Persistent deciduous teeth is the term that should be used for a deciduous tooth that remains present when the adult tooth has erupted. It persists, despite the presence of the adult tooth. The deciduous tooth, in this case, should be extracted. No two teeth should occupy the same space. The presence of the deciduous tooth can lead to malocclusion and will predispose the adult tooth to periodontal disease. The term retained is better suited for dental structure that is present underneath the gums (i.e., retained tooth root) or can sometimes be used when describing a deciduous tooth that is present due to the lack of an adult counterpart. I most commonly see this with second premolars in dogs. I let owners know that a dental radiograph should be performed to ensure there is no adult tooth. The deciduous tooth can remain if there is no indication of pathology associated with it. Owners are warned that the tooth roots may resorb, and there is the potential the tooth can fracture – both situations requiring extraction in the future.

With adult patients, we have more treatment options for a fractured tooth with pulp exposure (complicated fracture, endodontic disease), including extraction, root canal therapy, or vital pulpotomy given the right circumstances. If a deciduous tooth is fractured, treatment recommendations should be for an extraction. Not only is the fractured tooth a source of pain and infection, but the inflammation associated with endodontic disease can affect the developing adult tooth bud. The apex of the deciduous tooth root sits in close proximity to the permanent tooth bud, and changes in the local environment can lead to disruption of the ameloblasts forming enamel on the adult tooth.



DENTISTRY

Pediatric Dentition and Malocclusions

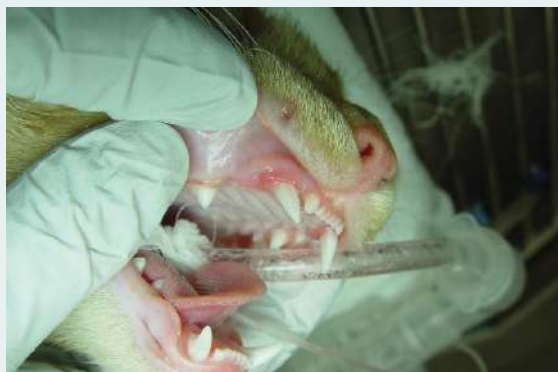CONTINUED FROM PAGE 8

MALOCCLUSIONS

Most times, patients presenting for malocclusion will be pediatric or young juvenile when this issue is noticed. When assessing occlusion, keeping in mind that the standards of normal occlusion are most important. Normal or ideal occlusion (canine) consists of interdigitation of the upper and lower teeth; maxillary incisor teeth are slightly rostral to the mandibular incisor teeth with the mandibular incisor teeth contacting the cingulum of the maxillary incisors; the mandibular canine teeth should be slightly inclined labially and sit within the interdental space between the maxillary third incisor and canine tooth; the crown cusps of the mandibular premolars should be lingual to the maxillary premolar teeth; the premolars should have a pinking shears relationship with the mandibular first premolar rostral to the maxillary premolars; and the mesial cusp tip of the maxillary fourth premolar should be lateral to the space between the mandibular fourth premolar and first molar. Normal occlusion in cats follows the same basic guidelines with minor adjustments.

Malocclusions can be a result of abnormal tooth positioning or due to an abnormal jaw length relationship. Many animals with malocclusion may have more than one deviation from normal and thus multiple concurrent malocclusions (i.e., mandibular distocclusion with linguoverged mandibular canine teeth). Class 1 malocclusion consists of a normal jaw length relationship with malpositioning of one or more teeth. Generally, these malocclusions are described by the physical direction that the tooth is angled or deviated (i.e., mesioverted). Another Class 1 malocclusion version is a crossbite, where the mandibular teeth are more buccal or labial to the opposing maxillary tooth. Crossbites can be described as rostral crossbite – referring to the incisor teeth or caudal crossbite – when the malocclusion is associated with the premolars or molars. There are other classes of malocclusion that deal with skeletal malocclusion.

▼ Lance (mesioverted) canine



Class 2 malocclusion, or mandibular distocclusion, is when the mandible occludes caudal to the normal position relative to the maxilla. Colloquial terms for this malocclusion include ‘parrot mouth,’ ‘overbite,’ and ‘overshot jaw.’ On the other hand, in Class 3 malocclusion, or mandibular mesiocclusion, the mandible will be rostral to the maxillary arch. In some breeds, this occlusion is normal for the breed (i.e., brachycephalics). Other terms often used are ‘underbite’ or ‘monkey mouth.’ Class 4 malocclusions involve asymmetry and can be in a rostrocaudal, side-to-side, dorso-ventral direction, or a combination of these. We try to steer away from the term ‘wry bite,’ as this is non-specific and does not accurately provide an image of a patient’s malocclusion. An example of Class 4 malocclusion in a rostrocaudal direction would be when the right or left side of the face has

mandibular mesiocclusion or distocclusion. A side-to-side malocclusion would describe when the midline alignment of the maxilla and mandible is shifted. And finally, a dorsoventral malocclusion would correspond with an open bite in which there is abnormal vertical space between the maxilla and mandible when the mouth is in a closed position.

Treating malocclusion cases can be more of an art than a science, and frequently we are dealing with evolving circumstances. Expectations of malocclusion treatment should be relayed to the owner, and procedures should be performed to provide pets with a comfortable bite rather than a cosmetic outcome. Options for treatment include interceptive orthodontics (extractions), corrective orthodontics, or alteration to a tooth shape/structure (crown reduction with vital pulpotomy).

Our role as veterinarians in helping pets have a mouth free of discomfort and disease should begin when our patients are very young. Issues with deciduous dentition should not be overlooked due to the short timespan that these teeth are present since these issues may contribute to problems when the patient gets older. The stage when adult teeth erupt is crucial to ensure that teeth are accounted for, structurally normal, and positioned appropriately.



Canine Intervertebral Disc Disease: Clinical Points, Perspectives, and Minimizing Risk

Rob Daniel, DVM, DACVIM (Neurology)
 angell.org/neurology | neurology@angell.org | 617-541-5140

Acute, severe thoracolumbar spinal cord injuries make up 4% of cases presenting to ER facilities across North America, with ~75% due to some form of intervertebral disc (IV) displacement. Recent reports describe >20,000 surgeries annually.

During embryologic development, the intervertebral disc arises from differing regions, with the annulus fibrosus (AF) arising from sclerotome and the nucleus pulposus (NP) originating from the notochord. Notochordal cells persist into adulthood in chondrodystrophic (CD) breeds, whereas the notochordal cells disappear before two years of age in nonchondrodystrophic breeds (NCD).

The AF is collagen-rich tissue, with the NP rich in proteoglycans and a transitional zone (TZ) between the two. Regions of the disc that contact the adjacent vertebral bodies are hyaline-like cartilaginous tissue. Relatively inelastic Type I and II collagen fibers are contained within the intervertebral disc in organized, consistent patterns, with Type I predominantly in AF and Type II within NP. Elastin is present within the IV disc. Think in terms of a pillow for the IV

disc, a viscoelastic cushion countering compressive forces, with the load being transferred from NP to AF. The NP is 80% water.

Sensory nerves are sparse in the dorsal AF, with the dorsal longitudinal ligament innervated profusely and innervation to the outer AF communicating with two spinal levels, cranial and caudal, to the particular intervertebral (IV) disc.

In chondrodystrophic dogs, the NP loses its prior ability to retain water – this leads to more load to AF and an increase in AF size. As a result, weaker and stiffer inherent properties lead to structural failure, with AF defects, tears, and uneven load displacement.

The Nomenclature of Hansen's Type I (extrusion, chondroid metaplasia) and Hansen's Type II (protrusion, fibroid metaplasia) intervertebral disc disease is pervasive. It has been upheld since this classification system was proposed in a landmark, mid-twentieth century paper, although both situations are not mutually exclusive of one another.

In order to become better at care delivery, it is helpful to have agreed-upon nomenclature that

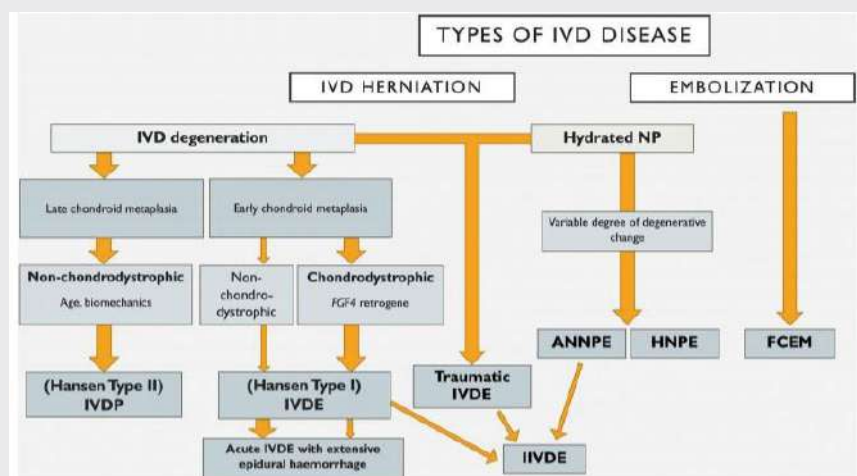
is pervasive and well-adopted to reduce heterogeneity in the description, facilitate communication, and improve data quality.

Intervertebral disc degeneration is defined as the structural failure of the IV disc associated with abnormal or accelerated changes in aging. IV disc herniation is defined as abnormal, localized displacement of the IV disc beyond bounds of IV space. IV disc extrusion describes a complete rent in AF, with a displacement of NP from prior containment. IV disc protrusion describes rupture of inner layers of AF, with a partial displacement of NP and annular hypertrophy. Acute, non-compressive NP extrusions (ANNPE) describe small volume NP displacements resulting in spinal cord injury, which may be traumatic in origin. Velocity, dwell time, and impact force are major factors in determining the severity of spinal cord injury.

The importance of a thorough history and complete physical examination cannot be overstated. Stress on the pet's family is difficult to quantify, and informed consent can be difficult due to various reasons, including pet status, anxiety, need for timely decision-making, or financial concerns.

FIGURE 1

↳ Fenn et al. Classification of Intervertebral Disc Disease. 2020.



NEUROLOGY

Canine Intervertebral Disc Disease: Clinical Points, Perspectives, and Minimizing Risk

CONTINUED FROM PAGE 10

Spinal cord contusion and compressive forces have their earliest and most harmful effects on the myelin sheathing neurons within the spinal cord. Axons that typically conduct deep pain/nociception (DP) are relatively small with minimal to no myelin sheathing. Although the clinician is at an inherent disadvantage of testing deep pain/nociception, compared to people who can describe sensation, excellent interobserver variability exists between examiners of varying backgrounds. Place the dog on the ground and watch first, then assist if needed, followed by testing for deep pain/nociception only if a clear, purposeful motor function is not present. The presence or absence of nociception/deep pain is critical in decision-making.

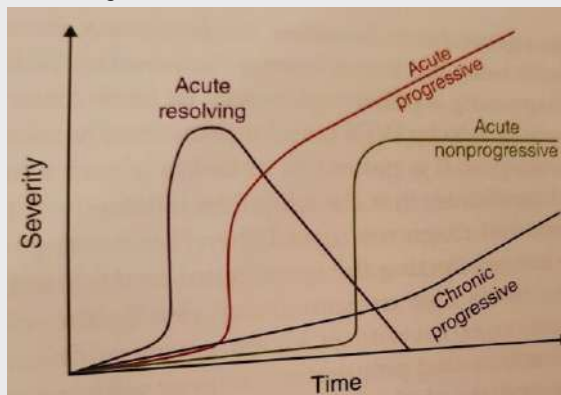
The decision to take radiographs is subjective. When discussing examination findings with the pet's family, consider how likely radiographs will change what the examiner is already recommending.

Advanced imaging, namely and in overwhelming majority in 2021, MRI or CT, are needed for a definitive diagnosis. The decision to refer a neurologic pet suspected of intervertebral disc-related spinal cord injury for evaluation is subjective, but understanding a severity vs. time graph can be helpful.

After evaluation by a veterinary neurologist and review of advanced imaging results, the decision for surgical intervention is overwhelmingly rooted in the purpose of decompression. For most intervertebral disc displacement cases, surgical approaches are relatively few, including hemilaminectomy, ventral slot, and dorsal laminectomy. Fenestration is always considered.

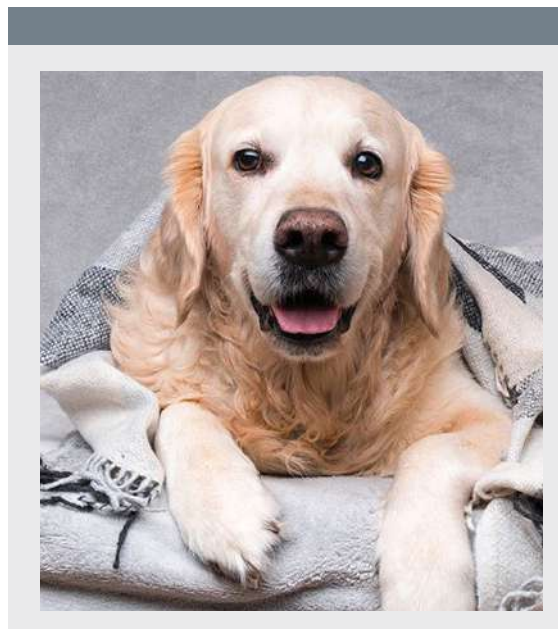
FIGURE 2

↘ Fingeroth and Thomas, *Advances in Intervertebral Disc Disease in Dogs and Cats*. P 157, 2015.



The cornerstone of conservative management is rest. Medications can be helpful, keeping in mind the relative risk of the particular medications, along with the risk of making an acutely myelopathic pet feel better in the absence of rest. Corticosteroids, NSAIDs, opioids, muscle relaxants, gabapentin/pregabalin, and amantadine are common in medical management. Adjunctive strategies, such as physical therapy, are often considered.

Regardless of whether referral for evaluation and surgical intervention or conservative management is decided, a follow-up with the family is essential in maintaining a solid relationship, rapport, and health care of the pet.



REFERENCES

- 1 Advances in Intervertebral Disc Disease in Dogs and Cats. James M. Fingeroth and William B. Thomas. Wiley Blackwell, 2015
- 2 An Update on hemilaminectomy of the cranial thoracic spine: Review of six Cases. Bray, K.B, Early, P.J., Olby, NJ and Lewis, M.J. *Open Veterinary Journal* (2020) Vol 10(1): 1621.
- 3 Fenn, J., Olby, NJ and Canine Spinal cord Injury Consortium (CANSORT-SCI). Classification of Intervertebral Disc Disease. *Frontiers in Veterinary Science* October 2020 Volume 7, Article 579025
- 4 Olby, NJ, da Costa, R.C., Levine, J.M., Stein V.M. and the Canine Spinal Cord Injury Consortium CANSORT SCI) Prognostic Factors in Canine Acute Intervertebral Disc Disease. November 2020 Volume 7 Article 596059

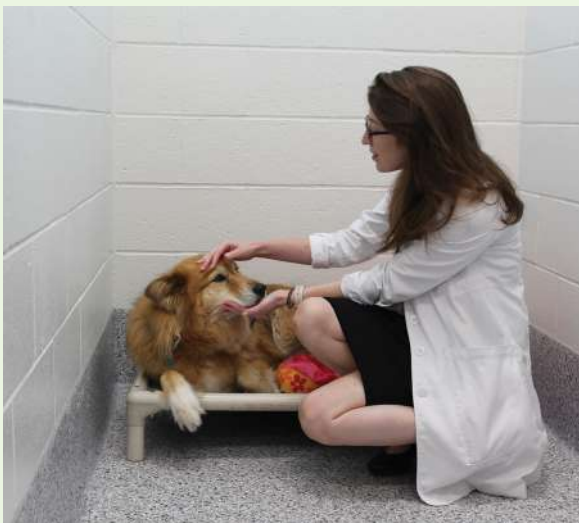SCU AND CCU CONSTRUCTION

Construction continues at Angell in Boston! We opened the doors to our new Supportive Care Unit (SCU) in July 2021, and the SCU now houses Angell's recovering in-patients. We are on track to complete the new Critical Care Unit (CCU) in 2022. These cutting-edge units will ensure that Angell patients and their families continue to have access to the highest level of life-saving care.



New CCU Highlights

- Private visiting rooms for patients and families
- Bays designed specifically for a mechanical ventilator and for dialysis
- A 6,000 square foot increase in CCU and ward space
- A built-in isolation ward and work space for doctors
- Direct access to the outdoors; minimizing walking distance for patients
- Design flow enabling easy transition from the emergency room to the CCU space
- Separate spaces for different species with noise control to reduce patient anxiety levels
- Increased capacity for all species, including large cage spaces
- Skylights that provide beautiful, natural lighting
- Dedicated space for medical boarding, grooming, and laboratory and pharmacy services



Physical Rehabilitation at MSPCA-Angell West

Watch patients enjoy land-based and hydrotherapy treatment in our Physical Rehabilitation facility at [angell.org/rehab](https://www.angell.org/rehab)

Canine and feline physical rehabilitation is used to treat a wide variety of orthopedic and neurological conditions. Whether recovering from an injury, or cross-training, or facing a mobility issue, dogs and cats can substantially benefit from physical rehabilitation.

MSPCA-Angell West Physical Rehabilitation offers services seven days a week. Jennifer Palmer, DVM, Certified Canine Rehabilitation Therapist (CCRT), and Amy Straut, DVM, CCRT, lead our Physical Rehab team. Visit [angell.org/rehab](https://www.angell.org/rehab) for details and video footage of the impact their work on our patients.

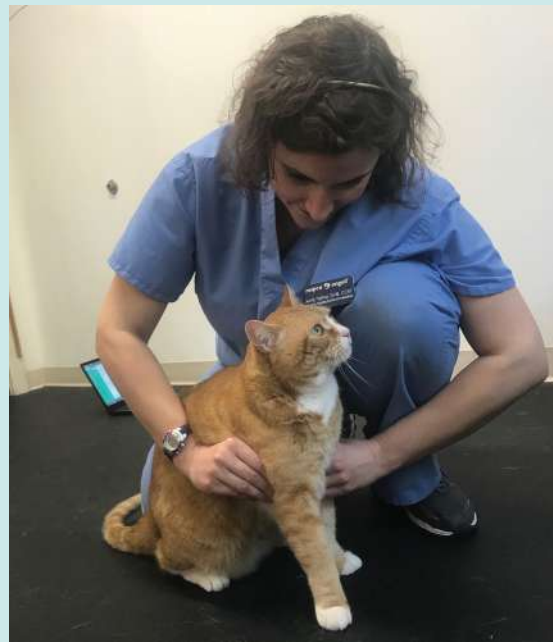Currently physical rehabilitation services include:

- Hydrotherapy
- Land-based exercise
- Manual therapy
- Therapeutic laser treatment
- Massage
- Consultation and fitting of assistive devices
- Chiropractic

mspca  **angell west**



Land-based Exercise Area



Hydrotherapy – AquaPaws Water Treadmills



Hydrotherapy – Indoor Pool



Understanding Vascular Ring Anomalies

Jordanna Fetto, VMD

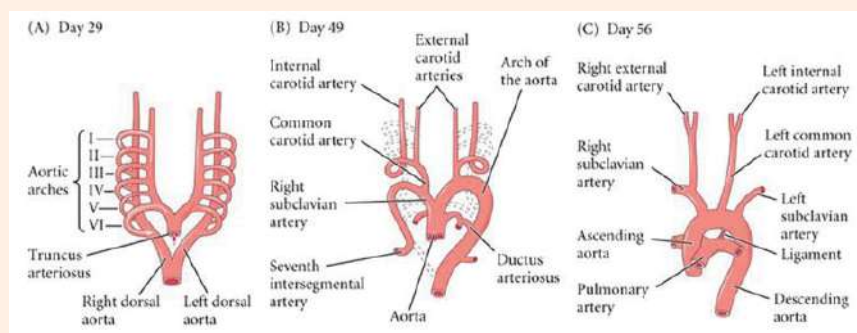
angell.org/emergency | MSPCA-Angell West | 781-902-8400

Vascular ring anomalies are congenital malformations of the major blood vessels of the body that result in esophageal entrapment and constriction. The mode of inheritance is complex and believed to involve multiple recessive genes. As such, affected animals and unaffected animals from litters containing affected animals should not be bred. All species can be affected, but dogs are significantly more commonly affected than cats. Furthermore, while any breed can be affected, dog and cat breeds commonly include German shepherd, Irish setter, Boston terrier, German Pinscher, Greyhound, Persian, and Siamese.

During fetal development, six pairs of aortic arches initially surround the trachea and esophagus. As fetal development progresses, some of the arches will regress while others will form the great vessels. Developmental abnormalities occur when the arches persist and do not regress. While vascular ring anomalies can arise from the abnormal development of the third, fourth, or sixth aortic arches, the most common is the persistence

FIGURE 1

Embryologic development of the six aortic arches into the great vessels of the body.



of the fourth right aortic arch (a.k.a. PRAA) which makes up 95% of all cases in dogs and most of the cases in cats.

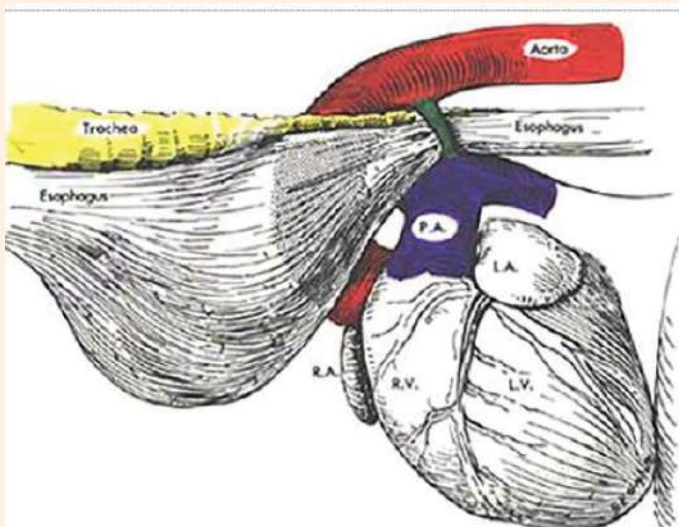
As mentioned above, this disorder is typically diagnosed in young animals of two to six months of age around the time they are weaned from

milk to solid food. Signs observed include failure to grow, thin body condition, voracious appetite, regurgitation, and sometimes even bulging of the neck in the region of the dilated esophagus. Since these animals are at high risk for aspiration pneumonia, other symptoms that may be observed include fever, lethargy, nasal discharge, cough, and difficulty breathing. Vascular ring anomalies can be diagnosed with thoracic radiographs (chest X-rays), ideally with the use of contrast, which reveals a dilated esophagus in front of the heart. In order to know the specific type of vascular ring anomaly and aid in surgical planning, a CT scan with angiography needs to be performed.

The treatment of choice is a surgical intervention in which the aberrant vessel is ligated and transected, alleviating the esophageal constriction. Surgery should be done as soon as possible after diagnosis to reduce the degree of damage to the esophageal muscles and nerves. The prognosis for survival to discharge is 92%, and 87% of cases have good to excellent long-term survival. However, only 30% of cases have complete resolution of clinical signs. Even if the esophagus does not return to normal, as some degree of dilation is often permanent, episodes of regurgitation become less frequent, and body condition greatly improves. A worse prognosis is associated with the severity of esophageal dilation and a more significant time delay to surgery. While medical management can be attempted through elevated feedings of a liquid

FIGURE 2

(Drawing of vascular ring anomaly) The structure colored green is the vascular ring anomaly (specifically a persistent right aortic arch) causing entrapment and constriction of the esophagus.



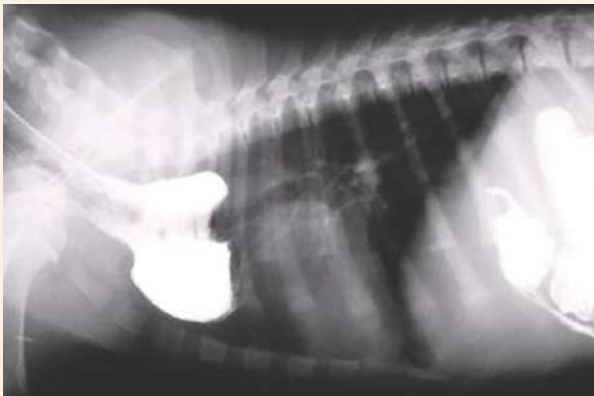
EMERGENCY AND CRITICAL CARE

Understanding Vascular Ring Anomalies

CONTINUED FROM PAGE 14

FIGURE 3

∇ Barium study of the thorax showing the enlarged esophagus immediately before the heart, which is classic for a vascular ring anomaly. This lateral thoracic radiograph is from a dog with chronic regurgitation of food. The image was taken soon after the dog swallowed barium paste, but while barium paste passed to the stomach, a portion accumulated in an esophageal dilation cranial to the heart. This appearance is typical for a vascular ring anomaly, most commonly a persistent right aortic arch. Courtesy of Dr. Mark Kittleson © 2005.



diet, this is palliative. The affected animal will continue to have chronic regurgitation, worsening episodes of aspiration pneumonia, and failure to thrive due to the inability to consume an appropriate amount of calories. Thus, the long-term prognosis is poor with this treatment option.

BIBLIOGRAPHY

- 1 Rishniw, Mark, et al. "VINyclopedia of Diseases: Vascular Ring Anomalies." VIN, 28 May 2015, vin.com/Members/Associate/Associate.plx?from=GetDzInfo&DiseaseId=17&pid=607.
- 2 Holmberg, D L, and K R Presnell. "Vascular Ring Anomalies: Case Report and Brief Review." Canadian Veterinary Journal, vol. 20, Mar. 1979, pp. 78–81., ncbi.nlm.nih.gov/pmc/articles/PMC1789496/.
- 3 Plesman, Rhea, et al. "Thoracoscopic Correction of a Congenital Persistent Right Aortic Arch in a Young Cat." The Canadian Veterinary Journal, vol. 52, Oct. 2011, www.ncbi.nlm.nih.gov/pmc/articles/PMC3174512/.

∇ MSPCA-Angell West Emergency/Critical Care (E/CC) Service Temporarily Closed; Urgent Care Service Now Available by Appointment

On June 28, the Angell West E/CC service in Waltham temporarily closed to incoming triages. The increase in patient volume drove this decision to ensure high quality care for our other patients. The Angell West E/CC staff is working with the Angell Boston E/CC team to address the record high case load at our Boston location and decrease emergency service wait times. We will reopen our Angell West E/CC when our staff-to-patient volume ratio enables us to do so without impacting patient care. Importantly, all other specialty services at Angell West in Waltham will continue to serve patients without change. We will continue to hospitalize these patients and care for them overnight as needed. Specialty services continue to offer surgery, procedures, and diagnostic imaging (radiographs, ultrasound, and CT).



With the temporary closing of emergency and critical care services at our Waltham location, we are pleased to share that the MSPCA-Angell West has launched an Urgent Care service for dogs and cats. Clients can call up to one day in advance to book an Urgent Care appointment. Our team can help clients discern if their animal's condition is an Urgent Care or Emergency case. Established to treat less critical cases when appropriate staff is scheduled, this is an appointment-based service, NOT a walk-in service. Afternoon and evening appointments are available throughout the week by calling 781-902-8400. Avian and exotic animals are not eligible for the Urgent Care service at this time.

mspca  **angell west**

∨ Angell Fall Continuing Education — **Registration is Open!**

Practical Techniques in Veterinary Medicine

Sunday, October 3, 2021

8:15am – 2:45pm

5 Interactive CE Credits (RACE Approved)

TOPICS:

- **Top 10 Tips for Better Pathology Submissions;** *Patty Ewing, DVM, MS, DACVP*
- **The Neurologic Exam;** *Michele James, DVM, DACVIM (Neurology)*
- **Emergency Preparedness;** *Ashley Lockwood, DVM, DACVECC*
- **Treating GI Stasis in the Herbivore Patient and Appropriate Antibiotic Use in Rabbits;** *Patrick Sullivan, DVM, DABVP (Avian Practice)*
- **Practical Approach to CPR;** *Catherine Sumner, DVM, DACVECC*

Making the Cut: 1) A Practical Approach to Surgical Upper Airway Disease in Dogs and 2) Treating Hip Luxation

Wednesday, October 20, 2021

6:15pm – 8:45pm

2 Interactive CE Credits (RACE Approved)

TOPICS:

- **A Practical Approach to Surgical Upper Airway Disease in Dogs;** *Nicholas Trout, MA, VET MB, DACVS, ECVS*
- **Hip Luxation;** *Emily Ulfelder, BVetMed, DACVS*



JOIN US FOR A LIVE, INTERACTIVE WEBINAR!

To register for our fall online webinars, please visit angell.org/ce

➤ Angell Offers Five Low-Cost, Need-Based Clinics

Angell at Essex (Danvers, MA) and Angell at Nashoba (Westford, MA) clinics are dedicated to providing quality care to the general public as well as offering deeply-discounted services for qualified low-income families. The clinics provide primary veterinary care, spay/neuter services, vaccinations, and surgery and dental services.

The clinics do not provide overnight care, specialty service care, or 24/7 emergency care. Appropriate cases will be referred to Angell's Boston or Waltham facilities or a surrounding specialty veterinary referral hospital.

To see if your clients qualify for financial assistance, please visit angell.org/essex or angell.org/nashoba



angell at nashoba

To schedule an appointment with the Angell at Nashoba clinic, please call **978-577-5992**.

angell at essex

To schedule an appointment with the Angell at Essex clinic, please call **978-304-4648**.



Left to Right: Dr. Laurence Sawyer. Angell at Nashoba on campus at Nashoba Valley Technical High School (Westford, MA).



Left to Right: Dr. Erin Turowski. Angell at Essex on campus at Essex North Shore Agricultural and Technical School (Danvers, MA).

➤ MSPCA-Angell Clinics now in Boston, Methuen, and on Cape Cod

Offering subsidized veterinary care to help keep pets and families together.

The clinics provide spay/neuter services as well as acute outpatient surgical care, but they do not provide primary, overnight, or emergency veterinary care. The clinics are meant for families who cannot afford urgent medical care and are faced with a painful choice between euthanasia, surrender, or bringing an animal home against medical recommendations. By providing subsidized, low-cost veterinary care, the clinic provides a new pathway for families in need. We welcome your referrals to our clinics.

mspca **angell clinic**

Boston | Cape Cod | Nevins Farm

MSPCA-Angell Cape Cod and Boston clinics
Monday – Friday 8am-4pm

MSPCA-Angell Nevins Farm in Methuen
Monday – Saturday 8am-4pm

To refer low income clients, please visit angell.org/referrals

MSPCA-Angell Clinic Boston: 617-541-5007 | MSPCA-Angell Clinic Cape Cod: 508-815-5226 | MSPCA-Angell Clinic Nevins Farm: 978-379-6605



STAFF DOCTORS AND RESIDENTS

■ We encourage you to contact Angell's specialists with questions.

Main Phone: 617-522-7282 (Boston) | Main Phone: 781-902-8400 (Waltham) | Veterinary Referrals: 617-522-5011
Angell at Nashoba: 978-577-5992 | Angell at Essex: 978-304-4648

CHIEF OF STAFF

Ann Marie Greenleaf, DVM, DACVECC
agreenleaf@angell.org

24-HOUR EMERGENCY & CRITICAL CARE MEDICINE, BOSTON

Alison Allukian, DVM
aallukian@angell.org

Justina Bartling, DVM
jbartling@angell.org

Jami Becker, DVM
jbecker@angell.org

Kiko Bracker, DVM, DACVECC
Service Co-Director
kbracker@angell.org

Callie Cazlan, DVM
ccazlan@angell.org

Elton Chan, DVM
echan@angell.org

Sara Doyle, DVM
sdoyle@angell.org

Rose Feldman, DVM
rfeldman@angell.org

Molly Graham, DVM
mgraham@angell.org

Virginia Sinnott-Stutzman, DVM, DACVECC
vsinnottstutzman@angell.org

Kelsey Turley, DVM
kturley@angell.org

Julia VanDerslice, DVM
jvanderslice@angell.org

Megan Whelan, DVM, DACVECC, CVA
Chief Medical Officer
mwhelan@angell.org

24-HOUR EMERGENCY & CRITICAL CARE MEDICINE, WALTHAM - TEMPORARILY CLOSED. SEE URGENT CARE INFO BELOW.**URGENT CARE BY APPOINTMENT ONLY, WALTHAM**

Jordana Fetto, DVM
jfetto@angell.org

Mina Gergis, DVM
mgergis@angell.org

Ashley Lockwood, DVM, DACVECC
alockwood@angell.org

Amanda Lohin, DVM
alohin@angell.org

Courtney Peck, DVM, DACVECC
cpeck@angell.org

Jessica Seid, DVM
jseid@angell.org

Catherine Sumner, DVM, DACVECC
Chief Medical Officer, Waltham
csumner@angell.org

ANESTHESIOLOGY

Kate Cummings, DVM, DACVAA
kcummings@angell.org

AVIAN & EXOTIC MEDICINE (W/B)

Brendan Noonan, DVM, DABVP (Avian Practice)
(Boston)
bnoonan@angell.org

Elisabeth Simone-Freilicher, DVM, DABVP (Avian Practice)
esimonefreilicher@angell.org

Patrick Sullivan, DVM, DABVP (Avian Practice)
(Boston & Waltham)
psullivan@angell.org

BEHAVIOR (W/B)

Terri Bright, PhD, BCBA-D, CAAB
tbright@angell.org

CARDIOLOGY (W/B)

Katie Hogan, DVM, DACVIM (Cardiology)
(Boston)
khogan@angell.org

Rebecca Malakoff, DVM, DACVIM (Cardiology)
(Waltham, Part-Time)
rmalakoff@angell.org

Michelle Oranges, DVM
moranges@angell.org

Elizabeth Wiley, DVM
ewiley@angell.org

DENTISTRY

Alice Ekerdt Goodman, DVM, DAVDC
aekerdt@angell.org

Jessica Riehl, DVM, DAVDC
jriehl@angell.org

Joyce Tai, DVM, MS
jtai@angell.org

DERMATOLOGY (W/B)

Klaus Loft, DVM
kloft@angell.org

Meagan Painter, DVM, DACVD
mpainter@angell.org

Brooke Simon, DVM
(Residency Trained)
(Boston & Waltham)
bsimon@angell.org

DIAGNOSTIC IMAGING (W/B)

Naomi Ford, DVM, DACVR
nford@angell.org

Steven Tsai, DVM, DACVR
stsai@angell.org

Ruth Van Hatten, DVM, DACVR
rvanhatten@angell.org

INTERNAL MEDICINE (W/B)

Michelle Beehler, DVM
mbeehler@angell.org

Douglas Brum, DVM
dbrum@angell.org

Maureen Carroll, DVM, DACVIM
mccarroll@angell.org

Zach Crouse, DVM, DACVIM
zcrouse@angell.org

Lisa Gorman, DVM, DACVIM
(Waltham)
lgorman@angell.org

Jessica Hayes, DVM
jhayes@angell.org

Shawn Kearns, DVM, DACVIM
skearns@angell.org

Evan Mariotti, DVM, DACVIM
emariotti@angell.org

Susan O'Bell, DVM, DACVIM
Service Director
sobell@angell.org

Annie Sheu-Lee, DVM
asheulee@angell.org

Daisy Spear, DVM
dspear@angell.org

Daniela Vrabelova Ackley, DVM, DACVIM
(Waltham)
dvrabelova@angell.org

STAFF DOCTORS AND RESIDENTS

CONTINUED FROM PAGE 18

NEUROLOGY

Rob Daniel, DVM, DACVIM**(Neurology)**

rdaniel@angell.org

Michele James, DVM, DACVIM**(Neurology)**

mjames@angell.org

Jennifer Michaels, DVM, DACVIM**(Neurology)**

jmichaels@angell.org

ONCOLOGY

Kristine Burgess, DVM, MLA, DACVIM**(Medical Oncology)**

kburgess@angell.org

J. Lee Talbott, DVM, DACVIM**(Medical Oncology)**

jtalbott@angell.org

Jillian Walz, DVM, DACVIM**(Medical Oncology)****(Board Eligible for Radiation Oncology)**

jwalz@angell.org

OPHTHALMOLOGY

Daniel Biros, DVM, DACVO

dbiros@angell.org

Martin Coster, DVM, MS, DACVO

mcoster@angell.org

PATHOLOGY

(CLINICAL & ANATOMIC)***Patty Ewing, DVM, MS, DACVP**

pewing@angell.org

Pamela Mouser, DVM, MS, DACVP

pmouser@angell.org

PHYSICAL REHABILITATION**

Jennifer Palmer, DVM, CCRT

jpalmer@angell.org

Amy Straut, DVM, CCRT

astraut@angell.org

SURGERY (W/B)

Sue Casale, DVM, DACVS

scasale@angell.org

Caroline Choi, DVM

cchoi@angell.org

Michael Pavletic, DVM, DACVS

mpavletic@angell.org

Nicholas Trout, MA, VET MB, MRCVS,**DACVS, DECVS**

ntrout@angell.org

Emily Ulfelder, BVetMed, DACVS**(Boston and Waltham)**

eulfelder@angell.org

Emily Viani, DVM

eviani@angell.org

Mallory Watson, DVM

mwatson@angell.org

ANGELL AT ESSEX

Erin Turowski, DVM

eturowski@angell.org

ANGELL AT NASHOBA

Laurence Sawyer, DVM

lsawyer@angell.org

(W/B) Services also available at our Waltham location***Boston-based pathologists and radiologists serve both Boston and Waltham locations **Available only in Waltham**

↘ Courtesy Shuttle for Patients Needing Further Specialized Care

Angell Animal Medical Center offers the convenience of our MSPCA-Angell West facility in Waltham, MA. The Waltham facility offers Urgent Care and specialized service appointments Monday through Saturday. If needed, an oxygen-equipped courtesy shuttle can transport animals to Boston for further specialized care and then return them to Waltham. Whether in Boston or in Waltham, our specialists regularly collaborate and plan treatments tailored to our patients' emergency, surgical, and specialty needs.

WE OFFER A BROAD RANGE OF EXPERTISE AND DELIVER THIS CARE WITH THE ONE-ON-ONE COMPASSION THAT OUR CLIENTS AND PATIENTS DESERVE.

We mail one complimentary copy of our newsletter to each of our referring partners. Please circulate this copy within your practice.

Fall 2021 | angell.org | facebook.com/mspcaangell

MSPCA-ANGELL
350 South Huntington Avenue
Boston, MA 02130
617-522-5011
angell.org

MSPCA-ANGELL WEST
293 Second Avenue
Waltham, MA 02451
781-902-8400
angell.org/waltham

ANGELL AT NASHOBA
100 Littleton Road
Westford, MA 01886
978-577-5992
angell.org/nashoba

ANGELL AT ESSEX
565 Maple Street
Danvers, MA 01923
978-304-4648
angell.org/essex

ANGELL.ORG/DIRECTIONS (FREE PARKING) | ANGELL.ORG/HOURS | ANGELL.ORG/CE

Please consider adding Angell's main numbers to your after-hours phone message.

Our Service Locations

BOSTON & WALTHAM

Avian & Exotic Medicine
617-989-1561

Behavior
617-989-1520

Cardiology
617-541-5038

Dermatology
617-524-5733

Diagnostic Imaging
617-541-5139

Internal Medicine
617-541-5186

Physical Rehabilitation*
781-902-8400

Surgery
617-541-5048

Urgent Care*
781-902-8400

BOSTON ONLY

Anesthesiology
617-541-5048

Dentistry
617-522-7282

Neurology
617-541-5140

Oncology
617-541-5136

Ophthalmology
617-541-5095

Pathology
614-541-5014

*Available only in Waltham

